

Acetabular Labral Tears

Anterior hip or groin pain is a common complaint for which people are referred for physical therapy, with the hip region being involved in approximately 5% to 9% of injuries in high school athletes.¹ Although anterior hip pain is known to result from a number of musculoskeletal and systemic pathologies, a tear of the acetabular labrum is a recent addition to the list that is of particular interest to physical therapists. This mechanically induced pathology is thought to result from excessive forces at the hip joint^{2,3} and has been proposed as part of a continuum of hip joint disease that may result in articular cartilage degeneration.² Although the number of recent articles in the orthopedic literature identifying acetabular labral tears as a source of hip pain is increasing, labral tears often evade detection, resulting in a long duration of symptoms, greater than 2 years on average, before diagnosis.⁴⁻⁸ Studies have shown that 22% of athletes with groin pain⁹ and 55% of patients with mechanical hip pain of unknown etiology² were found to have a labral tear upon further evaluation. In order to provide the most appropriate intervention for patients with anterior hip or groin pain, physical therapists should be knowledgeable about all of the possible sources and causes of this pain, including a tear of the acetabular labrum and the possible factors contributing to these tears. Therefore, the purpose of this article is to review the anatomy and function of the acetabular labrum and present current concepts on the etiology, clinical characteristics, diagnosis, and treatment of labral tears.

Anatomy and Function of the Acetabular Labrum

The acetabular labrum is a ring consisting of both fibrocartilage and dense connective tissue¹⁰ attached to the bony rim of the acetabulum (Fig. 1). This ring is normally triangular in cross section, although other variants, including round, irregular, and flattened, have been noted in people without hip pain.¹¹⁻¹⁴ The labrum is wider¹⁵ and thinner in the anterior region of the acetabulum and thicker in the posterior region of the acetabulum¹⁶⁻¹⁹ (Fig. 2). The labrum appears to be a continuous structure and is completed by the transverse acetabular ligament over the acetabular notch^{10,15} (Fig. 1).

[Lewis CL, Sahrman SA. Acetabular labral tears. *Phys Ther.* 2006;86:110–121.]

Key Words: *Acetabular labral tear, Groin pain, Hip pain.*

Cara L Lewis, Shirley A Sahrman

This Update reviews the anatomy and function of the acetabular labrum and presents the current concepts on the etiology, clinical characteristics, diagnosis, and treatment of labral tears.

The labrum is attached to the acetabulum both directly and indirectly. The labrum attaches directly to the nonarticular side of the thin bony rim of the acetabulum. On the articular side, the labrum attaches indirectly through a zone of calcified cartilage and by merging with the acetabular articular hyaline cartilage through a transition zone of 1 to 2 mm¹⁵ (Fig. 2).

The majority of the acetabular labrum is thought to be avascular. Cadaver studies have shown blood vessels entering primarily the peripheral part of the labrum,^{2,10} with penetration only into the outer one third of the substance of the labrum.¹⁰ This blood supply originates from the obturator, superior gluteal, and inferior gluteal arteries.²

A variety of nerve endings and nerve end organs have been identified in the acetabular labrum. Kim and Azuma²⁰ found numerous ramified free nerve endings, which were more prevalent in the superior and anterior regions. They also found sensory nerve end organs, including Vater-Pacini corpuscles, Golgi-Mazzoni corpuscles, Ruffini corpuscles, and articular (Krause) corpuscles.²⁰ Theoretically, the presence of these nerve endings and nerve end organs would provide pain, pressure, and deep sensation from the labrum indicating that a tear of the labral tissues may be a source of hip pain.²⁰

Although the exact function of the acetabular labrum is not fully understood, the labrum is thought to aid in the stability of, and decrease the stress on, the hip joint. The labrum aids in hip stability by deepening the hip joint. One cadaver study²¹ showed that the labrum deepens the acetabulum by approximately 21%. Several authors have hypothesized that a tear in the labrum may destabilize the hip joint,^{10,17,22–24} resulting in premature articular damage.² However, the mechanism through which this destabilization occurs is not fully understood.

In addition to deepening the hip joint, the labrum also functions to reduce contact stress, or force per unit area, by increasing the contact area and by distributing the load. In their study of cadavers, Tan et al²¹ found that the labrum increased the surface area of the acetabulum by approximately 28%. A tear, therefore, could decrease the acetabular contact area, increase stress, and result in articular damage.^{2,25}

The labrum also has been shown to reduce contact stresses by distributing the load throughout the acetabular cartilage. This is accomplished, in part, by providing a sealing mechanism for the joint itself. That is, the intact labrum helps to keep synovial fluid within the articular cartilage, allowing some of the load to be borne by fluid pressurization and preventing direct contact between the femoral head and the acetabulum.²⁶ In a finite-element model, Ferguson et al²⁷ found that when the labrum was removed, contact stresses were up to 92% higher and the creep consolidation rate, or the rate at which the femur and acetabulum approach each other, was up to 40% greater. Similarly, in an in vitro study, these authors found that the initial consolidation rate was 22% greater and the final consolidation displacement was 21% greater when the labrum was removed.²⁸ The results of these studies suggest that the labrum plays an important role in the ability of the cartilage layers to carry and distribute loads by fluid pressurization, possibly by providing a sealing function for the joint.^{26–28} A tear in the labrum may compromise this seal, thus leading to higher stresses, poorly handled loads, and possibly joint deterioration.

Etiology of Labral Injury and Risk Factors

In studies of people with a tear of the labrum, researchers have attributed the injury to a variety of causes. Direct trauma, including motor vehicle accidents and slipping or falling with or without hip dislocation, are known causes of labral tears.^{5,6,29–32} Sporting activities that require frequent lateral (external) rotation, such as soccer, hockey, golf, and ballet, have been thought to result in labral tears.^{2,3,23,33} Some tears also have been attributed to running⁶ and sprinting.³¹ Certain movements, including torsional or twisting movements,^{3,6,29,34} hyperabduction,²⁹ hyperextension,³⁰ and hyperextension with lateral rotation,³ all have reportedly led to labral tears. Despite all of these movements that are

CL Lewis, PT, PhD, Movement Science Program, Washington University, St Louis, Mo.

SA Sahrman, PT, PhD, FAPTA, is Professor of Physical Therapy/Neurology/Cell Biology & Physiology, Program in Physical Therapy, Washington University School of Medicine, St Louis, Mo. Address all correspondence to Dr Sahrman at Program in Physical Therapy, Washington University, Campus Box 8502, 4444 Forest Park Blvd, St Louis, MO 63108-2212 (USA) (sahrmanns@wustl.edu).

Both authors provided concept/idea/project design and writing.

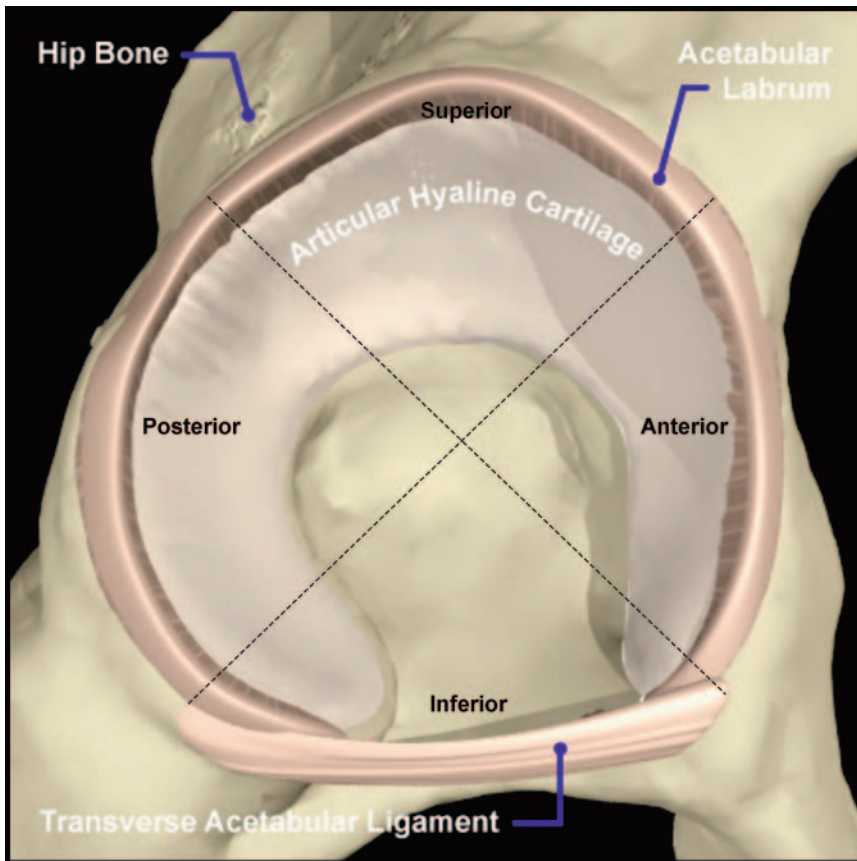


Figure 1. Acetabular labrum. Adapted with permission from Primal Pictures Ltd.

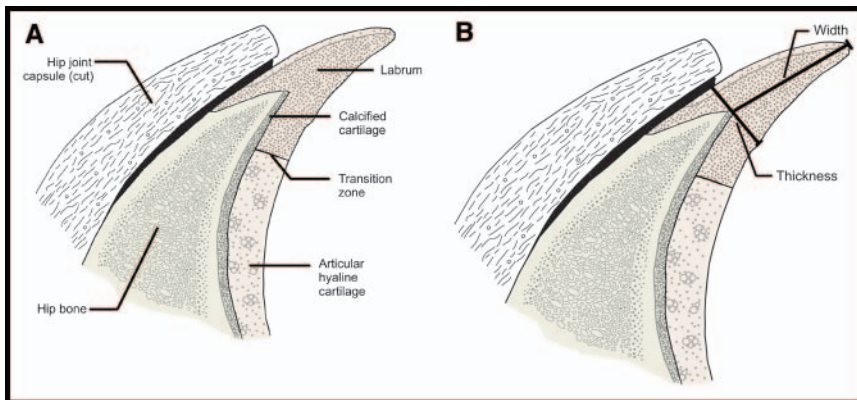


Figure 2. Cross-section of acetabular labrum. (A) Labral attachment. On the nonarticular side of the bone, the labrum attaches directly to the acetabulum. On the articular side, the labrum attaches indirectly through a zone of calcified cartilage and by merging with the articular hyaline cartilage through a transition zone.¹⁵ (B) Labral width and thickness. In the anterior region of the acetabulum, the labrum is wider¹⁵ and thinner, and in the posterior region, it is thicker.^{16–19}

thought to bring about tears, a large percentage of labral tears, up to 74.1%,²⁹ are not associated with any known specific event or cause. In these cases, the pain typically develops gradually and increases in intensity over time. Repetitive microtrauma is believed to be the cause of the labral lesions in these insidious cases.^{2,3}

Currently, the prevalence and significance of labral tears are unclear because some studies suggest that labral abnormalities are a natural part of aging, whereas other studies connect labral tears with joint pathology and pain. Labral abnormalities and tears were noted in subjects without hip pain, and the incidence of these irregularities increased with age, indicating that some deterioration may be associated with the aging process.^{11,12,14} Furthermore, in cadaver studies,^{15,23} labral abnormalities have been found in very high percentages. McCarthy et al²³ reported that 93% of cadavers studied (average age=78 years, range=48–102) had at least one labral lesion. Similarly, Seldes et al¹⁵ noted gross labral tears in 96% of the cadavers that they studied (average age=78 years, range=61–98). Age-related changes, however, cannot explain labral abnormalities found in young people with hip pain. Therefore, prevalence may be more appropriately discussed in terms of percentages of people who have hip pain and who also have a labral tear. In studies of patients with hip or groin pain,^{2,7,9} 22% to 55% of the patients were later found to have a labral tear. The reported age of people with hip pain and a labral tear ranges from 8 to 75 years.^{2–4,6–8,25,29–31,33–37}

Some structural risk factors for developing a labral tear have been identified. One such factor is hip dysplasia. *Hip dysplasia* is a general term used to describe certain abnormalities of the femur or the acetabulum, or both that result in inadequate containment of the femoral head within the acetabulum. These bony abnormalities can include a shallow acetabulum,³⁸ femoral or acetabular anteversion, and a decreased head offset or perpendicular

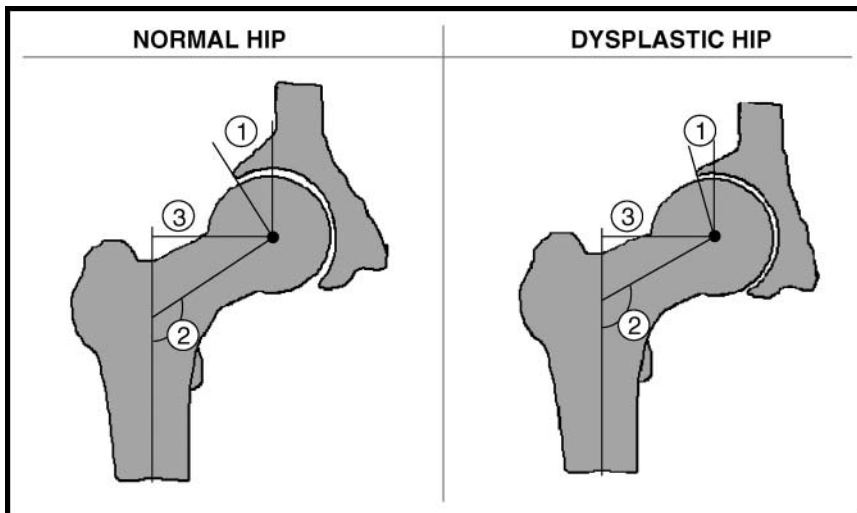


Figure 3.

Frontal views of a normal hip (left) and a dysplastic hip (right). (1) Center-edge angle or angle of Wiberg. Normally 30° to 40° , this angle represents the degree of femoral head coverage in the frontal plane. An angle of less than 30° is a characteristic sign of hip dysplasia. (2) Angle of inclination. This angle, between the femoral neck and the shaft of the femur, is normally 125° . In hips with dysplasia, it is commonly increased but also may be decreased.³⁸ (3) Head offset. This offset represents the perpendicular distance between the femoral head and the shaft. This distance often is decreased with dysplasia.⁴⁰

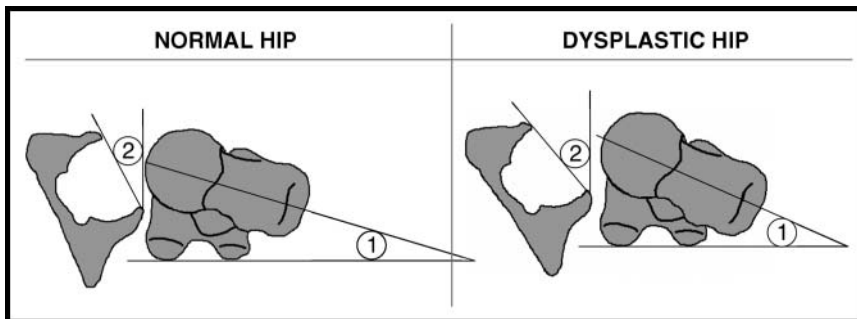


Figure 4.

Transverse views of a normal hip (left) and a dysplastic hip (right). (1) Angle of torsion. This angle represents the rotation of the femoral neck relative to the shaft. Normally, the femur is in 10° to 15° of anteversion.⁴⁶ Hips with dysplasia tend to have increased femoral anteversion.³⁸ (2) Acetabular anteversion angle. This angle, representing the anterior direction of the acetabulum, is normally 20° to 40° of anteversion.^{46,47} In hips with dysplasia, this angle most often is increased but also may be decreased.³⁹

distance from the center of the femoral head to the axis of the femoral shaft^{38–40} (Figs. 3 and 4). Any combination of these abnormalities leads to a change in the position of the femur within the acetabulum that often results in joint incongruity or decreased joint surface area, most commonly anteriorly, and increased stresses on the acetabulum and the labrum.^{3,25,41–43} The increased stresses may lead to fatigue fracture of the acetabular rim and separation of a rim fragment or detachment of the overstressed labrum from the acetabulum.⁴²

Labral tears have been well documented in people with hip dysplasia.^{24,25,42,44} Dorrell and Catterall²⁵ reported on acetabular labral tears in 11 patients (average age= 32.6 years, range= $13–47$) with dysplasia and hip pain. In a study of patients with mild to moderate hip dysplasia and hip pain, McCarthy and Lee⁴⁴ found that 72% of the 170 hips studied had labral tears, and 93% of these tears were in the anterior region of the labrum.

Other structural risk factors for labral tears, all of which decrease the clearance between the femur and the acetabulum, include a reduction in acetabular or femoral anteversion and a decreased femoral head-neck offset, which can be seen as a shallow taper of the femoral neck in the anterior and lateral aspects (Fig. 5). Siebenrock et al⁴⁵ studied 29 hips of 22 patients (average age= 23 years, range= $14–41$; 19 male hips, 10 female hips) with significantly reduced acetabular anteversion such that the acetabulum actually faced posteriorly or was in retroversion instead of the normal 20 to 40 degrees of anteversion.^{46,47} Of the 26 hips that underwent arthroscopic evaluation, all of the hips had either partial or complete tears of the labrum.⁴⁵ In the presence of acetabular retroversion, flexion brings the femur into contact with the acetabular rim, pinching the labrum, especially when combined with adduction.^{48,49}

Similarly, a reduction in the normal amount of femoral anteversion may

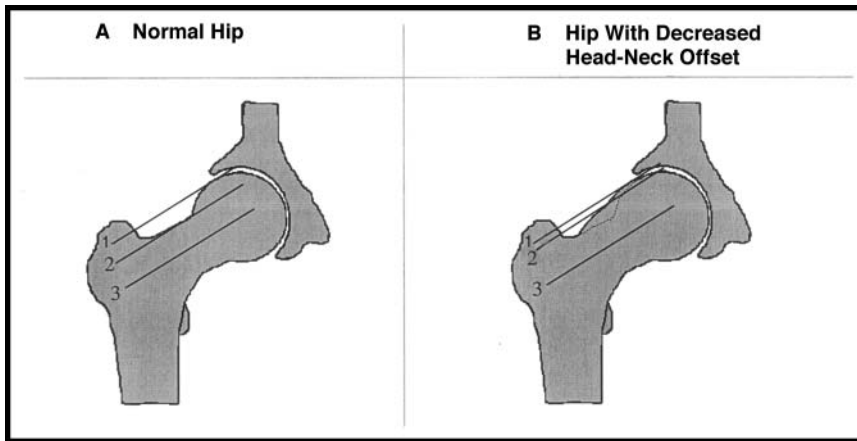


Figure 5.

Femoral head-neck offset. This offset represents the distance between the most superior aspect of the femoral head and the femoral neck. To obtain this measurement, a line is drawn through the long axis of the femoral neck (line 3), and then lines are drawn parallel to it to indicate the most superior aspect of the femoral head and the femoral neck.⁵⁹ (distance between line 1 and line 2). The decreased head-neck offset (right) significantly reduces the clearance between the femur and the acetabulum and may cause impingement.^{48–51}

lead to decreased clearance during flexion compared with normal, especially during flexion combined with medial (internal) rotation.⁵⁰ Ito et al⁵⁰ studied 24 patients (average age=40 years, range=18–78) with hip pain, pain with combined hip flexion, adduction, and medial rotation, and an abnormality of the labrum on magnetic resonance imaging. These patients were compared with 24 volunteers without hip pain of similar age and sex. Ito et al found that the patients with hip pain and a labral abnormality had less femoral anteversion ($9.7^{\circ} \pm 4.7^{\circ}$ [$\bar{X} \pm SD$] versus $15.7^{\circ} \pm 4.4^{\circ}$; $P < .001$) than the comparison subjects.⁵⁰ Ito et al also found that the younger patients, those under 40 years of age, also had a decreased head-neck offset (15.1 ± 6.0 mm versus 20.3 ± 2.0 mm; $P < .001$) compared with comparison subjects of a similar age. A decreased head-neck offset could lead to impingement of the femur against the acetabular rim even within a normal range of motion (ROM).^{48–50} This structural variation may be attributable to an increased lateral extension of the femoral head epiphysis.⁵¹

Clinical Characteristics of People With Symptomatic Labral Tears

The clinical characteristics of patients with labral lesions and hip pain provide information that can be used as a guide to the possible presence of this condition.

Sex

Labral tears are reported more often in females than in males^{2,25,29,31,37} (Tab. 1). This disparity between the sexes may be partly attributable to the increased incidence in females of hip dysplasia,⁵² one of the risk factors for labral tears. However, hip dysplasia alone

cannot account for the sex difference because many patients with labral tears do not have dysplasia.

Symptoms

Patients with a tear of the labrum most consistently complain of hip pain. In greater than 90% of the patients, pain is reported in the anterior hip or groin region^{2,5,30,33,37,42} and less often in the lateral region or deep in the posterior buttocks.^{3,30,37} Data suggest that anterior hip or groin pain is more consistent with an anterior labral tear, whereas buttock pain is more consistent with a posterior labral tear.³⁷ Patients with a labral tear also report a variety of mechanical symptoms, including clicking,^{4,25,29,30,43} locking or catching,^{3,4,25,35,43} or giving way.^{4,35,43} Of these symptoms, clicking appears to be the most consistent clinical symptom. In a

study by Narvani et al,⁹ in which 4 of 18 patients with groin pain were diagnosed with a labral tear using magnetic resonance arthrography, clicking was the most diagnostic symptom, with 100% sensitivity and 85% specificity. Several researchers^{6,30,32,33,35,37} have reported slight hip ROM limitations. The most commonly reported ROM limitation was in rotation,^{32,33,35} but hip flexion,^{35,53} adduction,³⁵ and abduction^{33,35} ROM limitations also have been reported.

Symptom Duration

Typically, patients report a long duration of symptoms, with an average of greater than 2 years.^{4–8} This long duration of symptoms may be related to the difficulty in recognizing an acetabular labral tear as the source of hip pain, especially when the onset is gradual and not associated with trauma.

Provocative Tests

A wide range of provocative tests have been reported, including hip extension alone or combined with medial rotation, flexion with medial rotation alone or combined with adduction or axial compression, flexion with lateral rotation, and resisted straight leg raise.^{2–4,33,37} Whether these tests were performed actively or passively was not specified, and specific information regarding the sensitivity and specificity of these tests has yet to be published. Mitchell et al⁵⁴ reported that the flexion-abduction-external rotation (FABER) test elicited pain in 88% of patients (15 of 17) with intra-articular pathology, but they did not find any correlation between a positive FABER test result and different types of hip joint pathology. In 6 professional soccer players with anterior labral tears, Saw and Villar³⁴ found that all of the players had

Table 1.
Characteristics of Patients With Labral Tears Across Studies

Study	n	Population	Male	Female	Dysplasia	Age Range (y)	Average Age (y)
Suzuki et al ⁵⁵	5	Patients with hip pain of unknown origin; labral tear, undiagnosed by arthrography, noted at arthroscopy	60%	40%	0%	13–16	15
Ikeda et al ³¹	7	Patients with hip pain and normal radiographs	42.8%	57.1%	14.3%	13–26	16.7
Hase and Ueo ³⁷	10	Patients with arthroscopically diagnosed and treated labral tears	30.0%	70.0%	10%	13–67	28.7
Dorrell and Catterall ²⁵	11	Patients in which acetabular dysplasia was associated with labral tears	0%	100.0%	100%	13–47	32.6
Farjo et al ⁴	28	Patients who underwent hip arthroscopy and were found to have labral tears	53.6%	46.4%	50% had arthritis or dysplasia		41
Fitzgerald ⁶	55	Patients with a diagnosis of labral tears	45.5%	54.5%	Not reported	18–75	36.5
Santori and Villar ²⁹	58	Patients with labral tears that were arthroscopically detected and treated with partial resection of the labrum	43.1%	56.9%	Not reported	8–70	36.7
McCarthy et al ²	241	Patients with labral tears and mechanical hip symptoms	45.6%	54.4%	Not reported	14–72	39.9

Table 2.
Locations of Acetabular Labral Tears Across Studies

Study	Patients Undergoing Surgical Treatment (n)	Country of Study	Anterior	Posterior	Superior or Lateral	Other
Suzuki et al ⁵⁵	5	Japan	0%	60% posterior 40% posterosuperior	0%	
Ikeda et al ³¹	7	Japan	14% anterosuperior	86% posterosuperior	0%	
Hase and Ueo ³⁷	10	Japan	20%	50%	10%	20% posterior and anterior
Farjo et al ⁴	28	United States	61%	25%	15%	
Fitzgerald ⁶	49	United States	92%	8%		
Santori and Villar ²⁹	58	England	67%	28%	5%	
McCarthy et al ²	241	United States	86%	11%	3%	

significant pain with combined hip flexion, medial rotation, and adduction.

The wide range of provocative tests may be attributable to differences in the location of the tear. In 56 hips of 55 patients, Fitzgerald⁶ used 2 different clinical tests that provoked symptoms in 54 patients, depending on tear location. To identify an anterior labral tear, the patient's leg is brought into full flexion, lateral rotation, and full abduction and then extended with medial rotation and adduction. To identify a posterior labral tear, the patient's leg is brought into extension, abduction, and lateral rotation and then flexed with medial rotation and

adduction. If a labral tear is present, these maneuvers will result in sharp pain with or without a click.⁶

Characteristics of Labral Tears and Their Diagnosis

Location of Tear

Across studies, tears were reported in all regions of the labrum, and occasionally tears occurred in multiple regions in the same hip. Some disagreement among studies existed regarding the region of the labrum most often torn (Tab. 2). Studies conducted in Japan revealed posterior labral tears to be the most common,^{31,37,55}

whereas studies conducted in the United States and European countries showed anterior tears to be the most common.^{2,4,5,29,42} This difference may be partly attributable to different lifestyles, because people in Japan tend to sit on the ground or squat more often than do people in the United States or European countries³⁷ and therefore may expose the hip to more posterior stresses.

Possible Reasons for Prevalence of Anterior Tears

Different reasons for the prevalence of anterior labral tears have been suggested. One possible explanation is that the anterior region of the labrum has a relatively poor vascular supply compared with the other regions and therefore is more vulnerable to wear and degeneration without the ability for repair.² However, McCarthy et al² found no gaps or regions of relative hypovascularity in a study of 10 acetabula. Furthermore, with the minimal penetration of vessels into the labrum, some authors^{2,31} have concluded that no area of the labrum has the potential for repair. However, Seldes et al¹⁵ noted that neovascularization had occurred within the labral tear and substance of the labrum adjacent to the attachment of the labrum to the bone in all 12 freshly frozen cadaver hips with labral tears that were studied. This finding may indicate that the labrum has some potential for repair,¹⁵ although no clinical studies to date have indicated that labral tears do heal. In contrast, Ikeda et al³¹ found that in one subject who had a labral tear and who had a repeat arthroscopy several months after the initial diagnosis, no healing of the torn tissue had occurred despite the subject's ability to return to sporting activities without a recurrence of pain.

Another possible explanation for the prevalence of anterior labral tears is that the tissue in the anterior region is mechanically weaker than the tissue in other regions of the labrum.^{2,15} Walker et al,⁵⁶ in a study of fetal development of the human hip, noted areolar tissue at the inner margin of the junction between the cartilaginous socket and the labrum. Areolar tissue is a type of loose, irregularly arranged connective tissue that is mechanically weaker than the normal dense connective tissue of the labrum. This tissue was present in only 13.7% (7 acetabula) of fetal hips studied histologically but was always observed in the anterosuperior region of the labrum. The authors were unsure of the significance of this finding but commented that the defect may weaken the labrum, allowing the femoral head to undergo subluxation in the anterosuperior direction.⁵⁶ If this area continues to be weaker in the adult hip, it could partially account for the prevalence of anterior labral tears. However, no reports of similar histologic differences in the adult hip were found.

The third and most likely reason for the prevalence of anterior labral tears is that this region is subjected to

higher forces or greater stresses than other regions of the labrum. Because of the anterior orientation of both the acetabulum and the femoral head, the femoral head has the least bony constraint anteriorly and relies instead on the labrum, joint capsule, and ligaments for stability. Despite its decreased stability, this area undergoes significant forces during daily activities. Using a 3-dimensional musculoskeletal model of the leg, Stansfield and Nicol⁵⁷ demonstrated that the hip joint contact forces are anteriorly directed in the last 20% to 30% of the stance phase of gait. Lewis et al,⁵⁸ also using a 3-dimensional musculoskeletal model, demonstrated that during active hip extension in the prone position, the femur exerts an anteriorly directed force on the acetabulum once the hip is extended approximately 5 degrees. These anteriorly directed forces from the femoral head on the labrum may, over time, become excessive and lead to pain and injury. When other factors, including structural abnormalities and altered movement and muscle recruitment patterns, further increase the joint stresses in the anterior aspect of the hip, labral tears are likely to result.

Radiographic Diagnosis

A tear of the acetabular labrum is difficult to definitively diagnose and is sometimes a "diagnosis of exclusion."³⁰ In people with a labral tear, standard radiographs are typically normal^{6,31}; however, radiographs of some patients may show degenerative changes,^{35,36} dysplasia,^{25,36,37} evidence of prior surgeries,⁶ or subtle bony abnormalities, including coxa valga, a small head-neck offset, or acetabular retroversion.⁵⁹ Computed tomography scans are unable to reliably detect labral tears.^{29,42} Standard magnetic resonance imaging produces both false-positive results and an underestimation of labral pathology and has only a 30% sensitivity and a 36% accuracy.⁶⁰ Magnetic resonance arthrography produces better results, with reported accuracies as high as 91%.^{6,18,19,60,61} Magnetic resonance arthrography does continue to have difficulty correctly identifying patients without labral tears, with a reported specificity of about 70%.^{19,61} Bone scintigraphy, more commonly known as the "bone scan," recently was proposed as a way of detecting a labral tear, as scans in patients with tears showed characteristic patterns of increased uptake in the superior aspect of the acetabulum.⁶² However, this method warrants further testing to determine its diagnostic value. Direct observation of the labrum by arthroscopy, although invasive, continues to be the gold standard for diagnosis.

Sequelae of Labral Tears

Acetabular labral lesions have been associated with hip osteoarthritis.^{2,4,30,35} In 1977, Altenberg³⁵ first noted early degenerative articular changes in 2 patients who had hip pain and who were later found to have labral

lesions. In a study of 436 patients with mechanical hip symptoms, McCarthy et al² found that 73% of patients with fraying or tearing of the acetabular labrum had chondral damage and that this chondral damage was more severe in patients with labral lesions. They also found that in 94% of these patients, the articular damage occurred in the same zone of the acetabulum as the labral lesions. McCarthy et al suggested that the relative risk of significant chondral erosion approximately doubles in the presence of a labral lesion. Furthermore, McCarthy et al noted that an isolated labral tear was found more often in younger patients, whereas a labral tear in conjunction with chondral lesions was found more often in older patients, indicating that a labral tear may precede and possibly lead to articular changes.

Treatment

Medical Management

Once a labral tear is suspected or diagnosed, the treatment is no more defined than the syndrome. The typical conservative treatment includes limited weight bearing, nonsteroidal anti-inflammatory drugs, and sometimes physical therapy.^{1,4,31,37,43} The patient's pain may be reduced during this period of limited activity. However, the pain often recurs when the patient returns to his or her normal activities, possibly because of the limited ability of the labral tear to heal.^{33,37}

Physical Therapy

The appropriate physical therapy intervention for a patient with an acetabular labral tear has yet to be established, and we found no published articles on treating labral tears. Hickman and Peters concluded that "[p]hysical therapy has not proved to be of significant benefit and is not recommended" for patients with a labral tear.^{43(p462)} However, from our clinical experience, physical therapy can be beneficial when appropriately used.

We believe that appropriate intervention should focus on reducing anteriorly directed forces on the hip by addressing the patterns of recruitment of muscles that control hip motion, by correcting the movement patterns during exercises such as hip extension and during gait, and by instruction in the avoidance of pivoting motions in which the acetabulum rotates on the femur, particularly under load. Thus, the initial examination is designed to identify any clinically detectable impairments in the precision of both active and passive hip motions. The most common examination finding is subtle increases in accessory joint motions, particularly during flexion and lateral rotation. The general goal of the intervention is to optimize the alignment of the hip joint and the precision of joint motion, particularly avoiding excessive forces into the anterior hip joint. The

control of the hip abductor, deep lateral rotator, gluteus maximus, and iliopsoas muscles should be optimized, and dominant participation of the quadriceps femoris and hamstring muscles should be corrected. We use the following key elements of the examination to develop a plan of intervention:

(1) Positions and movement tests:

- Standing alignment, particularly noting the presence of hip hyperextension as evident in knee hyperextension or pelvic posterior tilt, or both
- In the sitting position, femoral motions accompanying knee extension
- Precision of both active hip flexion and passive hip flexion
- In the prone position, the pattern of hip extension as an indication of the relative participation of the hamstring and gluteus maximus muscles
- Effect of passive knee flexion on femoral motion in the prone position
- Pattern and range of hip rotation in prone and sitting positions; this assessment includes asymmetric ranges, suggesting the presence of femoral anteversion or retroversion⁶³
- In the quadruped position, the alignment of the hip joint and the presence of symptoms both while in the position and when rocking backward toward the heels

(2) Muscle strength (force-generating capacity of muscle) and pattern of control: hip abductor, gluteus maximus, iliopsoas, and deep lateral rotator muscles when not painful; the deep lateral rotator muscles are best tested with the hip flexed⁶⁴

(3) Muscle length and stiffness: medial and lateral hamstring muscles

(4) Gait assessment:

- Particularly noting a lack of appropriate knee flexion at heel-strike and early stance phase, prolonged foot flat during stance, and knee hyperextension that causes hip hyperextension
- Walking with the hip in lateral rotation as an improper correction of femoral anteversion

(5) Modification of functional activities:

- Avoid sitting:
 - with knees lower than hips
 - with legs crossed or sitting on legs so that the hip is rotated
 - on the edge of the seat and contracting the hip flexor muscles

- with pressure on the femur, which can cause forces into the hip joint; instead, the pressure should be on the ischial tuberosity; a pad may be placed under the ischial tuberosities to correct the problem of increased pressure on the femurs; patients who are overweight and who have large thighs should be encouraged to lose weight to avoid the altered alignment of the femur in sitting
- When getting up from a chair that is behind a desk or out of a car, patients should avoid pushing or rotating the pelvis on a loaded femur
- When walking on a treadmill, patients must be careful not to let the moving tread contribute to excessive hip hyperextension
- Patients should avoid weight training of quadriceps femoris and hamstring muscles and avoid any exercises causing hip hyperextension.

Anecdotally, we have found that modifying these muscle recruitment and movement patterns during gait and functional activities can reduce anterior hip pain prior to or in the absence of surgery.

If surgery is performed, care of the patient after surgery includes evaluation of the above elements, but the timetable varies according to the extent of the surgical intervention. If the surgery is limited to arthroscopic debridement of the labral tear, the patient usually is able to bear weight as tolerated on the involved extremity. Such patients can progress through the same exercises as those designed for a patient before surgery as long as no symptoms are present. However, active straight leg raising should be avoided. The latter movement also would include any type of trunk curl with the hip in flexion, such as performing a sit-up. Any exercises requiring hip extension beyond neutral, such as prone hip extension exercises or lunges, in which the hip on the stance side is hyperextended, also should be avoided.

Cycling is a good activity, but a recumbent bicycle should be avoided because of the excessive hip flexion and the tendency to use the hip flexor muscles to maintain the foot on the pedal. As with a patient before surgery, hip rotation under load should be avoided, and the patient should be trained not to rotate the acetabulum on the femur. One of the most important interventions is to correct any gait faults, particularly knee hyperextension, which causes hip hyperextension during stance. Lewis et al⁶⁵ showed that anterior joint reaction forces are increased by walking in hip hyperextension and by performing hip extension in the prone position, when the hamstring muscle contribution to the motion is greater than the gluteus maximus muscle contribution.⁵⁸ Furthermore, Lewis et al⁶⁶ noted that walking in hip hyperextension can increase the angular hip flexion

impulse or the area under the flexion moment curve, thereby increasing demands on the anterior hip joint. Most importantly, no exercises should cause pain, and all functional activities should be corrected so that they also do not cause pain.

When the surgical intervention involves not only labral debridement but also joint resurfacing or cartilage growth-stimulating procedures, the patient usually is non-weight bearing or toe-touch weight bearing for 6 weeks, followed by weight bearing as tolerated. During this initial 6-week period, active and active-assisted exercises in gravity-minimized positions are used to maintain motions of the hip. Stationary cycling without resistance is a good exercise to provide motion to the hip and maintain endurance of the lower-extremity musculature. Again, a recumbent bicycle should not be used. In addition, any end-range hip flexion is best performed passively rather than actively and should be performed only in a pain-free range.

Surgery

When conservative management does not resolve a patient's symptoms, surgical intervention often is used. Repair of the torn tissue has been attempted, as some authors^{10,15} believe that the labrum may have the potential to heal. In a study by Klaue et al⁴² of 24 young adults with labral tears, the tear was surgically repaired in 12 patients and excised in the other 12 patients. The patients with the repaired labrum had the slowest recovery, and 17% (2 of 12) required a second procedure when the tissue tore again.⁴² Excision or debridement of the torn tissue by arthroscopy is the most common procedure. Multiple authors^{3,30,31,35,37} described case studies in which there was prompt resolution of symptoms following surgical debridement. However, studies of larger numbers of patients demonstrated a variety of results. In a study by Farjo et al,⁴ 28 patients (average age=41 years, range=14–72) who underwent arthroscopic debridement of a labral tear were questioned with regard to their pain, mechanical symptoms, general activity level, activities of daily living, work ability, and ability to return to sporting activities. Only 13 of the 28 patients (46%) reported being “better” or “much better” in all of these categories when monitored for at least 1 year.⁴ Santori and Villar²⁹ found slightly better results in a study of 58 patients (average age=36.7 years, range=8–70) who underwent resection of a labral tear. When questioned with regard to whether or not they were satisfied with the results of their surgery, 39 of the 58 patients (67.3%) reported being “pleased” with the results of the surgery, whereas 32.7% were not pleased.²⁹ The mean follow-up time for this study was 3.5 years.

Modifiers of surgical outcomes. Hip dysplasia and the presence of osteoarthritis have been found to influence

the benefits of labral tear debridement. In an intervention study, Bonnomet et al³⁶ found that 2 patients with dysplasia but without chondral lesions continued to have residual pain following arthroscopic treatment of a labral tear, whereas 3 patients without dysplasia or chondral lesions were all pain-free at the 4-year follow-up, indicating that dysplasia may influence the benefit of labral tear resection. Better results were reported when the labral tear was excised and a procedure to correct the hip dysplasia was performed. Dorrell and Catterall²⁵ reported on 11 patients (average age=32.6 years, range=13–47) who had acetabular dysplasia and an associated labral tear and who received surgical intervention. They found that the best surgical outcomes were achieved when the torn labrum was excised and a procedure to improve the containment of the femoral head within the acetabulum was performed. Eight patients initially receiving this intervention reported relief of their symptoms. In 2 patients in whom only excision of the labral tear was performed, symptom relief was incomplete, and a second surgery was needed to improve the containment of the femoral head. In one patient, only a procedure to improve the containment was performed initially, and it failed to relieve the patient's symptoms. This patient experienced rapid radiographic and clinical deterioration over the next 18 months, necessitating a total hip replacement. These cases suggest that treating both the labral tear and the hip dysplasia is important for optimal results.

The presence of chondral lesions of the femur or the acetabulum also has been implicated as an indicator of a poorer prognosis following excision of a labral tear.^{4,8,36,67} Farjo et al⁴ found a significant correlation between outcome and presence of arthritis on radiography. Only 21% of patients (3 of 14) with arthritis detectable on radiographs had good results from surgery, compared with 75% of patients without arthritis.⁴ Furthermore, 43% of patients (6 of 14) with arthritis went on to undergo total hip arthroplasty, whereas only 14% of patients (2 of 14) without arthritis went on to have total hip arthroplasty.⁴ Arthroscopic detection of chondromalacia was an even stronger indicator of poor long-term prognosis.⁴ Similarly, Byrd and Jones⁸ reported less symptomatic improvement following resection of labral tears in patients with articular surface damage than in patients without articular surface damage. Bonnomet et al further commented, "Resection of the labral lesion is immediately effective but does not prevent long-term degradation of the joint if there is an associated chondral lesion."^{36(p787)} This comment emphasizes the importance of early effective intervention in this patient population.

Risks of surgical intervention and complications. Debridement of a labral tear by hip arthroscopy includes risks.

The overall reported complication rate with arthroscopy of the hip ranges from 1.4% to 25%.^{4,6–8,36,68–72} The complications include neurovascular damage, instrument failure, articular damage, and other injuries. Neurovascular complications may be related to prolonged traction or direct trauma and are the most commonly reported complications. The nerves most often involved are the sciatic^{4,8,72} and pudendal nerves.^{4,68,71} These nerve palsies are typically transient and resolve in 2 hours⁷⁰ to 3 weeks.⁷¹

Rates of articular surface damage, although an admitted possible complication,⁸ have not been reported in any studies found to date. Dorfmann and Boyer⁶⁹ reported that "scuffing of the cartilage occurred in a few cases" but made no attempt to quantify it. Clarke et al⁷⁰ used the number of cases in which access to the joint was considered difficult to estimate a complication rate of 18%. This rate may represent the upper limit of the rate of articular surface damage during hip arthroscopy.

Summary

Acetabular labral tears are a recently recognized source of hip pain, particularly in the anterior hip or groin region. Except in cases of specific trauma, the etiology of labral tears is often difficult to determine. Labral tears often evade detection by noninvasive means. Once they are diagnosed, conservative medical treatment has not proven to be effective, and the appropriate physical therapy intervention has yet to be established. Surgical treatment results in short-term improvement, but the long-term outcomes are still unknown. Because labral tears have been associated with a higher risk for joint degeneration, including osteoarthritis, this area warrants further investigation, especially with regard to prevention, early detection, and appropriate physical therapy and medical treatment. In general, a physical therapist should suspect an acetabular labral tear when a patient with normal radiographs complains of a long duration of anterior hip or groin pain and clicking, pain with passive hip flexion combined with adduction and medial rotation, and pain with an active straight leg raise and has minimal to no restriction in ROM.

References

- 1 Anderson K, Strickland SM, Warren R. Hip and groin injuries in athletes. *Am J Sports Med.* 2001;29:521–533.
- 2 McCarthy JC, Noble PC, Schuck MR, et al. The Otto E. Aufranc Award: the role of labral lesions to development of early degenerative hip disease. *Clin Orthop.* 2001;393:25–37.
- 3 Mason JB. Acetabular labral tears in the athlete. *Clin Sports Med.* 2001;20:779–790.
- 4 Farjo LA, Glick JM, Sampson TG. Hip arthroscopy for acetabular labral tears. *Arthroscopy.* 1999;15:132–137.
- 5 O'Leary JA, Berend K, Vail TP. The relationship between diagnosis and outcome in arthroscopy of the hip. *Arthroscopy.* 2001;17:181–188.

- 6 Fitzgerald RH Jr. Acetabular labrum tears: diagnosis and treatment. *Clin Orthop*. 1995;311:60–68.
- 7 McCarthy JC, Busconi B. The role of hip arthroscopy in the diagnosis and treatment of hip disease. *Orthopedics*. 1995;18:753–756.
- 8 Byrd JW, Jones KS. Prospective analysis of hip arthroscopy with 2-year follow-up. *Arthroscopy*. 2000;16:578–587.
- 9 Narvani AA, Tsiridis E, Kendall S, et al. A preliminary report on prevalence of acetabular labrum tears in sports patients with groin pain. *Knee Surg Sports Traumatol Arthrosc*. 2003;11:403–408.
- 10 Petersen W, Petersen F, Tillmann B. Structure and vascularization of the acetabular labrum with regard to the pathogenesis and healing of labral lesions. *Arch Orthop Trauma Surg*. 2003;123:283–288.
- 11 Abe I, Harada Y, Oinuma K, et al. Acetabular labrum: abnormal findings at MR imaging in asymptomatic hips. *Radiology*. 2000;216:576–581.
- 12 Lecouvet FE, Vande Berg BC, Malghem J, et al. MR imaging of the acetabular labrum: variations in 200 asymptomatic hips. *AJR*. 1996;167:1025–1028.
- 13 Won YY, Chung IH, Chung NS, Song KH. Morphological study on the acetabular labrum. *Yonsei Med J*. 2003;44:855–862.
- 14 Cotten A, Boutry N, Demondion X, et al. Acetabular labrum: MRI in asymptomatic volunteers. *J Comput Assist Tomogr*. 1998;22:1–7.
- 15 Seldes RM, Tan V, Hunt J, et al. Anatomy, histologic features, and vascularity of the adult acetabular labrum. *Clin Orthop*. 2001;382:232–240.
- 16 Keene GS, Villar RN. Arthroscopic anatomy of the hip: an in vivo study. *Arthroscopy*. 1994;10:392–399.
- 17 Kelly BT, Williams RJ III, Philippon MJ. Hip arthroscopy: current indications, treatment options, and management issues. *Am J Sports Med*. 2003;31:1020–1037.
- 18 Petersilge CA, Haque MA, Petersilge WJ, et al. Acetabular labral tears: evaluation with MR arthrography. *Radiology*. 1996;200:231–235.
- 19 Czerny C, Hofmann S, Urban M, et al. MR arthrography of the adult acetabular capsular-labral complex: correlation with surgery and anatomy. *AJR*. 1999;173:345–349.
- 20 Kim YT, Azuma H. The nerve endings of the acetabular labrum. *Clin Orthop*. 1995;320:176–181.
- 21 Tan V, Seldes RM, Katz MA, et al. Contribution of acetabular labrum to articulating surface area and femoral head coverage in adult hip joints: an anatomic study in cadavera. *Am J Orthop*. 2001;30:809–812.
- 22 Philippon MJ. The role of arthroscopic thermal capsulorrhaphy in the hip. *Clin Sports Med*. 2001;20:817–829.
- 23 McCarthy J, Noble P, Aluisio FV, et al. Anatomy, pathologic features, and treatment of acetabular labral tears. *Clin Orthop*. 2003;406:38–47.
- 24 Leunig M, Podeszwa D, Beck M, et al. Magnetic resonance arthrography of labral disorders in hips with dysplasia and impingement. *Clin Orthop*. 2004;418:74–80.
- 25 Dorrell JH, Catterall A. The torn acetabular labrum. *J Bone Joint Surg Br*. 1986;68:400–403.
- 26 Hlavacek M. The influence of the acetabular labrum seal, intact articular superficial zone and synovial fluid thixotropy on squeeze-film lubrication of a spherical synovial joint. *J Biomech*. 2002;35:1325–1335.
- 27 Ferguson SJ, Bryant JT, Ganz R, Ito K. The influence of the acetabular labrum on hip joint cartilage consolidation: a poroelastic finite element model. *J Biomech*. 2000;33:953–960.
- 28 Ferguson SJ, Bryant JT, Ganz R, Ito K. An in vitro investigation of the acetabular labral seal in hip joint mechanics. *J Biomech*. 2003;36:171–178.
- 29 Santori N, Villar RN. Acetabular labral tears: result of arthroscopic partial limbectomy. *Arthroscopy*. 2000;16:11–15.
- 30 Byrd JW. Labral lesions: an elusive source of hip pain case reports and literature review. *Arthroscopy*. 1996;12:603–612.
- 31 Ikeda T, Awaya G, Suzuki S, et al. Torn acetabular labrum in young patients. Arthroscopic diagnosis and management. *J Bone Joint Surg Br*. 1988;70:13–16.
- 32 Nelson MC, Lauerman WC, Brower AC, Wells JR. Avulsion of the acetabular labrum with intra-articular displacement. *Orthopedics*. 1990;13:889–891.
- 33 Binningsley D. Tear of the acetabular labrum in an elite athlete. *Br J Sports Med*. 2003;37:84–88.
- 34 Saw T, Villar R. Footballer's hip a report of six cases. *J Bone Joint Surg Br*. 2004;86:655–658.
- 35 Altenberg AR. Acetabular labrum tears: a cause of hip pain and degenerative arthritis. *South Med J*. 1977;70:174–175.
- 36 Bonnomet F, Lefebvre Y, Clavert P, et al. Arthroscopic treatment of acetabular labrum lesions: a series of 12 patients with a 4-year follow-up [in French]. *Rev Chir Orthop Reparatrice Appar Mot*. 2000;86:787–793.
- 37 Hase T, Ueo T. Acetabular labral tear: arthroscopic diagnosis and treatment. *Arthroscopy*. 1999;15:138–141.
- 38 Coleman SS. *Congenital Dysplasia and Dislocation of the Hip*. St Louis, Mo: Mosby; 1978.
- 39 Li PL, Ganz R. Morphologic features of congenital acetabular dysplasia: one in six is retroverted. *Clin Orthop*. 2003;416:245–253.
- 40 Robertson DD, Essinger JR, Imura S, et al. Femoral deformity in adults with developmental hip dysplasia. *Clin Orthop*. 1996;327:196–206.
- 41 Lane NE, Lin P, Christiansen L, et al. Association of mild acetabular dysplasia with an increased risk of incident hip osteoarthritis in elderly white women: the study of osteoporotic fractures. *Arthritis Rheum*. 2000;43:400–404.
- 42 Klaue K, Durnin CW, Ganz R. The acetabular rim syndrome: a clinical presentation of dysplasia of the hip. *J Bone Joint Surg Br*. 1991;73:423–429.
- 43 Hickman JM, Peters CL. Hip pain in the young adult: diagnosis and treatment of disorders of the acetabular labrum and acetabular dysplasia. *Am J Orthop*. 2001;30:459–467.
- 44 McCarthy JC, Lee JA. Acetabular dysplasia: a paradigm of arthroscopic examination of chondral injuries. *Clin Orthop*. 2002;405:122–128.
- 45 Siebenrock KA, Schoeniger R, Ganz R. Anterior femoro-acetabular impingement due to acetabular retroversion: treatment with peri-acetabular osteotomy. *J Bone Joint Surg Am*. 2003;85:278–286.
- 46 Neumann DA. The hip. *Kinesiology of the Musculoskeletal System: Foundations for Physical Rehabilitation*. St Louis, Mo: Mosby; 2002:387–433.
- 47 Kapandji IA. *The Physiology of the Joints: Annotated Diagrams of the Mechanics of the Human Joints*. 2nd ed. New York, NY: Churchill Livingstone; 1983.
- 48 Lavigne M, Parvizi J, Beck M, et al. Anterior femoroacetabular impingement, part I: techniques of joint preserving surgery. *Clin Orthop*. 2004;418:61–66.

- 49 Ganz R, Parvizi J, Beck M, et al. Femoroacetabular impingement: a cause for osteoarthritis of the hip. *Clin Orthop*. 2003;417:112–120.
- 50 Ito K, Minka MA, Leunig M, et al. Femoroacetabular impingement and the cam-effect: a MRI-based quantitative anatomical study of the femoral head-neck offset. *J Bone Joint Surg Br*. 2001;83:171–176.
- 51 Siebenrock KA, Wahab KH, Werlen S, et al. Abnormal extension of the femoral head epiphysis as a cause of cam impingement. *Clin Orthop*. 2004;418:54–60.
- 52 Bache CE, Clegg J, Herron M. Risk factors for developmental dysplasia of the hip: ultrasonographic findings in the neonatal period. *J Pediatr Orthop B*. 2002;11:212–218.
- 53 Givens-Heiss DL, Krebs DE, Riley PO, et al. In vivo acetabular contact pressures during rehabilitation, part II: postacute phase. *Phys Ther*. 1992;72:700–705.
- 54 Mitchell B, McCrory P, Brukner P, et al. Hip joint pathology: clinical presentation and correlation between magnetic resonance arthrography, ultrasound, and arthroscopic findings in 25 consecutive cases. *Clin J Sport Med*. 2003;13:152–156.
- 55 Suzuki S, Awaya G, Okada Y, et al. Arthroscopic diagnosis of ruptured acetabular labrum. *Acta Orthop Scand*. 1986;57:513–515.
- 56 Walker JM. Histological study of the fetal development of the human acetabulum and labrum: significance in congenital hip disease. *Yale J Biol Med*. 1981;54:255–263.
- 57 Stansfield BW, Nicol AC. Hip joint contact forces in normal subjects and subjects with total hip prostheses: walking and stair and ramp negotiation. *Clin Biomech*. 2002;17:130–139.
- 58 Lewis CL, Sahrman SA, Moran DW. Predicted hip joint reaction forces during prone hip extension with varying contribution from the gluteal muscles. In: Proceedings CD of the American Society of Biomechanics 28th Annual Conference; September 8–11, 2004; Portland, Ore.
- 59 Wenger DE, Kendell KR, Miner MR, Trousdale RT. Acetabular labral tears rarely occur in the absence of bony abnormalities. *Clin Orthop*. 2004;426:145–150.
- 60 Czerny C, Hofmann S, Neuhold A, et al. Lesions of the acetabular labrum: accuracy of MR imaging and MR arthrography in detection and staging. *Radiology*. 1996;200:225–230.
- 61 Leunig M, Werlen S, Ungersbock A, et al. Evaluation of the acetabular labrum by MR arthrography. *J Bone Joint Surg Br*. 1997;79:230–234.
- 62 Bruce W, Van Der WH, Storey G, et al. Bone scintigraphy in acetabular labral tears. *Clin Nucl Med*. 2004;29:465–468.
- 63 Gelberman RH, Cohen MS, Desai SS, et al. Femoral anteversion: a clinical assessment of idiopathic intoeing gait in children. *J Bone Joint Surg Br*. 1987;69:75–79.
- 64 Delp SL, Hess WE, Hungerford DS, Jones LC. Variation of rotation moment arms with hip flexion. *J Biomech*. 1999;32:493–501.
- 65 Lewis CL, Sahrman SA, Moran DW. Walking in greater hip extension increases predicted anterior hip joint reaction forces. In: Proceedings CD of the XXth Congress of the International Society of Biomechanics; July 31–August 5, 2005; Cleveland, Ohio.
- 66 Lewis CL, Sahrman SA, Mueller MJ. Hip flexion moment is reduced when walking with less hip extension ROM [abstract]. *J Orthop Sports Phys Ther*. 2004;34:A26.
- 67 Villar RN. Hip arthroscopy. *Br J Hosp Med*. 1992;47:763–766.
- 68 Kim SJ, Choi NH, Kim HJ. Operative hip arthroscopy. *Clin Orthop*. 1998;353:156–165.
- 69 Dorfmann H, Boyer T. Arthroscopy of the hip: 12 years of experience. *Arthroscopy*. 1999;15:67–72.
- 70 Clarke MT, Arora A, Villar RN. Hip arthroscopy: complications in 1054 cases. *Clin Orthop*. 2003;406:84–88.
- 71 Funke EL, Munzinger U. Complications in hip arthroscopy. *Arthroscopy*. 1996;12:156–159.
- 72 Griffin DR, Villar RN. Complications of arthroscopy of the hip. *J Bone Joint Surg Br*. 1999;81:604–606.