

The role of ultrasonography in the diagnosis and management of idiopathic plantar fasciitis

D. Kane, T. Greaney¹, M. Shanahan, G. Duffy², B. Bresnihan, R. Gibney¹ and O. FitzGerald

Departments of Rheumatology, ¹Diagnostic Imaging and ²Nuclear Medicine, St Vincent's University Hospital, Dublin 4, Ireland

Abstract

Objective. To compare ultrasonography with bone scintigraphy in the diagnosis of plantar fasciitis and to compare ultrasound-guided injection with palpation-guided injection in the management of idiopathic plantar fasciitis.

Methods. Twenty-three patients with a clinical diagnosis of idiopathic plantar fasciitis in 28 heels underwent ultrasonography and bone scintigraphy of both heels at baseline. The patients were randomized to ultrasound- or palpation-guided injection of triamcinolone hexacetonide and xylocaine into the plantar fascia. The 100 mm visual analogue scale (VAS) of pain, the heel tenderness index (HTI), and ultrasonography were performed at baseline and follow-up (mean = 13.4 weeks).

Results. The mean thickness (\pm standard error of the mean) of the plantar fascia, measured by ultrasonography, was 5.7 ± 0.3 mm in symptomatic heels as compared with 3.8 ± 0.2 mm in asymptomatic heels ($P < 0.001$). Ultrasonography findings correlated with bone scintigraphic findings in the diagnosis of plantar fasciitis ($P < 0.001$). Fourteen heels were randomized to ultrasound-guided injection, 10 heels were randomized to palpation-guided injection and four heels were not injected. Ultrasound- and palpation-guided injection resulted in significant mean improvements in VAS [39.6 ± 9.2 (ultrasound) vs 41.5 ± 8 (palpation)] and HTI [1.35 ± 0.2 (ultrasound) vs 1.3 ± 0.4 (palpation)]. There was no significant difference in the response rate following corticosteroid injection by either modality (ultrasound = 13/14, palpation = 8/10). Following injection, the mean thickness of the plantar fascia decreased from 5.7 ± 0.3 mm to 4.65 ± 0.4 mm ($P < 0.01$).

Conclusion. Ultrasonography and bone scintigraphy are equally effective in the diagnosis of plantar fasciitis. Ultrasound-guided injection is effective in the management of plantar fasciitis but is not more effective than palpation-guided injection. Ultrasonography may be used as an objective measure of response to treatment in plantar fasciitis.

KEY WORDS: Ultrasonography, Bone scintigraphy, Plantar fasciitis.

The plantar fascia is a thin band of fibrous tissue which extends from the inferior aspect of the calcaneus to the plantar plates of the metatarsophalangeal joints and the bases of the proximal phalanges of the toes. The fascia is prone to repetitive injury at the posterior insertion due to the role of the fascia in maintaining the medial longitudinal arch and through the stress placed on the fascia by the shock absorbency function of the heel [1]. Plantar fasciitis is thought to result from microtears of the fascia with a subsequent inflammatory response perpetuated by repeated strain through weight bearing. This process is termed idiopathic or primary plantar fasciitis to differentiate it from the enthesopathy which may occur in seronegative spondyloarthropathy. The

long-term prognosis of idiopathic plantar fasciitis is good with resolution of symptoms in the majority of cases after 6 weeks [2]. However, plantar fasciitis may become chronic and the optimal treatment of chronic plantar fasciitis is not yet determined. A wide range of interventions have been reported as being successful in the management of chronic plantar fasciitis reflecting the frequency of this condition. These include night splinting [3, 4], corticosteroid injection [5, 6], radio-frequency lesioning [7], dexamethasone iontophoresis [8], open [9] and endoscopic [10] plantar fasciotomy and surgical neurolysis [11].

The role of corticosteroid injection in the management of plantar fasciitis is controversial. While patients rank corticosteroid injection as a highly effective treatment [12], a single prospective randomized study found no difference between lignocaine alone and lignocaine

plus corticosteroid [13]. Recently, the use of scintigraphic guidance for corticosteroid injection produced 100% response in chronic plantar fasciitis which had been unresponsive to palpation-guided injection [6]. It was postulated that the success of this technique was due to the site of scintigraphic abnormality being posterior to the clinical area of tenderness which is usually palpated to guide injection.

High-resolution ultrasonography of plantar fasciitis demonstrates a thickened hypoechoic plantar fascia [14]. Ultrasonography may be used to guide corticosteroid injection in plantar fasciitis [5], and is cheaper, faster and more widely available than bone scintigraphy. A retrospective, uncontrolled study of ultrasound-guided injection in recalcitrant plantar fasciitis reported complete relief in four of five heels (mean duration of relief = 24 months) [5]. The aim of this study was to compare ultrasonography with scintigraphy in the diagnosis of plantar fasciitis and to compare ultrasound-guided injection with palpation-guided injection in patients with idiopathic plantar fasciitis unresponsive to conservative treatment. Ultrasonography correlated with bone scintigraphy in the diagnosis of plantar fasciitis. Ultrasound- and palpation-guided injection were equally effective in the management of plantar fasciitis. Ultrasonography demonstrated a significant reduction in plantar fascia thickness following corticosteroid injection.

Methods

Patient assessment

Consecutive patients presenting to a rheumatology out-patient clinic with idiopathic plantar fasciitis unresponsive to conservative treatment were assessed. Conservative treatment was defined as the use of non-steroidal anti-inflammatory drugs (NSAIDs) and heel cup or cushion for a minimum period of 8 weeks. Clinical assessment consisted of a routine clinical history, a patient-assessed 100 mm visual analogue scale (VAS) of pain and a physician-assessed heel tenderness index (HTI) assessing pain on palpation (0 = no pain, 1 = painful, 2 = painful and winces, 3 = painful, winces and withdraws). The patients were assessed at presentation and at a follow-up period not less than 6 weeks following heel injection. Exclusion criteria included any history of acute heel trauma preceding the onset of plantar fasciitis, previous surgical intervention to the heel or corticosteroid injection of the heel within 6 weeks prior to assessment.

Ultrasonographic examination

Real-time ultrasonography was performed as described previously [5] with a 7.5 MHz linear array transducer (Acuson; Mountain View, CA, USA) on both symptomatic and asymptomatic heels at initial and follow-up assessment. The thickness of the plantar fascia was measured on a longitudinal view of the heel from the anterior edge of the inferior calcaneal border to the

inferior border of the ultrasound abnormality. Accurate positioning of the transducer was confirmed on a transverse view of the heel. Symptomatic heels were compared with asymptomatic heels. Plantar fasciitis was considered present when the plantar fascia thickness was greater than or equal to 4.5 mm or when there was more than a 1 mm difference in plantar fascia thickness between the symptomatic and asymptomatic heels in association with reduced echogenicity and/or loss of definition of the borders of the fascia distal to the antero-inferior border of the calcaneus [14, 15].

Bone scintigraphy

The subjects received an intravenous injection of 400 mBq Tc-99m methylene diphosphonate and 'three phase' bone scans were performed. The arterial phase, starting at the time of injection, included both feet, with images acquired at 2 s intervals for 60 s. This was followed by 'blood pool' images starting at 60 s intervals and included three static images (anterior, right and left lateral) with 600 kilocounts per image. The 'delayed or osseous phase' was begun at 3 h and included four images (anterior, plantar and medial views of both feet) with 600 Kcts per image. The images were obtained on a digital gamma camera (ADAC) with a low-energy, high-resolution collimator. Bone scintigraphy was obtained prior to corticosteroid injection. The images were interpreted by an experienced nuclear medicine physician. The images were scored visually as + or - relative to background activity in the uninvolved portion of the calcaneus. Both the symptomatic and asymptomatic feet were scored.

Management of plantar fasciitis

The patients were randomized to either palpation- or ultrasound-guided injection under a protocol approved by St Vincent's University Hospital ethics committee. Ultrasound- and palpation-guided injection were both performed with 0.5 ml of triamcinolone acetonide (10 mg/ml) and 0.5 ml of xylocaine 2%. Palpation-guided injection was performed using a medial approach into the heel directing a 21-gauge needle into the area of maximal tenderness on heel palpation with infiltration of the admixture. Ultrasound-guided injection was performed using a medial approach directing a 21-gauge needle into the area of maximal ultrasound abnormality (thickness + hypoechoic changes) under real-time imaging guidance (Fig. 1). The dispersal of the hyperechoic injection admixture was confirmed on post-injection ultrasound. In addition, all patients continued to receive physiotherapy which consisted of patient education, footwear advice and Achilles tendon stretching exercises.

Statistical analysis

Statistical analysis was performed with Statview SE™ statistical analysis software. Values are given in the text as mean ± standard error of the mean with 95% confidence intervals (CI). The Mann-Whitney *U*-test was used for comparison of means and Fisher's exact

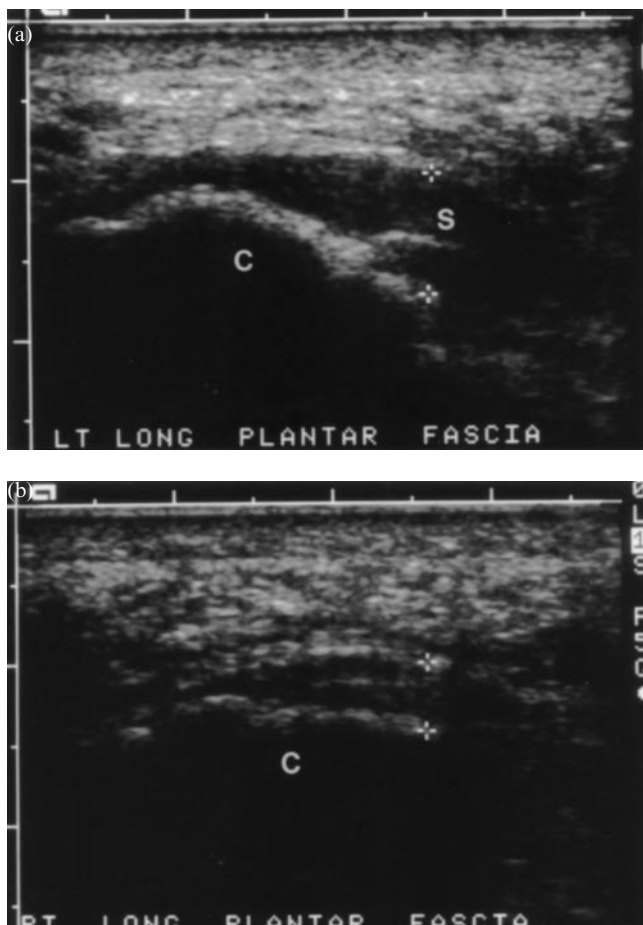


FIG. 1. (a) A 7.5 MHz linear array ultrasound transducer is positioned longitudinally on the medial and inferior surface of the left heel. The plantar fascia is grossly thickened and measures 7.1 mm (distance between crosses) at the antero-inferior border of the calcaneus (C), extending 2–3 cm posteriorly. There is reduced echogenicity of the plantar fascia with loss of definition of fibrillar echotexture and of the fascial borders distal to the anterior border of the calcaneus. A calcaneal spur (S) is present. (b) The right plantar fascia is normal, with a thickness of 3 mm at the antero-inferior border of the calcaneus.

test was used for analysis of frequency tables. A *P* value of <0.05 was considered significant.

Results

Clinical assessment (Table 1)

Twenty-three patients (14 female, nine male) with a clinical diagnosis of plantar fasciitis in a total of 28 heels (18 unilateral, five bilateral; 16 left, 12 right) were assessed. The mean age of the patients was 58 ± 2.19 yr with a mean weight of 84.8 ± 3.0 kg and a mean height of 1.68 ± 0.03 m. The mean body mass index was 30.4 (normal <28). The median duration of symptoms at presentation was 32 ± 9.6 weeks (8–204). The mean VAS score at presentation was 59 ± 4.1 (range 17–100) and the mean HTI score was 1.79 ± 0.17 (range 0–3).

All patients had received a NSAID and a heel cup or cushion for at least 8 weeks without relief of symptoms. Ten patients had had prior palpation-guided injection more than 8 weeks prior to study entry without permanent relief of symptoms (mean number of injections = 1.64, range = 0–4).

Ultrasonographic assessment (Table 1)

Twenty-three patients with a clinical diagnosis of plantar fasciitis in 28 heels underwent ultrasonography. Ultrasonography was positive in 24/28 symptomatic heels [positive predictive value (PPV) = 0.86] and in 2/18 asymptomatic heels [negative predictive value (NPV) = 0.89]. The mean thickness of the plantar fascia at the anterior calcaneal border in all symptomatic heels was 5.7 ± 0.3 mm (95% CI = 5.2–6.3) as compared with 3.8 ± 0.2 mm (95% CI = 3.4–4.4) in all asymptomatic heels ($P < 0.001$).

Scintigraphic assessment (Table 1)

Twenty-two patients with a clinical diagnosis of plantar fasciitis in 27 heels underwent bone scintigraphy. Bone scintigraphy was positive in 20/27 (PPV = 0.75) symptomatic heels and in 1/17 (NPV = 0.94) asymptomatic heels. Eleven patients were noted to have additional asymptomatic areas of increased scintigraphic uptake in the midtarsal and metatarsophalangeal joints consistent with asymptomatic degenerative joint disease. Five had bilateral degenerative joint abnormalities, four had degenerative joint abnormalities in the foot with plantar fasciitis only and two had degenerative joint abnormalities in the asymptomatic contralateral foot only.

Correlation of bone scintigraphy and ultrasonography in the diagnosis of plantar fasciitis (Table 2)

Twenty-two patients with 27 painful heels had paired bone scintigraphy and ultrasonography. There was a highly significant correlation between positive ultrasound findings and the clinical diagnosis of plantar fasciitis (Table 2a, $P < 0.0001$, Fisher's exact test). There was a highly significant correlation between positive scintigraphic findings and the clinical diagnosis of plantar fasciitis (Table 2b, $P < 0.0001$, Fisher's exact test). Ultrasonography and bone scintigraphy correlated significantly in the diagnosis of plantar fasciitis (Table 2c, $P < 0.0001$, Fisher's exact test). Ultrasonography had a higher PPV than bone scintigraphy (0.86 vs 0.75) in the diagnosis of plantar fasciitis, but this was not statistically significant. Using both techniques, 25/27 symptomatic heels demonstrated abnormality, while 2/27 demonstrated none. No alternative pathology such as stress fracture, osteomyelitis or soft tissue tumour was observed in any of the heels with a clinical diagnosis of plantar fasciitis.

The site of the ultrasound abnormality and the site of the scintigraphic abnormality were also compared. On ultrasonography the plantar fascial abnormality was consistently seen extending 1–2 cm from the anterior border of the inferomedial surface of the calcaneus

TABLE 1. Clinical, ultrasonographic and scintigraphic features of plantar fasciitis before and after ultrasound-guided injection (*n* = 14), palpation-guided injection (*n* = 10) and conservative treatment (*n* = 4)

Patient	Heel	Mode of injection	VAS baseline	VAS follow-up	HTI baseline	HTI follow-up	PF thickness in symptomatic heel ^a (baseline)	PF thickness in opposite normal heel ^a (baseline)	Bone scintigraphy findings (baseline)
1	L	Ultrasound	19	0	1	0	4.8	3.9	+
2	R	Ultrasound	92	9	3	1	5.4	3.6	+
3	L	Ultrasound	64	20	2	1	6.9	4.0	+
4	L	Ultrasound	61	5	1	0	7.7	2.7	+
5	L	Ultrasound	73	76	1	0	5.8	–	+
6	L	Ultrasound	17	38	1	1	2.7	2.7	n/a
7	R	Ultrasound	89	0	2	0	5.8	3.5	+
8	L	Ultrasound	70	34	2	1	7.1	3.9	+
9	L	Ultrasound	100	5	2	0	4.9	3.9	+
10	R	Ultrasound	50	45	2	0	4.5	–	0
10	L	Ultrasound	70	45	2	0	4.5	–	+
11	L	Ultrasound	35	30	3	1	4.1	–	0
12	L	Ultrasound	50	10	1	0	4.9	–	0
13	L	Ultrasound	57	0	0	0	6	4.5	+
14	R	Palpation	44	6	2	0	7.5	3.4	+
15	L	Palpation	45	0	1	0	6.6	3.1	+
16	R	Palpation	21	20	3	1	3.8	3.6	+
17	L	Palpation	75	11	2	0	6.4	2.6	+
18	R	Palpation	70	10	2	1	10.1	6.3	+
19	L	Palpation	64	60	2	2	6.4	–	0
11	R	Palpation	87	10	3	0	6.3	–	+
12	R	Palpation	72	50	0	1	5.7	–	0
20	L	Palpation	63	15	3	1	5	3.2	+
21	R	Palpation	56	0	3	2	5.1	6.0	+
22	R	Not injected	26	0	1	0	6.1	4.8	+
5	R	Not injected	73	76	1	0	4.9	–	0
19	R	Not injected	45	0	2	0	3.8	–	0
23	L	Not injected	60	0	2	0	7	3.4	+

PF, plantar fascia.

^aPlantar fascia thickness measured on ultrasonography at the anterior border of the calcaneus.

(Fig. 1). Bone scintigraphy also consistently demonstrated a similar area of increased uptake on the inferomedial surface of the calcaneus, extending to the anterior border of the calcaneus (Fig. 2). In addition to confirming the overlapping localization of the two imaging modalities we used an injection volume of 1 ml which was infiltrated throughout this small area (Fig. 3) to ensure that corticosteroid was infiltrated into all of the area of scintigraphic and ultrasonographic abnormality.

Comparison of ultrasound- and palpation-guided injection (Table 3)

Of the 23 patients initially assessed, two declined to participate in the study of heel injection. Two patients with bilateral plantar fasciitis had resolution of symptoms in one heel each when reviewed after initial bone scintigraphy and ultrasonography. Of 21 remaining patients with 24 painful heels, 14 heels were randomized to ultrasound-guided injection and 10 to palpation-guided injection. Of the 10 patients who had prior heel injection, two declined to participate in the study, five were randomized to the ultrasound-guided group and three were randomized to the palpation-guided group. The mean duration of clinical follow-up was 13.4 weeks (range = 6–48 weeks). There was no significant difference in the duration of symptoms, body

mass index, mean VAS or mean HTI at baseline in the two randomized groups.

Following ultrasound-guided injection, the VAS score decreased from 60.5 ± 6.7 mm (95% CI = 59.7–61.3) to 20.9 ± 6.2 mm (95% CI = 8.7–33.0; *P* < 0.001) and the HTI score decreased from 1.64 ± 0.2 (95% CI = 1.2–2.1) to 0.4 ± 0.1 (95% CI = 0.1–0.6; *P* < 0.001). Following palpation-guided injection, the VAS score decreased from 59.7 ± 6 mm (95% CI = 48–71.5) to 18.2 ± 6.5 mm (95% CI = 5.5–30.9; *P* < 0.001) and the HTI score decreased from 2.1 ± 0.3 (95% CI = 1.5–2.7) to 0.8 ± 0.2 (95% CI = 0.3–1.3; *P* < 0.001). There was no significant difference in the response to injection by either modality (Table 3). The overall response rate (50% reduction in symptoms as assessed by either HTI or VAS) was 93% (13/14) following ultrasound-guided injection and 80% (8/10) following palpation-guided injection.

Ultrasonography as a measure of clinical outcome (Fig. 4)

Follow-up ultrasonography was performed in 16 heels from 15 patients. The mean plantar fascia thickness at the anterior border of the calcaneus decreased from 5.7 ± 0.4 mm (95% CI = 5.1–6.5) to 4.65 ± 0.4 mm (95% CI = 4.0–5.5; *P* < 0.01). There was no evidence of fascial rupture at follow-up ultrasound examination.

TABLE 2

(a) Correlation of ultrasonographic findings with a clinical diagnosis of plantar fasciitis in 22 patients with 27 symptomatic heels and 17 normal heels

	Symptomatic heel	Normal heel	Total
Ultrasound positive	24	2	26
Ultrasound negative	3	15	18
Total	27	17	44

$P < 0.001$, Fisher's exact test, odds ratio = 60, 95% CI = 8.9–402.

(b) Correlation of bone scintigraphic findings with a clinical diagnosis of plantar fasciitis in 22 patients with 27 symptomatic heels and 17 normal heels

	Symptomatic heel	Normal heel	Total
Bone scintigraph positive	20	1	21
Bone scintigraph negative	7	16	23
Total	27	17	44

$P < 0.001$, Fisher's exact test, odds ratio = 46, 95% CI = 5.1–411.2.

(c) Correlation of ultrasonography with bone scintigraphy in the diagnosis of plantar fasciitis in 22 patients with 27 symptomatic heels and 17 normal heels. The number of heels with a clinical diagnosis of plantar fasciitis is given in parentheses

	Bone scintigraph positive	Bone scintigraph negative	Total
Ultrasound positive	19 (19)	7 (5)	26 (24)
Ultrasound negative	2 (1)	16 (2)	18 (3)
Total	21 (20)	23 (7)	44 (27)

$P < 0.001$, Fisher's exact test, odds ratio = 22, 95% CI = 4.0–120.

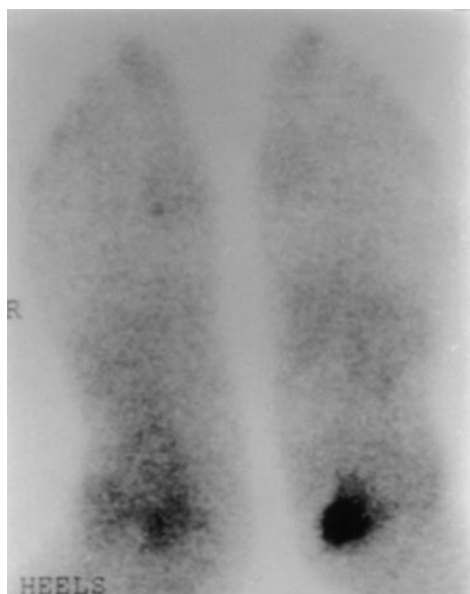


FIG. 2. Bone scintigraphy in the same patient demonstrates abnormal technetium uptake in the inferomedial aspect of the calcaneus in the left foot consistent with a diagnosis of plantar fasciitis.

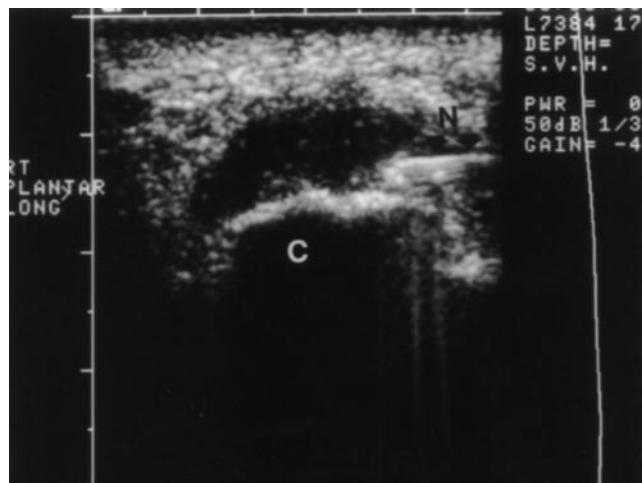

FIG. 3. Transverse view of ultrasound-guided injection. Under ultrasound guidance, a 21-gauge needle (N) has been introduced into the inflamed plantar fascia and perifascial tissues via a medial approach. An injection of triamcinolone acetonide and xylocaine 2% is infiltrated throughout this area under real-time imaging.

Discussion

This is the first study to compare ultrasound-guided corticosteroid and local anaesthetic injection with palpation-guided injection in the management of plantar fasciitis. As a 100% success rate has been reported using scintigraphic guidance when injecting plantar fasciitis, ultrasonography was initially compared with scintigraphy in the diagnosis of plantar fasciitis.

Twenty-three patients with 28 symptomatic heels were assessed at baseline. The majority of the patients were female with a mean age of 58 yr, which is in keeping with the age and sex distribution of previous studies of plantar fasciitis. As with other studies of plantar fasciitis, we noted that the mean body mass index of our cohort was moderately elevated at 30.4, which reflects the association of this condition with obesity [16]. Patients were only entered into the study if their symptoms were not resolving after a minimum of 8 weeks of simple conservative treatment. Ten patients were unresponsive to one or more prior palpation-guided injections but did not differ in response to treatment from patients who had no prior injection (data not shown).

Ultrasonography and bone scintigraphy were confirmed as sensitive and specific diagnostic imaging investigations in plantar fasciitis. In the absence of surgical findings or an accepted gold standard, both investigations were compared with a clinical diagnosis of plantar fasciitis. Ultrasonography was more sensitive than bone scintigraphy (86 vs 75%) in the diagnosis of plantar fasciitis, while bone scintigraphy was more specific than ultrasonography (94 vs 89%). These differences did not reach statistical significance, making either investigation equally efficacious in the diagnosis

TABLE 3. Comparison of ultrasound- and palpation-guided injection in idiopathic plantar fasciitis (mean ± standard error of the mean)

	Ultrasound-guided injection (n = 14)	Palpation-guided injection (n = 10)	P value (Mann-Whitney U-test)
VAS (baseline)	60.5 ± 6.7	59.7 ± 6	0.66
VAS (follow-up)	20.9 ± 6.2	18.2 ± 6.5	0.93
VAS (improvement)	39.6 ± 9.2	41.5 ± 8	0.53
HTI (baseline)	1.64 ± 0.2	2.1 ± 0.3	0.48
HTI (follow-up)	0.4 ± 0.1	0.8 ± 0.2	0.22
HTI (improvement)	1.35 ± 0.2	1.3 ± 0.4	0.34

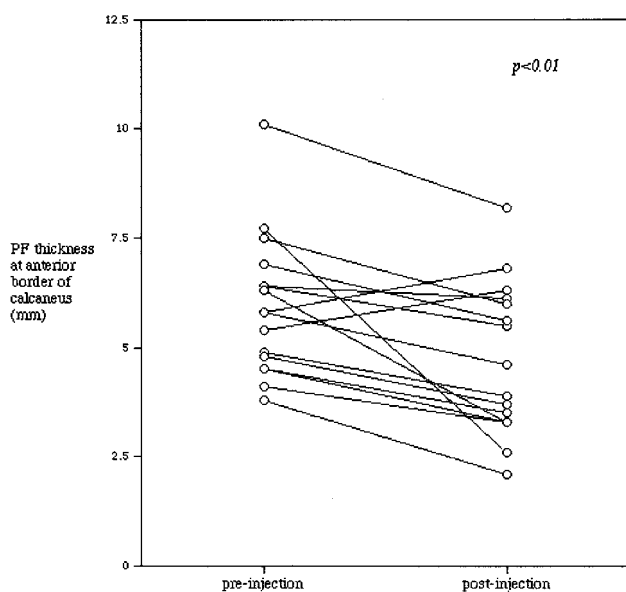


FIG. 4. Ultrasonographic measurement of plantar fascia thickness before and after injection of plantar fasciitis with corticosteroid and local anaesthetic.

of plantar fasciitis. However, ultrasonography is non-radioactive, less expensive and faster than scintigraphy in the diagnosis of plantar fasciitis, thus offering certain advantages. Both ultrasonography and scintigraphy confirmed the clinical diagnosis in a total of 25 of 27 heels, highlighting the accuracy of clinical diagnosis. This suggests that clinical examination is sufficient to establish the initial diagnosis of plantar fasciitis and that the diagnostic role of ultrasonography and scintigraphy should be limited to the evaluation of persistent heel pain in order to rule out rare, alternative pathologies.

In this small series neither modality demonstrated an alternative pathology in the heel, such as stress fracture or soft tissue neoplasia, in the two heels with normal ultrasonography and scintigraphy, although plantar nerve entrapment could not be ruled out [17]. Eleven patients were noted to have additional asymptomatic areas of increased scintigraphic uptake in the midtarsal and metatarsophalangeal joints. These were felt to represent minor degrees of degenerative joint disease

which may reflect a shared aetiology, such as obesity, prolonged weight bearing or repetitive strain, with plantar fasciitis.

There were highly significant improvements in VAS and HTI following injection by both localization techniques, confirming the efficacy of corticosteroid injection in the treatment of plantar fasciitis. Failure to respond to a previous heel injection did not preclude a response to a subsequent injection. However, no statistical difference in outcome was observed between ultrasound- and palpation-guided injection, with both producing a clinical response in the majority of patients. In a randomized, controlled trial, Crawford *et al.* [18] noted that steroid injection produced relief of heel pain at 1 month which did not persist at 3 months' follow-up. As our subjects were reviewed at a mean of 12 weeks, it is possible that if they had been reviewed at 4 weeks a difference in clinical response may have been observed between the two injection modalities.

Ultrasound-guided injection resulted in a clinical response in 93% of heels. This is less than the 100% response rate reported for scintigraphic-guided injection, although it should be noted that scintigraphic-guided injection was not compared with routine palpation-guided injection in that study group. Ultrasonography and bone scintigraphy were shown to correlate closely in the diagnosis of plantar fasciitis. The areas of bone scintigraphic abnormality and ultrasound abnormality were both located on the medial aspect of the inferior surface of the calcaneus. In view of these findings, we felt it was reasonable to assume that injection of the ultrasound abnormality with 1 ml of corticosteroid admixture approximated to scintigraphic localization and injection. More accurate co-localization of the ultrasound and scintigraphic abnormalities may be required to determine whether they are measuring the same point of inflammation.

Occasional reports have expressed concern at the risks of fascial rupture following corticosteroid injection of the heel, estimating a plantar fascia rupture rate of 10% [19, 20]. This was not observed in any of the 16 heels examined ultrasonographically at follow-up. Follow-up ultrasonography did demonstrate a significant reduction in the thickness of the plantar fascia which correlated with clinical improvement. This suggests that ultrasound may be used as an objective measure of therapeutic response in plantar fasciitis. Ultrasonography is useful in the diagnosis and monitoring of

plantar fasciitis, but ultrasound-guided corticosteroid injection was not superior to palpation-guided injection in plantar fasciitis.

References

1. Schepesis AA, Leach RE, Gorzyca J. Plantar fasciitis. Etiology, treatment, surgical results, and review of the literature. *Clin Orthop* 1991;266:185–96.
2. Wolgin M, Cook C, Graham C, Mauldin D. Conservative treatment of plantar heel pain: long-term follow-up. *Foot Ankle Int* 1994;15:97–102.
3. Wapner KL, Sharkey PF. The use of night splints for treatment of recalcitrant plantar fasciitis. *Foot Ankle* 1991;12:135–7.
4. Powell M, Post WR, Keener J, Wearden S. Effective treatment of chronic plantar fasciitis with dorsiflexion night splints: a crossover prospective randomized outcome study. *Foot Ankle Int* 1998;19:10–18.
5. Kane D, Greaney T, Bresnihan B, Gibney R, FitzGerald O. Ultrasound guided injection of recalcitrant plantar fasciitis. *Ann Rheum Dis* 1998;57:383–4.
6. Dasgupta B, Bowles J. Scintigraphic localisation of steroid injection site in plantar fasciitis. *Lancet* 1995;346:1400–1.
7. Sollitto RJ, Plotkin EL, Klein PG, Mullin P. Early clinical results of the use of radiofrequency lesioning in the treatment of plantar fasciitis. *J Foot Ankle Surg* 1997;36:215–9;256.
8. Gudeman SD, Eisele SA, Heidt RS Jr, Colosimo AJ, Stroupe AL. Treatment of plantar fasciitis by iontophoresis of 0.4% dexamethasone. A randomized, double-blind, placebo-controlled study. *Am J Sports Med* 1997; 25:312–6.
9. Lester DK, Buchanan JR. Surgical treatment of plantar fasciitis. *Clin Orthop* 1984;186:202–4.
10. Barrett SL, Day SV, Pignetti TT, Robinson LB. Endoscopic plantar fasciotomy: a multi-surgeon prospective analysis of 652 cases. *J Foot Ankle Surg* 1995; 34:400–6.
11. Baxter DE, Thigpen CM. Heel pain—operative results. *Foot Ankle* 1984;5:16–25.
12. Gill LH, Kiebzak GM. Outcome of nonsurgical treatment for plantar fasciitis. *Foot Ankle Int* 1996;17:527–32.
13. Blockley NJ. The painful heel. *Br Med J* 1956;ii:1277–8.
14. Cardinal E, Chhem RK, Beauregard CG, Aubin B, Pelletier M. Plantar fasciitis: sonographic evaluation. *Radiology* 1996;201:257–9.
15. Wall JR, Harkness MA, Crawford A. Ultrasound diagnosis of plantar fasciitis. *Foot Ankle* 1993;14:465–70.
16. Hill JJ Jr, Cutting PJ. Heel pain and body weight. *Foot Ankle* 1989;9:254–6.
17. Schon LC, Glennon TP, Baxter DE. Heel pain syndrome: electrodiagnostic support for nerve entrapment. *Foot Ankle* 1993;14:129–35.
18. Crawford F, Atkins D, Young P, Edwards J. Steroid injection for heel pain: evidence of short-term effectiveness. A randomised controlled trial. *Rheumatology* 1999;38:974–7.
19. Acevedo JI, Beskin JL. Complications of plantar fascia rupture associated with corticosteroid injection. *Foot Ankle Int* 1998;19:91–7.
20. Sellman JR. Plantar fascia rupture associated with corticosteroid injection. *Foot Ankle Int* 1994;15:376–81.