

# Ultrasonography versus nerve conduction study in patients with carpal tunnel syndrome: substantive or complementary tests?

Y. M. El Miedany, S. A. Aty<sup>1</sup> and S. Ashour<sup>2</sup>

**Objective.** Our aim is to assess the optimal discriminatory sonographic criteria and relevant threshold values in patients with carpal tunnel syndrome (CTS) and to evaluate quantitative ultrasonography (US) as a tool for diagnosis and treatment of patients suffering from carpal tunnel syndrome in comparison with electrophysiological study.

**Methods.** Seventy-eight patients with CTS and 78 asymptomatic controls were assessed and underwent ultrasonography of the wrists. All patients and controls completed a self-administered questionnaire. Electrophysiological testing was done for all patients and control subjects. Data from the patient and the control groups were compared to determine the diagnostic relations in patients with CTS and the grade of severity.

**Results.** There was a high degree of correlation between the conduction abnormalities of the median nerve as detected by electrodiagnostic tests, self-administered assessment and the measurement of the cross-sectional area of the nerve by US ( $P < 0.05$ ). Various levels of disease severity could also be illustrated by US, giving confident results for diagnosis, treatment planning and following the patients with CTS. In 16 patients (17%) tenosynovitis/localized swelling in the tendons in the carpal tunnel was the primary cause of CTS. A cut-off point of  $10 \text{ mm}^2$  for the mean cross-sectional area of the median nerve was found to be the upper limit for normal values. Based on the results of this study, an algorithm for evaluation and management of CTS has been suggested.

**Conclusion.** High-frequency US examination of the median nerve and measurement of its cross-sectional area should be strongly considered as a new alternative diagnostic modality for the evaluation of CTS. In addition to being of high diagnostic accuracy it is able to define the cause of nerve compression and aids treatment planning; US also provides a reliable method for following the response to therapy.

**KEY WORDS:** Carpal tunnel syndrome, Ultrasonography, Nerve conduction study.

Carpal tunnel syndrome (CTS) is the most common form of peripheral nerve entrapment and is particularly prevalent in middle-aged women [1–4]. Although it is well accepted that compression of the median nerve within the carpal tunnel leads to the symptom complex, the underlying aetiology is often uncertain. In most cases carpal tunnel syndrome can be readily identified by the examining clinician, and the clinical findings alone may be sufficient for diagnosis [4], while nerve conduction studies are useful mainly in the less typical cases and in cases in which other conditions, such as entrapment of other nerves, cervical neural compression, demyelinating disease, diabetes or peripheral neuritis, could cause confusion. Although nerve conduction studies have been reported in some studies to be highly specific [5], other studies noted a substantial false positive and false negative rate of 10–20% [6–9]. However, while nerve conduction studies often indicate the level of the lesion, they do not provide spatial information about the nerve or its surroundings that could help in determining aetiology. In recent years, imaging techniques such as magnetic resonance imaging (MRI) [10–13] and sonography [14–17] have been shown to be of value in the diagnosis of carpal tunnel syndrome. Both have an advantage over nerve conduction study in that they provide information about the possible causes of CTS, such as rheumatoid arthritis tenosynovitis or synovitis of the wrist [18, 19]. Imaging criteria for MRI and sonography for carpal tunnel syndrome appeared to be the same [1, 13, 20, 21]. Compared

with MR imaging, sonography has the potential advantages of lower cost, shorter examination time and the possibility of sonographically guided intervention and treatment. Although more than one study was done to assess the value of quantitative sonography in the diagnosis of CTS [3, 11, 22, 23], these studies were mainly concerned with investigating the sonographic features of median nerve as well as the carpal tunnel itself in a group of patients. The impact of such findings upon the handling of patients suffering from the disease from the clinical point of view and whether sonography can be used as a substantive or a complementary tool in the diagnosis of CTS has not yet been fully clarified. Therefore we performed this prospective study aimed at first assessing the optimal discriminatory sonographic criteria and relevant threshold values in patients with CTS and secondly evaluating quantitative sonography as a tool for diagnosis, treatment planning and follow-up of patients with CTS in comparison with electrophysiological studies.

## Materials and methods

### Patients

This was a cross-sectional, age-group-matched case-control study. Seventy-eight patients were included in this study. Eighteen patients had bilateral symptoms. All participants had both hands

Rheumatology and Rehabilitation Department, <sup>1</sup>Radiology Department, <sup>2</sup>Neuropsychiatry Department, Ain Shams University, Cairo, Egypt.

Submitted 10 January 2004; revised version accepted 12 March 2004.

Correspondence to: Y. El Miedany, Darent Valley Hospital, Dartford, Kent DA2 8DA, UK. E-mail: yasser\_elmiedany@yahoo.com

examined sonographically and electrophysiologically but we considered each wrist separately in clinical diagnosis. Thus in total 96 hands were analysed in this work. Our patient group was 51 females and 27 males with ages ranging between 29 and 67 years; the limit for age matching was a 5-yr interval for both men and women. The duration of illness ranged from 2 months to 14 months.

#### *Definition of cases and data collection at initial evaluation*

Diagnosis of CTS was based on the American Academy of Neurology clinical diagnostic criteria (1993) [24] summarized here: paraesthesia; pain; swelling, weakness or clumsiness of the hand provoked or worsened by sleep; sustained hand or arm position; repetitive action of the hand or wrist that is mitigated by changing posture or by shaking of the hand; sensory deficit or hypotrophy of the median innervated thenar muscle; symptoms elicited by the Phalen test (1 min passive forced flexion of the wrist), performed on each patient.

A detailed clinical history, a careful examination and extended neurophysiological evaluation were always performed. Laboratory investigations to diagnose any secondary cause for CTS were done for all patients. Only idiopathic CTS (with no aetiological factors) was included. Exclusion criteria included: (1) history of wrist surgery (including carpal tunnel injection) or fracture; (2) clinical or electrophysiological evidence of an accompanying condition that mimics CTS or interferes with its evaluation, such as proximal median neuropathy, cervical radiculopathy or polyneuropathy; (3) history of underlying disorders associated with CTS such as diabetes mellitus, rheumatoid arthritis, pregnancy, acromegaly or hypothyroidism. Forty-seven of our patients group underwent decompression surgery.

#### *Control group*

Seventy-eight healthy, age-group-matched subjects with no signs or symptoms of CTS were studied as a control group: 50 females and 28 males. The control subjects were either from the healthy subjects accompanying the patients during their visits to the hospital (mostly housewives) or from the hospital staff. They were subjected to full neurological and medical examination to verify their normality. All patients showed negative results on the self-administered questionnaire. In addition, they were subjected to the same laboratory investigations as the patient group. Nerve conduction studies and sonography of both wrists were done for all subjects included in the control group (total 156 hands).

#### *Patient-oriented data: Arabic version of the Boston Carpal Tunnel Questionnaire (A-BCTQ)*

A patient-oriented measurement was used: the Arabic version of the BCTQ [25]. The BCTQ evaluates two domains of CTS, namely 'symptoms', assessed with an 11-item scale (pain, paraesthesia, numbness, weakness, and nocturnal symptoms) and 'functional status' assessed with an eight-item scale (writing, buttoning, holding, gripping, bathing, dressing). The questionnaire was presented in multiple-choice format, and scores were assigned from 1 point (mildest) to 5 points (most severe). No response to a certain question was given 0 points. Each score is calculated as the mean of the responses of the individual items. Patients were divided into five groups according to their mean score: extreme (4.1–5 points), severe (3.1–4 points), moderate (2.1–3 points), mild (1.1–2 points) and minimal (0.1–1 point) [25]. No patients showed negative results on the self-administered questionnaire. The patients who had bilateral symptoms were asked to answer two questionnaires, one for each hand separately. In order to avoid any influence of

the physician or the neurophysiological data on the patient-oriented results, the A-BCTQ was always completed in the waiting room.

#### *Electrodiagnostic evaluation*

Electrodiagnostic studies were performed for all subjects included in this study according to the protocol [26, 27] inspired by the American Association of Electrodiagnostic Medicine recommendations [28] using a Dantec Keypoint. All testing was done in the same room and in similar temperature conditions. When standard tests (median sensory nerve conduction velocity in two-digit/wrist segments and median distal motor latency from the wrist to the thenar eminence) yielded normal results, we always performed further segmental over a short distance of 7–8 cm [29, 30] or comparative median/ulnar studies [31, 32]. F-wave testing was done for all patients. Measurements performed and cut-off points or normal values used in our study were as follows. (1) Median nerve distal sensory latency, upper limit of normal 3.6 ms. (2) Difference between the median and ulnar nerve distal sensory latencies, upper limit of normal 0.4 ms. (3) Distal motor latency over the thenar, upper limit of normal 4.3 ms. (4) Median motor nerve conduction velocity, lower limit of normal 49 m/s. (5) Median sensory nerve conduction velocity, lower limit of normal 49 m/s [33]. The severity of electrophysiological CTS impairment was assessed according to the classification reported by Padua [34]. CTS hands were divided into six groups on the basis of neurophysiological findings on all tests:

- Negative: normal findings on all tests.
- Minimal: abnormal segmental or comparative tests only.
- Mild: abnormal digit/wrist sensory nerve conduction velocity and normal distal motor latency.
- Moderate: abnormal digit/wrist sensory nerve conduction velocity and abnormal distal motor latency.
- Severe: absence of sensory response and abnormal distal motor latency.
- Extreme: absence of motor and sensory responses.

#### *Sonography*

All patients underwent high-resolution real-time sonography of the carpal tunnel (both hands) using a Diasonics Gateway Series machine and 12 MHz linear array transducer. To ensure unbiased examination, the examiner was requested not to inquire about symptoms and the patients were asked not to speak about their problem during examination. Sonographic examination was done either on the same day or within 3 days of the electrophysiological study. The sonographic examination was performed with the patient seated in a comfortable position facing the sonographer, with the forearm resting on the table and the palm facing up in the neutral position. The volar wrist crease was used as an initial external reference point, with subsequent modifications during scanning using carpal bony landmarks and internal reference points. The full course of the median nerve in the carpal tunnel was assessed in both transverse and longitudinal planes. The median nerve is located superficial to the echogenic flexor tendons and its size, shape, echogenicity and relationship to the surrounding structures and overlying retinaculum were noted. The amount of synovial fluid and the presence or absence of masses were noted. The continuity of the median nerve and any area of constriction were assessed in both the longitudinal and transverse planes. Measurements were taken for the median nerve at the carpal tunnel inlet proximally and at the carpal tunnel outlet distally. The mean cross-sectional area of the median nerve was measured by tracing

with electronic callipers around the margin of the nerve at the time of sonography (direct tracing). The flattening ratio (defined as the ratio of the major axis of the median nerve to its minor axis) was also assessed at the tunnel inlet and outlet. The thickness of the flexor retinaculum was measured as close to the midline as possible in the midportion of the carpal tunnel. Measurement of the anteroposterior dimension of the carpal tunnel was also assessed at the midpoint of the carpal tunnel at the level of the distal margin of pisiform bone. Median nerve measurements were taken for both patients and control groups. Forty-seven of our patients group underwent surgery for their carpal tunnel problems. Postoperative US was done for the cases that experienced recurrence of their symptoms.

In order to assess the reliability, every seventh subject was asked to return within 24 h for a repeat US. A total of 11 CTS patients and 11 controls were assessed for this purpose.

The nature of the work was explained to all the patients and healthy subjects included in this study. All subjects who shared in this work signed information consent written according to the Declaration of Helsinki.

### Statistical analysis

Statistical analysis was performed using the Student's *t*-test and one-way ANOVA to test differences between groups' means.  $\chi^2$  and Fisher Exact were used for testing the association between qualitative variables. The cut-off point for cross-sectional area was calculated taking the upper limit of the 95% confidence interval for the control or the reference group. Correlation was tested using Pearson's correlation coefficient. Test-retest reliability was tested using the intra-class correlation coefficient. In all tests the *P* value was set at 0.05 and data manipulation and analysis were performed using the SPSS Version 6.

### Results

Ninety-six hands with carpal tunnel syndrome were studied. A positive Phalen's sign was present in 68 hands (70%) while Tinel's test was positive in 51 patients (53%). Table 1 shows the baseline characteristics of the patients and control subjects included in this study.

In comparison with the control group (Figs 1 and 2), US assessment of the median nerve in the patients group showed that the swelling of the median nerve at the entrance to the carpal tunnel appears to be the most reliable criterion for diagnosing CTS (Fig. 3). The US images also demonstrated other changes in the median nerve, such as marginal effacement from oedema and longitudinal irregularities (Fig. 4). Longitudinal evaluation of the abnormal nerve, especially in those patients with moderate to severe abnormal electromyography results, frequently revealed

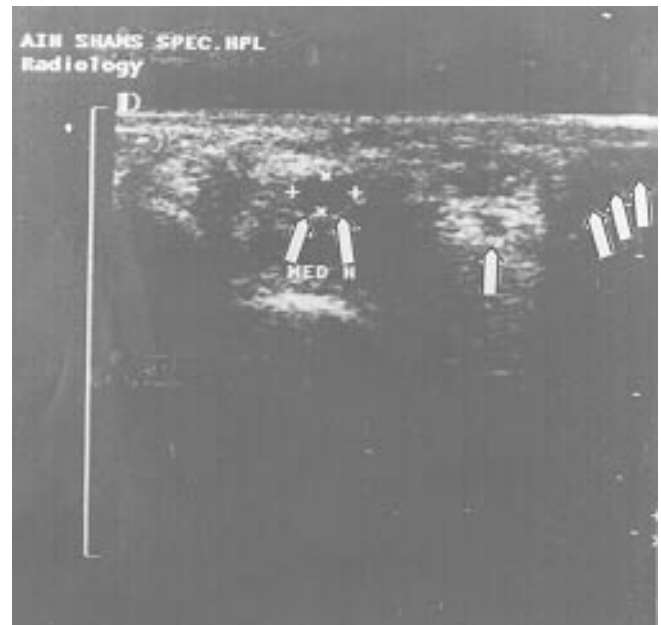


FIG. 1. Normal wrist: transverse scan at the level of pisiform bone showing normal median nerve (hypoechoic and ovoid in shape).

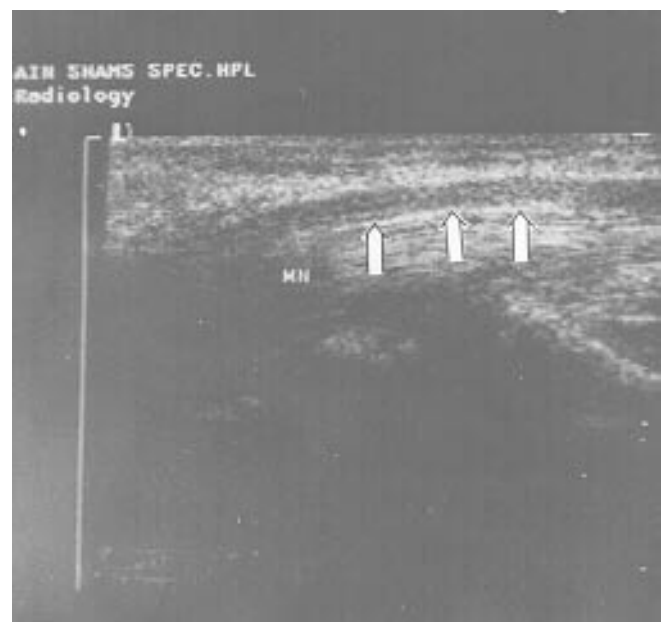


FIG. 2. Longitudinal scan showing normal median nerve.

TABLE 1. Baseline characteristics of the patients and control subjects included in this study

Variable	Patients	Control
Age (yr) (mean $\pm$ S.D.)	44.9 $\pm$ 6.16	44.3 $\pm$ 7.54
Sex (female:male)	51:27	50:28
Duration of symptoms (months) (mean $\pm$ S.D.)	7.75 $\pm$ 4.63	
No. of patients/wrists examined	78/96	78/156
Side affected (no. of patients)		
Right	41	
Left	19	
Bilateral	18	
BMI (mean $\pm$ S.D.)	29.46 $\pm$ 3.49	30.05 $\pm$ 5.41
Forearm length (cm) (mean $\pm$ S.D.)	21.225 $\pm$ 1.251	21.6 $\pm$ 1.594

marked dilatation proximal to the carpal ligament with a sharp anterior calibre change (Fig. 5). Comparing the US measures in the symptomatic hands of 60 patients with unilateral carpal tunnel syndrome with their asymptomatic contralateral hands showed similar findings (Table 2). In 16 patients (17%) there was tenosynovitis/localized swelling in the tendons in the carpal tunnel as the primary cause of CTS (Figs 6 and 7). Electrodiagnostic studies were found to be mildly impaired in these patients while their symptoms and functional status ranged from moderate to severe. In patients who suffered from post-operative recurrence of their symptoms, interstitial oedema and tenosynovitis were found to be the main cause (Fig. 8). Six hands (6%) were negative on the



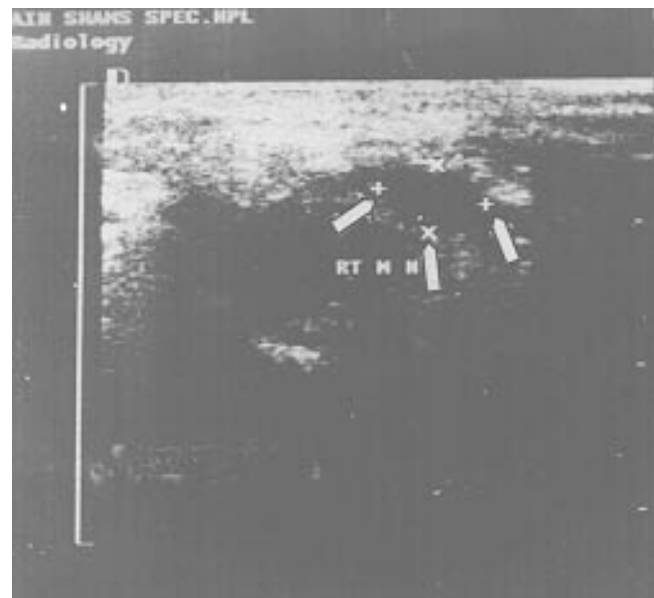


FIG. 3. Transverse scan showing enlarged (swollen) median nerve.




FIG. 4. Transverse scan showing flattening of the median nerve.

electrophysiological tests while only two hands were found negative on the US assessment. One of these two negative hands showed a bifid median nerve (Fig. 9).

Statistical analysis showed a significant positive correlation between the cross-sectional area of the median nerve measured by US, as well as electrodiagnostic severity grades, with patients' oriented measurements. Table 3 shows the distribution of the patients according to the four modalities. Apart from four patients (4%), patients with abnormal electromyography results demonstrated significant correlation with US grades ( $P < 0.01$ ). In addition, results of this study showed a trend of increase in the measures, both of flattening ratio and flexor retinaculum, with the increase in the severity of carpal tunnel syndrome as evident from US and electromyography findings (Table 4). On studying the correlation of different US measurement to each other there was significant correlation ( $P < 0.05$ ) between the cross-sectional area

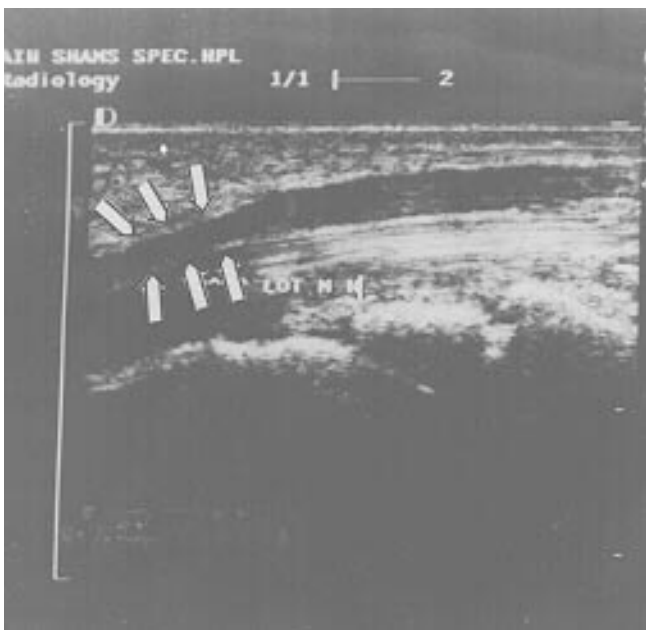

FIG. 5. Longitudinal scan showing indentation (notching) of the median nerve by the flexor retinaculum anteriorly (arrowheads).

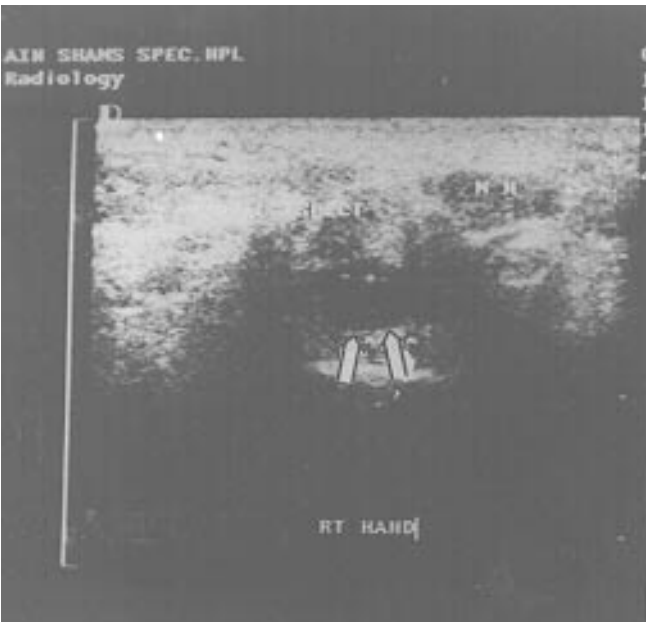


FIG. 6. Transverse scan demonstrating an anechoic cystic lesion deep and on the radial aspect of the median nerve (arrowheads), proved to be a ganglion at surgery.

TABLE 2. Ultrasonographic (US) measures in the symptomatic hands of 60 patients with unilateral carpal tunnel syndrome in comparison with their contralateral asymptomatic ones

US measure	Symptomatic hands (60)	Asymptomatic hands (60)
Flat. ratio (mean $\pm$ s.d.)	2.65 $\pm$ 0.52*	1.75 $\pm$ 0.15
CSA (mm <sup>2</sup> ) (mean $\pm$ s.d.)	15.18 $\pm$ 4.38*	8.81 $\pm$ 3.2
FR (mean $\pm$ s.d.)	1.05 $\pm$ 0.2	0.85 $\pm$ 0.46
AP of CT (mean $\pm$ s.d.)	11.9 $\pm$ 1.3	11.9 $\pm$ 0.91

Flat. ratio, flattening ratio; CSA, cross-sectional area; FR, flexor retinaculum; AP of CT, anteroposterior dimension of carpal tunnel.  
\* $P < 0.01$ .

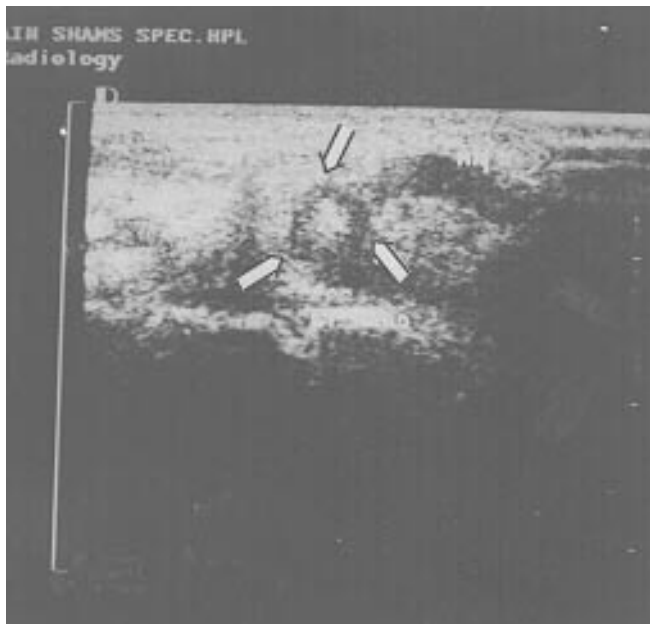


FIG. 7. Transverse scan showing tenosynovitis of the flexor pollicis longus: the tendon appears swollen and surrounded by hypoechoic halo of oedema (arrowheads), median nerve (MN). The tendon could be identified by asking the patient to move the thumb during scanning.

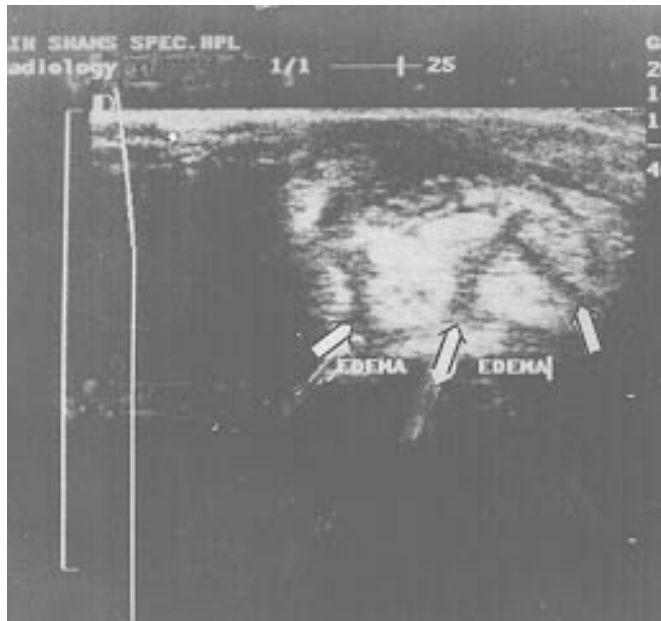


FIG. 8. Transverse scan: post-operative wrist showing abnormally increased fluid surrounding and in between the flexor tendons, denoting synovitis and interstitial oedema.

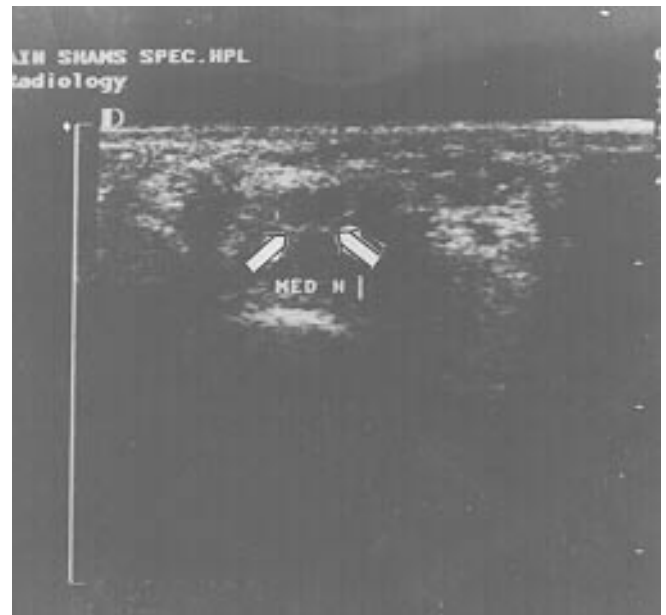


FIG. 9. Transverse scan showing bifid median nerve.

of the median nerve and the flexor retinaculum measurement (Table 5).

Statistical analysis was done using the upper limit of 95% confidence interval to calculate the cut-off point, its specificity and sensitivity, for a pathological mean cross-sectional area of the median nerve that discriminates between cases versus the control group. This was revealed to be 10.03 mm<sup>2</sup>. Similarly the cut-off point for the flattening ratio was found to be 0.3. The same was done when choosing the cut-off points that discriminate between the mild and moderate groups; as well as between the moderate and severe groups. This study revealed that 13.03 and 15.02 mm<sup>2</sup> were the best cut-off points to discriminate between both grades respectively (Table 6). Table 7 shows the relation of different grades of nerve conduction studies to different grades of median nerve cross-sectional area as assessed by US. Results of the test-retest reliability of the different measurements of ultrasonographic examination are shown in Table 8.

## Discussion

The diagnosis of CTS is based mainly on the patient's history and the clinical findings [8, 35]. The value of provocative physical tests, such as Tinel's or Phalen's tests for CTS is controversial and results are often of doubtful clinical significance. Confirmation of CTS is usually based on nerve conduction studies [36]. However, many authors have proposed that conventional electrophysiological studies are not appropriate for detecting mild median nerve compression and that the process causing symptoms of CTS might not be identical to the process causing slowing of nerve

TABLE 3. Distribution of patients according to the different modalities tested

Grade	Extreme	Severe	Moderate	Mild	Minimal	No abnormality	Total no of patients
Symptom Severity Scale: <i>n</i> (%)	11 (12%)	24 (25%)	39 (40%)	21 (22%)	1 (1%)	0 (0%)	96
Functional Status Scale: <i>n</i> (%)	8 (8%)	34 (36%)	25 (26%)	24 (25%)	5 (5%)	0 (0%)	96
NCS grade: <i>n</i> (%)	9 (9%)	18 (19%)	33 (35%)	29 (30%)	1 (1%)	6 (6%)	96
US grade <sup>a</sup> : <i>n</i> (%)	29 (30%)		34 (35%)	31 (33%)		2 (2%)	96

NCS: nerve conduction studies.

<sup>a</sup>Patients were divided according to the sonographic cut-off points suggested in this study.

TABLE 4. Ultrasonographic measurements in relation to EMG grades

US measure	Control group	EMG severity grade (no of patients)			
		Negative (6/96)	Min./mild (30/96)	Moderate (33/96)	Severe/extreme (27/96)
Flat. ratio (mean $\pm$ s.d.)	1.72 $\pm$ 0.01	2.4 $\pm$ 0.03 <sup>a</sup>	2.5 $\pm$ 0.4 <sup>a</sup>	2.8 $\pm$ 0.8 <sup>a,b</sup>	2.9 $\pm$ 0.06 <sup>a,b</sup>
CSA (mm <sup>2</sup> ) (mean $\pm$ s.d.)	8.9 $\pm$ 0.2	11.6 $\pm$ 0.6 <sup>a</sup>	11.7 $\pm$ 0.2 <sup>a</sup>	16.7 $\pm$ 0.3 <sup>a,b</sup>	20.7 $\pm$ 0.1 <sup>a,b,c</sup>
FR (mean $\pm$ s.d.)	0.8 $\pm$ 0.5	0.9 $\pm$ 0.1	1.0 $\pm$ 0.1 <sup>a</sup>	1.1 $\pm$ 0.2 <sup>a,b</sup>	1.12 $\pm$ 0.2 <sup>a,b,c</sup>
AP dimension of CT (mean $\pm$ s.d.)	11.9 $\pm$ 1.3	11.9 $\pm$ 0.8	11.9 $\pm$ 1.6	11.9 $\pm$ 1.4	11.8 $\pm$ 1.1

Flat. ratio, flattening ratio; CSA, cross-sectional area; FR, flexor retinaculum; AP dimension of CT, anteroposterior dimension of carpal tunnel; EMG, electromyography.

<sup>a</sup>Significant difference from the control group.

<sup>b</sup>Significant difference from the mild and negative groups.

<sup>c</sup>Significant difference from the moderate group.

TABLE 5. Correlation of different ultrasonographic measurements with each other

	Flat. ratio	CSA	FR	AP of CT
Flat. ratio	1.00			
CSA	0.169	1.00		
FR	0.108	0.373*	1.00	
AP of CT	0.107	0.145	0.307*	1.00

Flat. ratio, flattening ratio at the proximal carpal tunnel; CSA, cross-sectional area at the proximal carpal tunnel; FR, flexor retinaculum; AP of CT, anteroposterior dimension of carpal tunnel.

\*Significant at  $P < 0.05$ .

TABLE 6. Sensitivity and specificity of US cut-off points that discriminate between different grads of CTS severity as detected by US

Group	CSA (mm <sup>2</sup> )	$P$ value	Sensitivity	Specificity
Controls	<10.03	0.001	97.9%	100%
	>10.03			
Patients	158			
	2			
Mild	<13.03	0.001	98.4%	96.8%
	>13.03			
Moderate and severe	30			
	1			
Moderate	<15.02	0.001	96.6%	99%
	>15.02			
Severe	34			
	1			

CSA, cross-sectional area at proximal carpal tunnel.

TABLE 7. Relation of different grades of NCS to different grades of CSA of median nerve assessed by US

CSA	NCS grade NAD	Min./mild	Moderate	Severe/ extreme
NAD	2	0	0	0
Mild	1	30	0	0
Moderate	1	0	33	0
Severe	2	1	0	27

CSA, cross-sectional area at the proximal carpal tunnel; NCS, nerve conduction study; NAD, no abnormality detected.

conduction [37]. Electrodiagnostic parameters are abnormal only if there is significant demyelination of axonal loss in the large myelinated fibres. In addition, symptoms may be produced by other mechanisms. Although the defined criteria of electrodiagnosis were reproduced to minimize the false negatives in diagnosis, including the 0.3 ms difference between the median and ulnar or the median and radial sensory latencies [38], these criteria also have the potential for false positive results in diagnosing CTS. Some

TABLE 8. Test-retest reliability of the different measurements of US examination

US measure	Correlation coefficient, $r$	$P$ value
CSA	0.943	0.001
Flattening ratio	0.851	0.001
AP	0.879	0.001
Flexor retinaculum	0.823	0.002

CSA, cross-sectional area; AP, anteroposterior dimension of the carpal tunnel.

authors reported more than 40% false positive results using the 0.3 ms difference and proposed more generous criteria [9].

In patients with CTS, anatomical evaluation of the carpal tunnel is a strong plus in diagnosis and management. Chronic focal compression of the median nerve can lead to alteration in its morphology and cause demyelination by mechanical stress, deforming the myelin lamellae. Ischaemia can account for the intermittent paraesthesia that can occur at night or with wrist flexion [39]. Imaging techniques were unimportant in the assessment of CTS until recently. Buchberger *et al.* [1, 16] were the first to quantify changes in carpal tunnel syndrome using sonography. Their findings confirmed those of earlier MRI studies [40, 41]. Later on, other research was published on sonography and MRI for CTS. Current criteria for both MRI and sonography are: swelling of the median nerve at the entrance to the carpal tunnel and flattening of the median nerve and palmar bowing of the flexor retinaculum at the exit from the carpal tunnel. For MRI an additional criterion is increased signal intensity within the median nerve on  $T_2$ -weighted images at the exit from the carpal tunnel in cases of CTS. Thickening of the flexor retinaculum and an increased height of the carpal tunnel, as measured from the apex of the flexor retinaculum convexity to the underlying carpal bone, are also mentioned in both MRI and sonography literature [11, 13, 20–23, 42]. Thus, criteria for MRI and sonography have become similar, but are subject to discussion [43, 44].

In all patients studied, the median nerve demonstrated a consistent and statistically significant increase in cross-sectional area. Variation in the magnitude of the increases was rated corresponding to the severity of CTS as reported by the patients and electrodiagnostic studies. Furthermore, the longitudinally abrupt contour changes along the course of the median nerve were noted to varying degrees relative to the amount of increase in cross-sectional area (i.e. the greater the increase, the greater the contour deformity as the nerve flattens against the unyielding flexor retinaculum). This was confirmed by our finding of significant correlation between cross-sectional area and flexor retinaculum on studying the correlation of different ultrasonographic findings with each other (Table 3).

Our cut-off point of  $10.03 \text{ mm}^2$  for the mean cross-sectional area of the median nerve to distinguish patients from controls corresponds with the previously reported findings in the literature [14, 15, 22, 23]. In a recent study by Wong *et al.* [45] the authors reported choosing a cross-sectional area of  $9.8 \text{ mm}^2$  as a reliable criterion for CTS and made the diagnostic value of sonography approach that of electrophysiological study.

Assessment of cut-off points for moderate and severe cases in comparison to electrodiagnostic measures revealed that a cross-sectional area measurement greater than  $13 \text{ mm}^2$  can be considered positive and corresponds to electrodiagnostic measures in the moderate level, whereas a cross-sectional area at the level of  $15 \text{ mm}^2$  corresponds to a measure in the severe level. These data agree with the findings reported by Lee *et al.* [46], who found that one can be confident of determining the level of severity of median nerve neuropathy based on ultrasound measurement of its cross-sectional area. In their work, they reported that an ultrasound measurement of greater than  $15 \text{ mm}^2$  correlates with electromyography findings of moderate to severe disease and that is statistically distinguished ( $P < 0.05$ ) from a measurement indicating mild to moderate disease.

On assessing the correlation among modalities assessed, a highly significant positive correlation was observed between ultrasound as well as electrodiagnostic measurements; with patient-oriented measures (both the symptom and functional severity scales). This confirms the earlier published studies [47, 48] that reported that patient-oriented measures are a very reliable method for diagnosing CTS and that CTS appears to be an ideal model for the role of a patient-oriented measure in the diagnosis of disease. Padua *et al.* [27] found that the clinical-neurophysiological relationship is very strong, with an exponential increase in functional impairment as the classification of neurophysiological severity progresses. This study showed that, similar to the electrophysiological studies, US has a strong and significant relationship to the clinical and patient-oriented parameters and was even more sensitive than electrophysiological testing.

We believe that having a typical clinical picture of CTS with negative electrophysiological studies does not preclude a diagnosis of CTS. That was the reason why we included the six patients with a typical clinical picture of CTS and negative electrophysiological studies. Dhong *et al.* [47], in a study of the correlation of electrodiagnostic findings with subjective symptoms in CTS, reported that considering that patients' major concerns are their subjective symptoms, we should accept electrodiagnostic data as a supporting reference. Similarly, Padua *et al.* [27] reported that patients with typical CTS symptoms but negative electrophysiological studies have similar symptoms, function and examination findings to the minimally affected group, which is in agreement with our results (Table 2). They hypothesized that negative patients are similar to minimally affected patients except that the neurophysiological findings are still within the normal range. Moreover, in further work Padua *et al.* [30] reported that it is probable that these negative patients will become positive at a subsequent neurophysiological evaluation.

Results of this study showed that there was a trend of increase in the measures of both flattening ratio and flexor retinaculum with the increase in the severity of carpal tunnel flex. While this would seem logical on looking at the flattening ratio, it still seems puzzling on considering the flexor retinaculum thickening trend. On studying the correlation of different US measurements with each other, there was a significant correlation between cross-sectional area and the flexor retinaculum, denoting its importance in the pathogenesis of the disease. These data agree with the findings reported in earlier studies [20–22] and the notes made by the orthopaedic surgeons who reported an increase in the flexor retinaculum thickness in patients with CTS (personal communications).

Earlier studies showed that in interpretation of electrodiagnostic studies of the median nerve age as well as anthropometric

measures should be considered [49–51]. Temperature control along with consideration of age, height, finger circumference and instrumentation is imperative for the appropriate interpretation of electrodiagnostic studies. Increased weight and BMI ( $>29$ ) have been suggested as risk factors for prolonged median nerve distal latency [50]. Also, height was negatively associated with sensory amplitude of both median and ulnar nerves, whereas it was positively associated with median and ulnar sensory distal latencies ( $P < 0.01$ ). Sex, in isolation from highly correlated anthropometric factors such as height, was not found to be a significant predictor of median or ulnar nerve conduction measures [51]. Results of this study showed that there was no difference between the patients and control groups included in the study in terms of body height and body mass index (BMI). This would rule out the anthropometric element as a factor that might alter the interpretation of electrodiagnostic measures in this work. Moreover, this adds another positive point in favour of US versus electrodiagnostic studies in assessment of carpal tunnel syndrome.

In the work done by Lee *et al.* [46] they suggested a new algorithm for evaluating CTS and the median nerve. That protocol classified the cases as mild and severe. However, it ignored the greater percentage of the patients who usually present with moderate compression. The results of this study offer a pragmatic approach to the management of CTS. In our suggested algorithm (Fig. 10) we classified the patients suffering from CTS into three groups (mild, moderate, severe) that match with electrodiagnostic measures. The therapeutic implications have also been clarified in our suggested algorithm. We understand that these options illustrate a change in the focus of CTS diagnosis from electrodiagnostic studies, something that some traditional rheumatologists might find difficult to swallow. However, in agreement with

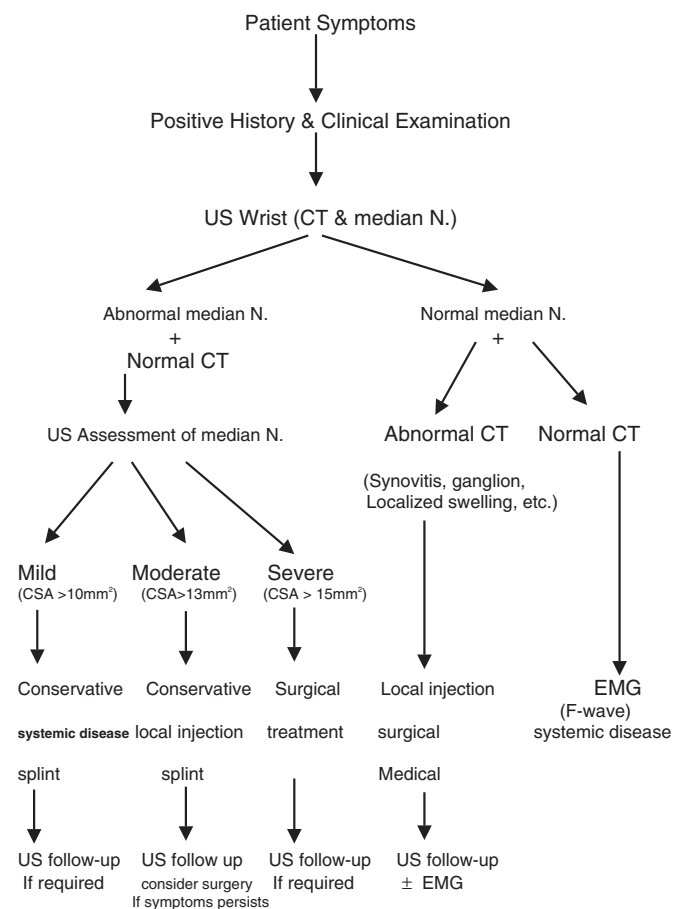


FIG. 10. Suggested algorithm for evaluation and management of carpal tunnel syndrome.



Lee *et al.* [46], considering the difficulties many patients experience with electrodiagnostic studies and the easier, faster and more reliable technique offered by US, we expect that the overwhelming majority of patients would prefer US examination to electromyography as a method for evaluating their disease. However, to evaluate the impact of this strategy on long-term outcome, randomized controlled trials are required.

In conclusion, high-frequency US examination of the median nerve and measurement of its cross-sectional area should be strongly considered as a new, alternative diagnostic modality for the evaluation of CTS. It offers high diagnostic accuracy, as indicated by high correlation with the present standard EMG as well as patient-oriented measures. In contrast to these two tools, US provides information about the possible causes of CTS and hence has a therapeutic impact regarding the management of the patients. Moreover, US provides a reliable method for following the response to therapy.

The authors have declared no conflicts of interest.

## References

- Buchberger W, Schon G, Strasser K, Jungwirth W. High-resolution ultrasonography of the carpal tunnel. *J Ultrasound Med* 1991;10:531–7.
- Rankin EA. Carpal tunnel syndrome issues and answers. *J Natl Med Assoc* 1995;87:169–71.
- Phalen GS. The carpal tunnel syndrome: seventeen years experience in diagnosis and treatment of six hundred fifty four hands. *J Bone Joint Surg Am* 1966;48:211–28.
- Phalen GS. The carpal tunnel syndrome: clinical evaluation of 598 hands. *Clin Orthop* 1972;8:29–40.
- Nathan PA, Keniston RC, Meadows KD. Predictive value of nerve conduction measurements at the carpal tunnel. *Muscle Nerve* 1993;16:1377–82.
- MacKinnen SE, Dellon AL. Diagnosis of nerve injury. In: MacKinnen SE, Dellon AL (eds) *Surgery of the Peripheral Nerve*. New York: Thieme, 1988:74–9.
- Wright PE. Carpal tunnel and ulnar tunnel syndromes and stenosing tenosynovitis. In: Crenshaw AIL (ed) *Campbell's Operative Orthopedics*, 8th edn. St Louis: Mosby, 1992:3435–7.
- Grundberg AB. Carpal tunnel decompression in spite of normal electromyography. *J Hand Surg Am* 1983;8:348–9.
- Redmond MD, Risner MH. False positive electrodiagnostic test in carpal tunnel syndrome. *Muscle Nerve* 1988;11:511–17.
- Gray RG, Gottlieb NL. Hand flexor tenosynovitis in rheumatoid arthritis prevalence, distribution and associated rheumatic features. *Arthritis Rheum* 1977;20:1003–8.
- Smukler NM, Patterson JR, Lorenz JJ, Weiner L. The incidence of the carpal tunnel syndrome in patients with rheumatoid arthritis. *Arthritis Rheum* 1963;6:298–9.
- Barnes GG, Curry HLF. Carpal tunnel syndrome in rheumatoid arthritis. A clinical and electrodiagnostic survey. *Ann Rheum Dis* 1967;26:226–33.
- Mesgarzadch M, Schneck CD, Bonakdarpour A. Carpal tunnel: MR imaging Part 1. Normal anatomy. *Radiology* 1980;171:743–8.
- Duncan I, Sullivan P, Lomas F. Sonography in the diagnosis of carpal tunnel syndrome. *Am J Roentgenol* 1999;173:681–4.
- Sarria L, Cabada T, Cozcolluela R, Martinez-Berganza T, Garcia S. Carpal tunnel syndrome: usefulness of sonography. *Eur Radiol* 2000;10:1920–5.
- Buchberger Q, Judmaier W, Birbamer G, Lener M, Schmidaner O. Carpal tunnel syndrome diagnosis with high-resolution sonography. *Am J Roentgenol* 1992;159:793–8.
- Kanoly LP, Schrogendorger KF, Rab M, Girsch W, Gruber N, Frey M. The precision of ultrasound imaging and its relevance for carpal tunnel syndrome. *Surg Radiol Anat* 2001;23:117–21.
- Hug C, Huber H, Terrier H. Detection of flexor tenosynovitis by magnetic resonance imaging: its relationship to diurnal variation of symptoms. *J Rheumatol* 1991;18:1055–9.
- Nakamichi K, Tachibana S. The use of ultrasonography in detection of synovitis in carpal tunnel syndrome. *J Hand Surg Br* 1993;18:176–9.
- Mesgarzadch M, Schneck CD, Bonakdarpour A, Mitra A, Conaway D. Carpal tunnel: MR imaging Part 2. Carpal tunnel syndrome. *Radiology* 1980;171:749–54.
- Brahme SK, Holder J, Braun RM, Sebrechts C, Jackson W, Resnick D. Dynamic MR imaging of carpal tunnel syndrome. *Skeletal Radiol* 1997;26:482–7.
- Swen WA, Jacobs JW, Bussemaker FE, de Waard JW, Bijlsma JW. Carpal tunnel sonography by the rheumatologist versus nerve conduction study by the neurologist. *J Rheumatol* 2001;28:62–9.
- Rempel D, Evanoff B, Amadio PC, de Krom M, Franklin G, Franzblau A. Consensus criteria for the classification of carpal tunnel syndrome in epidemiologic studies. *Am J Public Health* 1998;88:1447–51.
- AAN, AAEM, AAPMR. Practice parameter for carpal tunnel syndrome (summary statement). *Neurology* 1993;43:2406–9.
- Levine DW, Simmons PB, Koris MJ *et al.* A self-administered questionnaire for assessment of severity of symptoms and functional status in carpal tunnel syndrome. *J Bone Joint Surg Am* 1993;75A:1585–92.
- Padua L, Padua R, Lo Monaco M, Romanini E, Tonali P, for the Italian CTS study group. Italian multicentric study of carpal tunnel syndrome: study design. *Ital J Neurol Sci* 1998;19:285–9.
- Padua L, Padua R, Lo Monaco M, Aprile I, Tonali P. Multi-perspective assessment of carpal tunnel syndrome: a multicenter study. *Neurology* 1999;53:1654–9.
- AAEM, AAN, AAPMR. Practice parameter for electrodiagnostic studies in carpal tunnel syndrome: summary statement. *Muscle Nerve* 1993;16:1390–1.
- Rossi S, Giannini F, Passero S, Paradiso C, Battistini N, Cioni R. Sensory neural conduction of median nerve from digits and palm stimulation in carpal tunnel syndrome. *Electroencephalogr Clin Neurophysiol* 1994;93:330–4.
- Padua L, Lo Monaco M, Valente EM, Tonali P. A useful electrophysiologic parameter for diagnosis of carpal tunnel syndrome. *Muscle Nerve* 1996;19:48–53.
- Cioni R, Passero S S, Parasico C, Giannini F, Battistini N, Rushworth G. Diagnostic specificity of sensory and motor nerve conduction variables in early detection of carpal tunnel syndrome. *J Neurol* 1989;236:208–13.
- Uncini A, Lange DJ, Solomon M, Soliven B, Meer J, Lovelace RE. Ring finger testing in carpal tunnel syndrome: a comparative study of diagnostic utility. *Muscle Nerve* 1989;12:735–41.
- Delisa JA. Upper extremity nerves. In: Delisa JA, Lee HJ, Baron EM, Lai KS, Spielholz N (eds). *Manual of Nerve Conduction Velocity and Neurophysiology*. New York: Raven Press, 1994:68–71.
- Padua L, Lo Monaco M, Gregori B, Valente EM, Padua R, Tonali P. Neurophysiological classification and sensitivity in 500 carpal tunnel syndrome hands. *Acta Neurol Scand* 1997;96:211–17.
- Tier YG. Understanding nerve conduction and electromyographic studies. *Hand Clin* 1993;9:273–87.
- De Krom MCTFM, Knipschild PG, Kesler ADM, Spanans F. Efficacy of provocative tests for diagnosis of carpal tunnel syndrome. *Lancet* 1990;335:393–5.
- Jackson DA, Clifford JC. Electrodiagnosis of mild carpal tunnel syndrome. *Arch Phys Med Rehab* 1989;70:199–204.
- Gutmann L, Gutierrez A, Riggs JE. The contribution of median-ulnar communications in diagnosis of mild carpal tunnel syndrome. *Muscle Nerve* 1986;9:319–21.
- Dawson DM. Entrapment neuropathies of the upper extremities. *N Engl J Med* 1993;329:2013–18.
- Middleton WD, Kneeland JB, Kellman GM. MR imaging of the carpal tunnel: normal anatomy and preliminary findings in the carpal tunnel syndrome. *Am J Roentgenol* 1987;148:307–16.



41. Mesgarzadeh M, Schneck C, Bonakdarpour A, Amitabha M, Conway D. Carpal tunnel: MR imaging. *Radiology* 1989;171:749–51.
42. Chen P, Maklad N, Redwine M, Zelitt D. Dynamic high-resolution sonography of the carpal tunnel. *Am J Roentgenol* 1997;168:533–7.
43. Mesgarzadeh M, Triolo I, Schneck CD. Carpal tunnel syndrome: MR imaging diagnosis. *MRI Clin North Am* 1995;2:249–64.
44. Radack DM, Schweitzer ME, Taras J. Carpal tunnel syndrome: are the MR findings a result of population selection bias? *Am J Roentgenol* 1997;169:1649–53.
45. Wong SM, Griffith JF, Hui ACF, Tang A, Wong KS. Discriminatory sonographic criteria for the diagnosis of carpal tunnel syndrome. *Arthritis Rheum* 2002;46:1914–21.
46. Lee D, Van Holsbeeck T, Janevski P, Ganos DL, Ditmars DM, Darian VB. Diagnosis of carpal tunnel syndrome. *Radiol Clin North Am* 1999;37:859–72.
47. Dhong ES, Han SK, Lee BI, Kim WK. Correlation of electrodiagnostic findings with subjective symptoms in carpal tunnel syndrome. *Ann Plast Surg* 2000;45:127–31.
48. Porras DAF, Alaminos PR, Vinuales JI, Ruiz Villamanan MA. Value of electrodiagnostic tests in carpal tunnel syndrome. *J Hand Surg Br Eur* 2000;25B:361–5.
49. Hennessey WJ, Falco FJ, Braddom RI. Median and ulnar nerve conduction studies: normative data for young adults. *Arch Phys Med Rehab* 1994;75:259–64.
50. Werner RA, Alber JW, Franzbau A, Armstrong TJ. The relationship between body mass index and the diagnosis of carpal tunnel syndrome. *Muscle Nerve* 1994;17:1491–3.
51. Robinson LR, Rubner DE, Wahl PW, Fujimoto WY. Influence of height and gender on normal nerve conduction studies. *Arch Phys Med Rehab* 1993;74:1134–8.