

Intravenous cyclophosphamide therapy for progressive interstitial pneumonia in patients with polymyositis/dermatomyositis

Y. Yamasaki¹, H. Yamada¹, M. Yamasaki¹, M. Ohkubo¹, K. Azuma¹,
S. Matsuoka², Y. Kurihara², H. Osada³, M. Satoh⁴ and S. Ozaki¹

Objectives. To study the efficacy and safety of monthly intravenous pulse cyclophosphamide (IVCYC) therapy for progressive interstitial pneumonia in polymyositis/dermatomyositis (PM/DM).

Methods. Seventeen patients with PM/DM/amyopathic DM (mean age 51.4 ± 10.4 , mean follow-up 32 months) who received IVCYC for progressive interstitial pneumonia between August 1993 and October 2002 were studied. Nine patients had failed to respond to previous treatment with high-dose steroid and/or immunosuppressant. Cyclophosphamide ($300\text{--}800\text{ mg/m}^2$) was given at least six times every 4 weeks. Oral prednisolone ($0.5\text{--}1\text{ mg/kg/day}$) was administered for the first 2 weeks and was gradually tapered. Response to treatment was evaluated based on the degree of exertional dyspnea, pulmonary function test and high-resolution computed tomography (HRCT).

Results. Eleven of 17 patients showed improvement in their dyspnea; six out of seven patients who had required oxygen treatment before IVCYC no longer did so after IVCYC. Eight of 17 patients had $\geq 10\%$ improvement of vital capacity (VC)% and 9/17 had ≥ 10 point reduction in their HRCT score. Twelve patients had exhibited at least one result. Two patients with anti-Jo-1 antibodies showed a flare-up of interstitial pneumonia or myositis. After the IVCYC therapy, mean VC% improved by 15% (from 68 to 83%, $P = 0.0034$). The extent of abnormal lesions in HRCT was reduced from 24 to 13% ($P = 0.0055$). There was neither death nor severe toxicities observed.

Conclusions. In this open-label study, IVCYC improved symptoms, pulmonary function tests and HRCT findings in patients with PM/DM. Longitudinal controlled studies are required to further confirm the efficacy of IVCYC.

KEY WORDS: Interstitial pneumonia, Intravenous pulse, Cyclophosphamide, Polymyositis, Dermatomyositis.

Introduction

Interstitial pneumonia is a well-recognized manifestation of polymyositis (PM) and dermatomyositis (DM) found in 5–46% of patients [1]. Interstitial pneumonia is frequently associated with increased mortality and morbidity, and is listed in some studies as the most common cause of death [2, 3]. The reported mortality of PM/DM with interstitial pneumonia is as high as 50% at 5 yrs [4] or 40% at 31 months [5]. Although surprisingly little literature clearly show the effects of interstitial pneumonia on mortality and morbidity of PM/DM, one long-term analysis identified interstitial pneumonia as a factor that affects the survival curve ($P < 0.001$) [6]. The mortality of PM/DM with interstitial pneumonia in this study was 83% compared with 34% without it at 100 months. One study has suggested that the effects of interstitial pneumonia on mortality became clear only after excluding death from cancer [7], and another study indicated that DM with interstitial pneumonia had particularly poor prognosis compared with PM with interstitial pneumonia [8].

In spite of the significant effects of interstitial pneumonia on prognosis of PM/DM, optimal treatment remains to be established. High-dose corticosteroid therapy has been used as a

standard initial treatment of interstitial pneumonia, but its efficacy is limited. Nawata *et al.* [9] noted that 44% of interstitial pneumonia complicated with PM/DM was steroid-resistant. The intravenous cyclophosphamide (IVCYC) treatment has a benign therapeutic profile with less treatment-associated toxicity and has proven to be effective in various diseases, including a severe type of lupus nephritis [10]. Although IVCYC in PM/DM with interstitial pneumonia produced inconsistent results in a few case reports, a recent study by Schnabel *et al.* [11] reported that 10 cases with PM/DM with interstitial pneumonia responded to IVCYC. We here report our experiences with IVCYC treatment for the progressive interstitial pneumonia in 17 PM/DM patients in the last 10 yrs.

Patients and methods

Patients

Between August 1993 and October 2002, a total of 136 patients were diagnosed as definite PM or DM by Bohan and Peter's criteria (120 cases) [12] or amyopathic DM (ADM) as defined by Sontheimer (16 cases) [13] at St Marianna University Hospital

¹Division of Rheumatology and Allergy, Department of Internal Medicine, ²Department of Radiology, ³Division of Thoracic Surgery, Center for Respiratory Disease, St Marianna University School of Medicine, 2-16-1 Sugao, Miyamae, Kawasaki, Kanagawa 216-8511, Japan and ⁴Division of Rheumatology and Clinical Immunology, Department of Medicine, University of Florida, USA.

Received 29 September 2005; revised version accepted 28 February 2006.

Correspondence to: Yoshioki Yamasaki, Division of Rheumatology and Allergy, Department of Medicine, St Marianna University School of Medicine, 2-16-1 Sugao, Miyamae, Kawasaki, Kanagawa 216-8511, Japan. E-mail: yams@marianna-u.ac.jp

(Kawasaki, Japan). Twenty-three patients who also had systemic lupus erythematosus, scleroderma or rheumatoid arthritis were excluded from this study. Among the remaining 113 patients, 58 patients (51%) were complicated with interstitial pneumonia, based on diffuse interstitial shadow on the chest X-ray and high resolution computed tomography (HRCT). By the end of 1999, 44 patients were treated with either steroid alone (23 cases) or with immunosuppressive drugs, including methotrexate (two cases), azathioprine (three cases), cyclosporine A (CsA) (11 cases) and IVCYC (five cases) depending on the physician's decision. After the year 2000, all 14 patients who presented with interstitial pneumonia associated with PM/DM were treated with IVCYC, except for two patients with contraindications for the use of cyclophosphamide such as infection and congestive heart failure. Thus, a total of 17 patients (3PM/9DM/5ADM; mean age of 51.4 ± 10.4) received IVCYC for their interstitial pneumonia and were analysed in this study. Patients with infectious diseases such as *Pneumocystis jiroveci* (formerly *Pneumocystis carinii*) pneumonia and malignancy were excluded from this study. Excisional lung biopsy per video-assisted thoracic surgery was performed on eight patients for the histological diagnosis. Seven patients showed such severe and progressive respiratory failure that thoracic surgery under general anaesthesia was thought to be too risky to perform. The remaining two patients denied the biopsy. This study meets and is in compliance with ethical standards in medicine, and written informed consent was obtained according to the Declaration of Helsinki.

Pulmonary function test

Vital capacity (VC) was measured by the helium dilution technique. The diffusing capacity of the lung for carbon monoxide (DLCO) was measured by a single-breath method. Pulmonary function test was repeated before and after the IVCYC therapy.

HRCT and scoring

Thin-section CT (1 mm thickness) was taken at 10 mm intervals from the apex to base of the lung. HRCT findings just before and after the IVCYC treatment were assessed by two radiologists (Y.K. and S.M.) in a blinded manner. The lesion of interstitial pneumonia on HRCT was scored as previously described [14]. Briefly, three CT levels were pre-selected: mid-arch of the aorta, tracheal carina, and 1 cm above the dome of the right diaphragm. Allowance was made for differences in lung volume at each level. The weighting ratios for the three levels were 1.0, 1.20 and 1.45, respectively. The estimated percentage (to the nearest 5%) of the lung lesions at each level was multiplied by the corresponding ratio and calculated, which was designated as the CT score of the total extent of interstitial pneumonia. The CT images were reviewed and the presence of consolidation, ground-glass opacities, traction bronchiectasis, and linear opacities and honeycombing were recorded as previously defined [15].

Treatment

Cyclophosphamide was administered intravenously in 500 ml of normal saline, at an initial dose of 500–1000 mg ($300\text{--}800\text{ mg/m}^2$ body surface area adjusted based on the age) every 4 weeks with a minimum of six doses. Continuation of IVCYC after six doses was based on each physician's decision. The dose of IVCYC was adjusted to keep peripheral leucocytes above $4 \times 10^9/\text{l}$. Mesna was given intravenously to all patients to prevent haemorrhagic cystitis. Concomitant oral prednisolone was administered at a dose between 30 and 60 mg/day for the first 2 weeks and gradually tapered in all patients. All patients had been followed at our hospital and the records up to May 2004 were reviewed. Isoniazid and sulfamethoxazole-trimethoprim were administered

in all patients in this study to prevent tuberculosis and *Pneumocystis jiroveci* pneumonia, respectively, unless the patients were allergic to these drugs.

Histopathology

Lung specimen was obtained from eight patients who underwent video-assisted thoracic surgery. The histological sections were stained with haematoxylin–eosin and elastica van Gieson. Inflammatory cell infiltration (cellularity) and collagen deposition (fibrosis) were graded from minimal to marked (0–3). The following histopathological classification of interstitial pneumonia were also utilized [16]: usual interstitial pneumonia, diffuse alveolar damage, non-specific interstitial pneumonia (NSIP), organizing pneumonia, desquamative interstitial pneumonia and respiratory bronchiolitis-associated interstitial lung disease.

Analysis of serum autoantibodies

Anti-Jo-1 antibodies were tested in all patients by ELISA. Serum samples from 10 patients were available for testing of anti-aminoacyl-tRNA synthetase antibodies such as threonyl (PL-7), alanyl (PL-12), glycyl (EJ), isoleucyl (OJ) and asparagyl-tRNA synthetase (KS) by radioimmunoprecipitation. Immunoprecipitation of ^{35}S -methionine-labelled K562 (human erythroleukaemia cell) cell extracts was performed as previously described [17]. Proteins in immunoprecipitates were analysed on 8% polyacrylamide gel electrophoresis followed by autoradiography. Immunoprecipitation of the corresponding tRNAs was also confirmed by urea–PAGE and silver staining (Silver Stain Plus, Bio-Rad, Harcules) as described [17].

Statistical analysis

All statistical analyses were performed using Prism 4.0c for Macintosh (GraphPad Software, Inc., San Diego, USA). Wilcoxon rank sum test was used to assess both the HRCT score and pulmonary function test before and after the IVCYC treatment. Linear regression analysis was used to assess the association between the changes in CT score or VC% vs disease duration, period of steroid treatment prior to IVCYC, or creatine kinase (CK) before IVCYC.

Results

Patients profile and outcome

The clinical characteristics and the treatment of the 17 patients who received IVCYC are summarized in Table 1. Seven patients had severe hypoxia that required oxygenation. HRCT findings obtained before the IVCYC treatment included ground-glass opacities (15 cases, 88%), air-space consolidation (14 cases, 82%) and linear opacities (13 cases, 76%). There was no honeycombing. Lung histology in all eight patients was compatible with NSIP pattern with a varying degree of both cellular infiltration and fibrotic changes (column C/F).

All patients received IVCYC treatment for at least 6 months and favourable response was apparent within 6 months in all except for two patients (cases 4 and 7). Case 4 showed a flare-up of interstitial pneumonia 1 month after the fifth IVCYC. This patient was successfully treated with methylprednisolone (MPSL) pulse therapy and later with CsA. In case 7, IVCYC was prematurely discontinued because of a flare-up of myositis and arthritis. She was further treated with prednisolone 60 mg/day and later with CsA. Both of these patients were positive for anti-Jo-1 antibodies. Eleven of 17 patients showed no dyspnea without oxygen treatment within 6 months of the initiation of

TABLE 1. Clinical characteristics of the patients

Case	Age/sex/diagnosis	Previous treatment (months)	Disease duration ^c (months)	CK ^d at initial IVCYC (IU/l)	Auto-antibodies	AaDO ₂ (mmHg)	C/F ^f	IVCYC (mg)/(months)
1	37/M/PM	GC/CsA(15)	19	1811	Jo-1	44.2	2/1	500/13
2	43/F/DM	GC ^a /AZA(15)	15	64	(-)	26.1	nd	700/25
3	63/F/DM	GC/CsA(14)	19	390	(-) ^c	35.9	3/2	500/23
4	43/M/DM	GC(4)	5	1153	Jo-1	39.5	nd	1000/5
5	44/F/DM	GC(40)	40	53	(-)	18.9	2/2	900/32
6	47/F/PM	GC (2)	13	1824	Jo-1 ^c	16.0	2/3	700/16
7	50/F/DM	GC(21)	21	48	Jo-1	6.5	nd	500/3
8	55/M/DM	GC(11)	12	296	PL-7	25.7	nd	750/6
9	38/F/DM	none	2	947	PL-12	11.8	3/2	600/7
10	48/F/ADM	none	6	20	(-)	18.4	3/3	700/6
11	50/F/DM	none ^b	1	271	(-) ^c	43.0	nd	700/10
12	51/F/DM	none	8	919	(-) ^c	23.7	nd	700/6
13	52/M/ADM	none	10	49	PL-12	6.3	1/1	500/22
14	53/F/PM	none	10	467	(-) ^c	42.6	nd	700/7
15	59/F/ADM	none	3	166	(-) ^c	54.3	nd	750/6
16	61/F/ADM	none	3	85	(-) ^c	22.1	2/0	600/20
17	80/F/ADM	none	1	40	PL-7	42.5	nd	500/22

GC, glucocorticoid; AZA, azathioprine; CsA, cyclosporine; AaDO₂, alveolar–arterial oxygen tension gradient; mmHg, kPa/0.133; Jo-1, histidyl; PL-7, threonyl; PL-12, alanyl tRNA synthetase.
^aThis case was treated with pulse MPSL at first.
^bShe received pulse MPSL a week before the first IVCYC.
^cDisease duration was defined as months from the onset of PM/DM to the first IVCYC treatment.
^dCK, creatine kinase.
^eOnly anti-Jo-1 antibodies were tested by ELISA.
^fScore of histopathology C, cellularity; F, fibrosis.

IVCYC treatment. Six out of seven patients who had required oxygen treatment before IVCYC did not do so after IVCYC. Continuation of IVCYC after 6 months was each physician's decision on an individual case basis. In cases 8, 9, 10, 12, 14 and 15, IVCYC was discontinued because the patient achieved remission and the physician felt that the remission could be maintained without continuing IVCYC. In cases 1, 2, 3, 5, 6, 11, 13, 16 and 17, the physician decided to continue the IVCYC further because it was effective and felt that continuing it might prevent chronic progression or relapse of interstitial pneumonia. Thus, the longer treatment was not due to the lack of response in 6 months but rather because of a good response. Two patients (cases 12 and 17) had a relapse of interstitial pneumonia 3 and 12 months after the cessation of IVCYC. These two patients received another course of monthly IVCYC treatment and achieved a remission. Two patients (cases 10 and 16) who had IVCYC treatment for 6 and 20 months, respectively, have maintained a remission after 32 and 20 months after the discontinuation of IVCYC.

Percent VC and CT score before and after IVCYC are shown in Fig. 1 and Table 2. The mean VC improved by 15% (68–83%, $P=0.0034$ by Wilcoxon signed-rank test) from the baseline after a mean interval of 10 months (Fig. 1A). Eight out of the 17 patients showed more than 10% improvement of VC%. The improvement of VC% was not dependent on the baseline pulmonary function. The improvement in DLCO% was not statistically significant (from 47 to 54%, data not shown). The extent of interstitial pneumonia assessed by HRCT showed a significant improvement, from 24 to 13% ($P=0.0055$ by Wilcoxon signed-rank test), after the IVCYC treatment (Fig. 1B). Case 4 is not included in the analysis because the improvement was after the administration of CsA.

Two representative cases are shown in Figs 2 and 3. Case 2, who received IVCYC treatment for 2 yrs, showed a complete resolution of linear opacities of interstitial pneumonia and was in remission for another 8 yrs (Fig. 2). Case 11, who had progressive interstitial pneumonia despite MPSL pulse therapy, was successfully treated with IVCYC and showed dramatic improvement in chest X-ray and HRCT (Fig. 3).

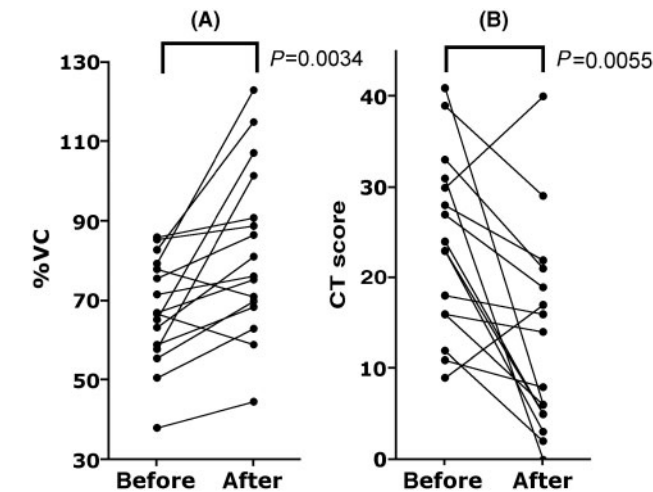


FIG. 1. Percent VC (A) and CT score (B) before and after IVCYC. The VC improved significantly ($P=0.0034$ by Wilcoxon signed-rank test) after the IVCYC therapy. The CT score improved in 14/16 patients after the IVCYC therapy ($P=0.0055$ by Wilcoxon signed-rank test).

Factors that can affect the response to IVCYC

The improvement of VC% had negative correlation with the disease duration of PM/DM prior to IVCYC treatment (Fig. 4A, $R^2=0.2806$, $P=0.0348$ by linear regression) and with the time between initial steroid treatment and IVCYC (Fig. 4B, $R^2=0.3082$, $P=0.0256$ by linear regression). The changes of CT score did not have any significant correlation with disease duration or the time between initial steroid treatment and IVCYC. The CK levels before IVCYC had no statistically significant correlation with the changes of VC% or CT score. The improvement of VC% was also significantly higher in patients who received IVCYC without previous treatment ($n=9$) than in patients who had

TABLE 2. Response of interstitial pneumonia to cyclophosphamide therapy

Case	O ₂ requirement before/after	VC% before/after	CT score before/after	Outcome dyspnea
1	yes/no	63.4/81.2	30/40	yes
2	no/no	67.0/75.5	24/5	no
3	yes/no	75.8/86.6	9/17	yes
4	yes/yes ^a	60.5/81.0 ^a	30/5 ^a	yes ^a
5	no/no	78.0/71.2	27/19	no
6	no/no	38.1/44.6	16/14	yes
7	no/no	66.9/58.9	33/21	no
8	no/no	86.0/90.8	23/3	no
9	no/no	59.0/68.4	28/22	yes
10	no/no	65.2/107.1	16/6	no
11	yes/no	50.7/63.0	41/6	no
12	no/no	55.5/69.9	18/16	no
13	no/no	85.3/88.8	12/2	no
14	yes/no	79.4/122.9	31/0	no
15	yes/no	82.8/115.0	39/29	yes
16	no/no	71.6/76.3	11/8	no
17	yes/no	57.9/101.5	23/5	no

^aThis patient improved after CsA treatment.

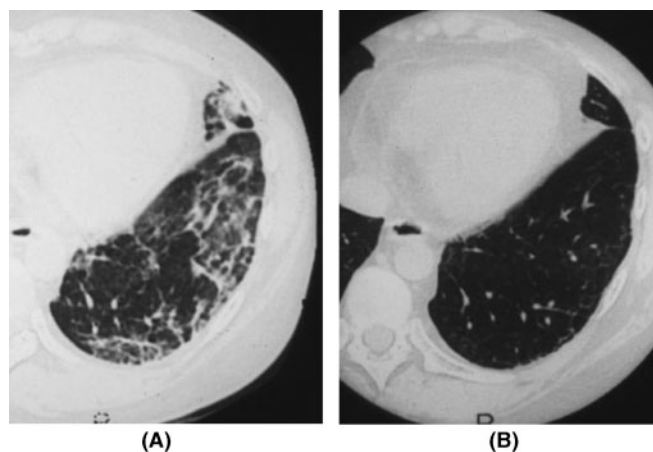


FIG. 2. HRCT before and after the IVCYC therapy. HRCT of the case 2 before (A) and 2 yrs after the IVCYC therapy (B) is shown. Note the disappearance of linear opacity seen in (A) in HRCT 2 yrs later (B).

previous treatment ($n=7$) ($22 \pm 17\%$ vs $5 \pm 9\%$, $P=0.04$ by Mann–Whitney, one-tailed). Six out of eight patients who had $\geq 10\%$ improvement in VC had not received previous treatment.

Adverse reactions

Adverse reactions observed during the course of the IVCYC treatment included opportunistic infection with *Mycobacterium avium* (case 3) and herpes zoster infection (case 9). IVCYC was discontinued in case 1 after 13 months of treatment because of azospermia. Neither malignancy nor haemorrhagic cystitis was observed. All patients were still under follow-up at our institute as of May 2004.

Discussion

The present study suggests that IVCYC is a promising treatment for interstitial pneumonia in PM/DM based on improved clinical

symptoms, pulmonary function tests and HRCT findings, even in the patients with severe fibrosis in histology. There was no death nor respiratory failure observed during the mean follow-up period of 32 months. No life-threatening complications such as sepsis, haemorrhagic cystitis or malignancy developed. Mild and reversible leucopaenia was observed in all patients; however, no discontinuation of IVCYC was necessary.

The efficacy of IVCYC in idiopathic interstitial pneumonia is incompletely documented, rendering it unclear whether the clinical benefit outweighs the risks [18–20]. Nevertheless, an advantage of a combination of oral cyclophosphamide plus prednisolone over prednisolone alone was reported [18]. IVCYC also appears beneficial in certain patients in open-labelled studies [21, 22]. Reports of monthly IVCYC for interstitial pneumonia in systemic sclerosis were published with a favourable outcome [23]. Oral cyclophosphamide, azathioprine and methotrexate have been used conventionally for interstitial pneumonia in PM/DM [24]. Published experience of IVCYC in the treatment of PM/DM was limited [25, 26], however, Schnabel *et al.* [11] reported more recently that a combination of IVCYC and prednisolone prevented further progression of interstitial pneumonia in all 10 cases with PM/DM and led to normalization of pulmonary function in some patients. The present study further confirmed this observation, showing that IVCYC could lead to favourable long-term outcome in patients with PM/DM-associated interstitial pneumonia.

In addition to the studies using IVCYC, several recent studies reported encouraging data on CsA for interstitial pneumonia complicated in PM/DM [9, 27, 28]. CsA was effective in 4/5 cases of juvenile DM with interstitial pneumonia [27]. The other study [28] suggested that a combination of CsA and steroid was likely to be beneficial in 4/10 cases that were refractory to the conventional therapy and that the dosage of steroid was tapered in 3/4 CsA-responsive cases without exacerbation. Nawata *et al.* [9] reported that CsA was effective in all 5 cases of corticosteroid-resistant interstitial pneumonia in PM/DM and improved survival. It has been suggested that CsA was an effective treatment for interstitial pneumonia in PM/DM when used early in the course of the disease [9, 29]. A recent study reported that a combination therapy with corticosteroid, CsA and IVCYC was effective in acute/subacute interstitial pneumonia in DM [30]. Five of 10 patients in the study survived and were doing well for more than 2 yrs. Another new drug that seems promising is tacrolimus [31–33]. Wilkes *et al.* [31] reported a study on 15 cases of anti-aminoacyl-tRNA synthetase antibody-positive interstitial pneumonia associated with PM/DM. A significant improvement in all pulmonary parameters and the serum CK levels as well as muscle strength along with steroid sparing effects was observed. Tacrolimus is well tolerated and an effective therapy for refractory interstitial pneumonia in this subset of patients. The other study [33] reported efficacy of tacrolimus in two cases that were refractory to conventional therapy with high-dose corticosteroid, CsA and IVCYC. While the aforementioned new immunosuppressive therapy seems encouraging, it is hard to argue which one is superior to others since all of these studies are open trial performed in various countries with relatively small number of patients of different subset of interstitial pneumonia with PM/DM.

The possibility that our patients' selection was biased and that our selection of 17 patients was skewed towards patients with a favourable prognosis could be argued. However, there are several reasons that most of our patients had a potential risk to develop a fatal course of respiratory failure. First, 12 out of 17 patients were not selected, because all new patients seen after 2000 were treated with IVCYC. Second, all eight patients who underwent lung biopsy showed NSIP pattern. Two recent studies showed that NSIP was the most common histological pattern of interstitial pneumonia in patients with PM/DM and that their 5-yr survival was 50–60% [4, 24]. Third, seven patients showed severe hypoxia that initially required oxygenation. Finally, 15 patients showed

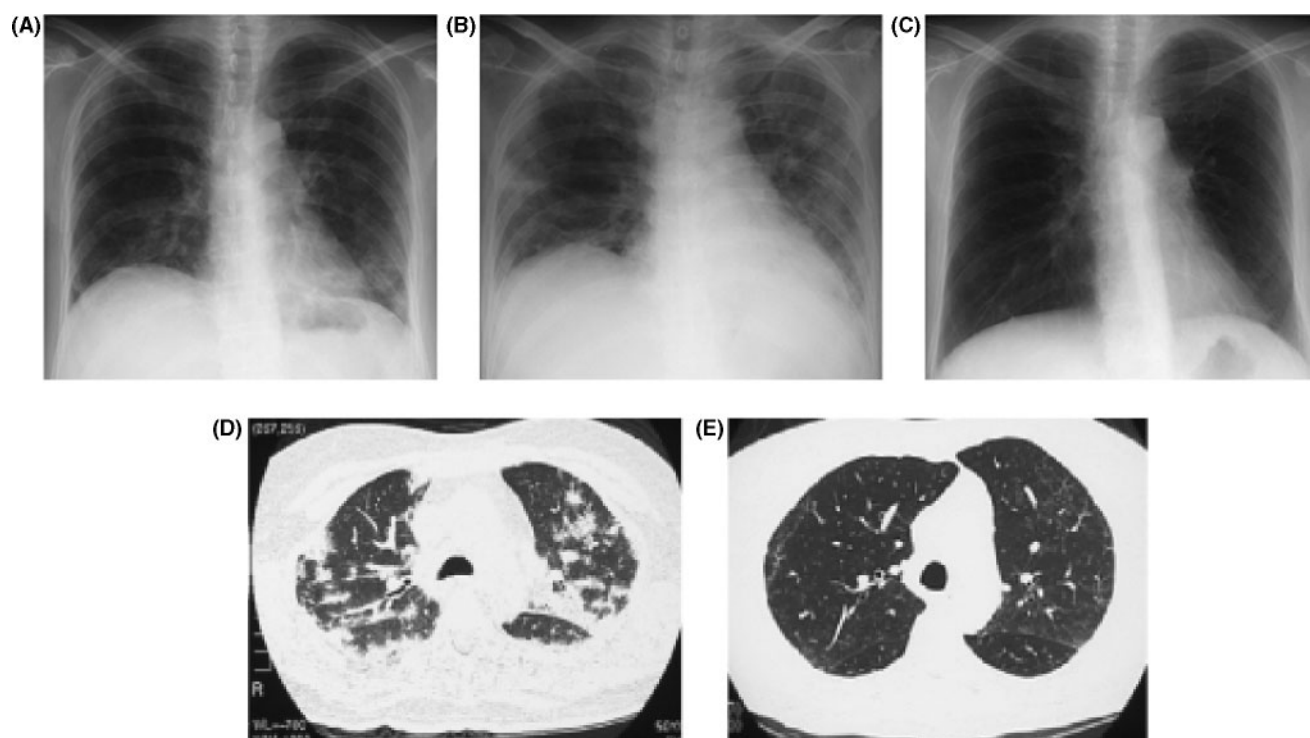


FIG. 3. Chest X-ray and HRCT in a case of a 50-yr-old woman (case 11). Chest X-ray films before MPSL pulse therapy (A) and 2 weeks after MPSL therapy (B) showing progressive interstitial pneumonia. HRCT before cyclophosphamide is shown in (D). Dramatic improvement was seen 11 months after IVCYC by chest X-ray (C) and HRCT (E).

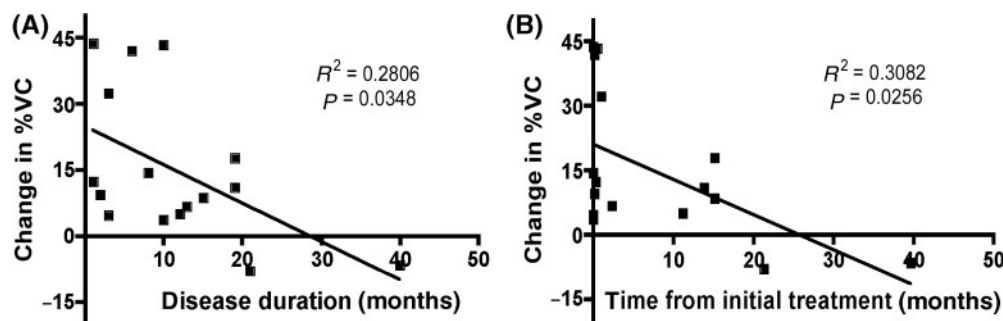


FIG. 4. Factors that affect on %VC improvement after IVCYC therapy. (A) Duration of the disease prior to IVCYC and changes in VC% after the IVCYC therapy. A negative correlation was found between the duration of the disease prior to IVCYC and the changes in %VC after IVCYC ($R^2 = 0.2806$, $P = 0.0348$ by linear regression). (B) Time between the initial steroid treatment and IVCYC therapy and changes in %VC after IVCYC. A negative correlation was found between time of the initial steroid treatment and IVCYC therapy vs changes in %VC after IVCYC ($R^2 = 0.3082$, $P = 0.0256$ by linear regression).

ground-glass opacities on HRCT which indicated a rapidly progressive diffuse alveolitis [11, 34, 35]. This form of pulmonary involvement often becomes fatal in weeks to months and may deteriorate into respiratory failure [36]. Furthermore, traction bronchiectasis that suggested parenchymal distortion often seen in diffuse alveolar damage [37] was detected in three quarters of our patients (data not shown). All these data strongly suggest that our patients were not biased for cases with favourable prognosis.

Incomplete resolution of pulmonary infiltrates with residual bibasilar opacities is commonly observed in the chronic phase of interstitial pneumonia [24]. Sequential evaluation of interstitial pneumonia with HRCT indicated that abnormal patterns such as linear opacities and subpleural line persisted and slowly progressed over years. In the present case series, case 2, who received IVCYC

for more than 2 yrs, showed complete resolution of the linear opacities on HRCT. The treatment with IVCYC was also effective in the two patients (cases 6 and 10) whose lung histology showed a remarkable fibrosis. These findings suggest that IVCYC can prevent chronic progression of lung fibrosis that is usually resistant to corticosteroid therapy. Nevertheless, a remarkable improvement in pulmonary function was seen mainly in patients treated with IVCYC without previous treatment in this study.

It is possible that treatment at an early stage of the disease process in many patients was a contributing factor for the favourable results in the present study, as suggested in previous studies [9, 29]. In fact, a negative correlation between the disease duration or the time before IVCYC and improvement of VC% or CT score was found in the present study (Fig. 4).

The favourable result in our patients treated with IVCYC may also partially be attributed to the strict strategy for preventing opportunistic infections using isoniazide and sulfamethoxazole-trimethoprim. Tuberculosis has been prevalent in Japan with an incidence rate of 31 cases per 100 000 per year [38]. *Pneumocystis jiroveci* pneumonia has also been one of the major problems in patients treated with immunosuppressive drugs such as cyclophosphamide [39]. A large study showed that the in-hospital mortality of *Pneumocystis jiroveci* pneumonia complicated in patients with connective tissue disease was 45.7% [40]. In addition, it is quite difficult for clinicians to distinguish the exacerbation of non-infectious interstitial pneumonia from diffuse lung infiltration by the opportunistic infection [41]. Our experience supports the idea that the prevention of opportunistic infection may be critical in these patients [42].

Optimal duration of IVCYC is debatable. In the present study, continuation of IVCYC after 6 months was each physician's decision on individual case. In some cases, long-term remission of interstitial pneumonia after discontinuation of IVCYC was achieved, while IVCYC was restarted in two cases for relapsed interstitial pneumonia. Among the cases in which IVCYC was continued, several patients showed further improvement (data not shown), suggesting that the continuation may be beneficial in some cases. How long IVCYC should be continued and whether continuing IVCYC can prevent chronic progression or relapse of interstitial pneumonia are important clinical questions that should be evaluated in the future long-term studies. Whether switching to other immunosuppressants such as cyclosporin and tacrolimus after achieving remission with IVCYC is beneficial may also need to be evaluated.

In conclusion, the present open-label study suggests that IVCYC is an effective and safe treatment for PM/DM-associated interstitial pneumonia. Randomized controlled studies are necessary to obtain further evidence that IVCYC can significantly improve the clinical outcome of interstitial pneumonia associated with PM/DM.

Rheumatology	Key messages
	<ul style="list-style-type: none"> • IVCYC appears to be a safe and effective treatment of interstitial pneumonia in PM/DM. • IVCYC at early stage of the disease may be more effective.

Acknowledgements

We would like to appreciate the clinical staff in the Division of Rheumatology and the Division of Thoracic Surgery, St Marianna University Hospital for their patients' care and Dr Shigeki Saiki at the St Luke International Hospital for critical review of lung histopathology. We also thank Prof. Dimitrios T Boumpas for the critical review of the manuscript, Ms. Gina D Tonogbanua for editorial assistance and Dr Sonali Narain for assistance in statistical analysis.

The authors have declared no conflicts of interest.

References

- Fathi M, Dastmalchi M, Rasmussen E, Lundberg IE, Tornling G. Interstitial lung disease, a common manifestation of newly diagnosed polymyositis and dermatomyositis. *Ann Rheum Dis* 2004;63:297–301.
- Takizawa H, Shiga J, Moroi Y, Miyachi S, Nishiwaki M, Miyamoto T. Interstitial lung disease in dermatomyositis: clinicopathological study. *J Rheumatol* 1987;14:102–7.
- Hidano A, Torikai S, Uemura T, Shimizu S. Malignancy and interstitial pneumonitis as fatal complications in dermatomyositis. *J Dermatol* 1992;19:153–60.
- Cottin V, Thivolet-Bejui F, Reynaud-Gaubert M *et al.* Interstitial lung disease in amyopathic dermatomyositis, dermatomyositis and polymyositis. *Eur Respir J* 2003;22:245–50.
- Arsura EL, Greenberg AS. Adverse impact of interstitial pulmonary fibrosis on prognosis in polymyositis and dermatomyositis. *Semin Arthritis Rheum* 1988;18:29–37.
- Maugars YM, Berthelot JM, Abbas AA, Mussini JM, Nguyen JM, Prost AM. Long-term prognosis of 69 patients with dermatomyositis or polymyositis. *Clin Exp Rheumatol* 1996;14:263–74.
- Danko K, Ponyi A, Constantin T, Borgulya G, Szegedi G. Long-term survival of patients with idiopathic inflammatory myopathies according to clinical features: a longitudinal study of 162 cases. *Medicine* 2004;83:35–42.
- Fujisawa T, Suda T, Nakamura Y *et al.* Differences in clinical features and prognosis of interstitial lung diseases between polymyositis and dermatomyositis. *J Rheumatol* 2005;32:58–64.
- Nawata Y, Kurasawa K, Takabayashi K *et al.* Corticosteroid resistant interstitial pneumonitis in dermatomyositis/polymyositis: prediction and treatment with cyclosporine. *J Rheumatol* 1999;26:1527–33.
- Austin HA 3rd, Klippel JH, Balow JE *et al.* Therapy of lupus nephritis. Controlled trial of prednisone and cytotoxic drugs. *N Engl J Med* 1986;314:614–9.
- Schnabel A, Reuter M, Biederer J, Richter C, Gross WL. Interstitial lung disease in polymyositis and dermatomyositis: clinical course and response to treatment. *Semin Arthritis Rheum* 2003;32:273–84.
- Bohan A, Peter JB. Polymyositis and dermatomyositis (first of two parts). *N Engl J Med* 1975;292:344–7.
- Sontheimer RD. Cutaneous features of classic dermatomyositis and amyopathic dermatomyositis. *Curr Opin Rheumatol* 1999;11:475–82.
- Arakawa H, Kurihara Y, Nakajima Y. Pulmonary fat embolism syndrome: CT findings in six patients. *J Comput Assist Tomogr* 2000;24:24–9.
- Arakawa H, Yamada H, Kurihara Y *et al.* Nonspecific interstitial pneumonia associated with polymyositis and dermatomyositis: serial high-resolution CT findings and functional correlation. *Chest* 2003;123:1096–103.
- American Thoracic Society. Idiopathic pulmonary fibrosis: diagnosis and treatment. International consensus statement. American Thoracic Society (ATS), and the European Respiratory Society (ERS). *Am J Respir Crit Care Med* 2000;161:646–64.
- Reeves WH, Satoh M, McCauliffe DP. Autoantibody testing by non-FITC methods. In: Rose NR, Hamilton RG, Detrick B, eds. *Manual of clinical laboratory immunology*. Washington, DC: American Society of Microbiology Press, 2001:933–50.
- Johnson MA, Kwan S, Snell NJ, Nunn AJ, Darbyshire JH, Turner-Warwick M. Randomised controlled trial comparing prednisolone alone with cyclophosphamide and low dose prednisolone in combination in cryptogenic fibrosing alveolitis. *Thorax* 1989;44:280–8.
- O'Donnell K, Keogh B, Cantin A, Crystal RG. Pharmacologic suppression of the neutrophil component of the alveolitis in idiopathic pulmonary fibrosis. *Am Rev Respir Dis* 1987;136:288–92.
- Dayton CS, Schwartz DA, Helmers RA *et al.* Outcome of subjects with idiopathic pulmonary fibrosis who fail corticosteroid therapy. Implications for further studies. *Chest* 1993;103:69–3.
- Baughman RP, Lower EE. Use of intermittent, intravenous cyclophosphamide for idiopathic pulmonary fibrosis. *Chest* 1992;102:1090–4.
- Kolb M, Kirschner J, Riedel W, Wirtz H, Schmidt M. Cyclophosphamide pulse therapy in idiopathic pulmonary fibrosis. *Eur Respir J* 1998;12:1409–14.

23. Steen VD, Lanz JK Jr, Conte C, Owens GR, Medsger TA Jr. Therapy for severe interstitial lung disease in systemic sclerosis. A retrospective study. *Arthritis Rheum* 1994;37:1290–6.
24. Douglas WW, Tazelaar HD, Hartman TE *et al.* Polymyositis-dermatomyositis-associated interstitial lung disease. *Am J Respir Crit Care Med* 2001;164:1182–5.
25. Maccioni FJ, Colebatch HJ. Management of fibrosing alveolitis with polymyositis dermatomyositis. *Aust N Z J Med* 1990;20:806–10.
26. al-Janadi M, Smith CD, Karsh J. Cyclophosphamide treatment of interstitial pulmonary fibrosis in polymyositis/dermatomyositis. *J Rheumatol* 1989;16:1592–6.
27. Kobayashi I, Yamada M, Takahashi Y *et al.* Interstitial lung disease associated with juvenile dermatomyositis: clinical features and efficacy of cyclosporin A. *Rheumatology* 2003;42:371–4.
28. Miyake S, Ohtani Y, Sawada M *et al.* Usefulness of cyclosporine A on rapidly progressive interstitial pneumonia in dermatomyositis. *Sarcoidosis Vasc Diffuse Lung Dis* 2002;19:128–33.
29. Maeda K, Kimura R, Komuta K, Igarashi T. Cyclosporine treatment for polymyositis/dermatomyositis: is it possible to rescue the deteriorating cases with interstitial pneumonitis? *Scand J Rheumatol* 1997;26:24–9.
30. Kameda H, Nagasawa H, Ogawa H *et al.* Combination therapy with corticosteroids, cyclosporin A, and intravenous pulse cyclophosphamide for acute/subacute interstitial pneumonia in patients with dermatomyositis. *J Rheumatol* 2005;32:1719–26.
31. Wilkes MR, Sereika SM, Fertig N, Lucas MR, Oddis CV. Treatment of antisynthetase-associated interstitial lung disease with tacrolimus. *Arthritis Rheum* 2005;52:2439–46.
32. Oddis CV, Sciurba FC, Elmagd KA, Starzl TE. Tacrolimus in refractory polymyositis with interstitial lung disease. *Lancet* 1999;353:1762–3.
33. Ochi S, Nanki T, Takada K *et al.* Favorable outcomes with tacrolimus in two patients with refractory interstitial lung disease associated with polymyositis/dermatomyositis. *Clin Exp Rheumatol* 2005;23:707–10.
34. Mino M, Noma S, Taguchi Y, Tomii K, Kohri Y, Oida K. Pulmonary involvement in polymyositis and dermatomyositis: sequential evaluation with CT. *Am J Roentgenol* 1997;169:83–7.
35. Schnabel A, Reuter M, Gross WL. Intravenous pulse cyclophosphamide in the treatment of interstitial lung disease due to collagen vascular diseases. *Arthritis Rheum* 1998;41:1215–20.
36. Oddis CV. Current approach to the treatment of polymyositis and dermatomyositis. *Curr Opin Rheumatol* 2000;12:492–7.
37. Mihara N, Johkoh T, Ichikado K *et al.* Can acute interstitial pneumonia be differentiated from bronchiolitis obliterans organizing pneumonia by high-resolution CT? *Radiat Med* 2000;18:299–304.
38. Raviglione MC, Pio A. Evolution of WHO policies for tuberculosis control, 1948–2001. *Lancet* 2002;359:775–80.
39. Godeau B, Coutant-Perronne V, Le Thi Huong D *et al.* *Pneumocystis carinii* pneumonia in the course of connective tissue disease: report of 34 cases. *J Rheumatol* 1994;21:246–51.
40. Ward MM, Donald F. *Pneumocystis carinii* pneumonia in patients with connective tissue diseases: the role of hospital experience in diagnosis and mortality. *Arthritis Rheum* 1999;42:780–9.
41. Rossi SE, Erasmus JJ, Volpacchio M, Franquet T, Castiglioni T, McAdams HP. “Crazy-paving” pattern at thin-section CT of the lungs: radiologic-pathologic overview. *Radiographics* 2003;23:1509–19.
42. Marie I, Hachulla E, Cherin P *et al.* Opportunistic infections in polymyositis and dermatomyositis. *Arthritis Rheum* 2005;53:155–65.