Rheumatology 2007;46:1450–1453
Advance Access publication 10 July 2007
doi:10.1093/rheumatology/kem166

Concise Report

Radiographic progression in patients with ankylosing spondylitis after 4 yrs of treatment with the anti-TNF-α antibody infliximab

X. Baraliakos, J. Listing[1], J. Brandt, H. Haibel[2], M. Rudwaleit[2], J. Sieper[2] and J. Braun

Objectives. Anti-tumour necrosis factor therapy with infliximab has been shown to improve signs and symptoms of patients with active ankylosing spondylitis (AS). The objective of this article was to study the effect of infliximab on structural changes in AS over 4 yrs.
Methods. Conventional radiographs of the cervical and the lumbar spine of 33 AS patients at baseline (BL), after 2 (FU1) and after 4 yrs (FU2) of infliximab therapy were scored by the modified Stokes ankylosing spondylitis spinal score (mSASSS). Definite baseline damage was defined when at least one syndesmophyte (mSASSS $\geq$2) was seen. Definite radiographic progression was defined as a change from 0 or 1 to syndesmophytes or ankylosis (mSASSS $\geq$2).
Results. The mean change over 4 yrs was 1.6 ± 2.6 mSASSS units ($P = 0.001$), (0.9 ± 2.3 for BL–FU1 *vs* 0.7 ± 1.6 for FU1–FU2). This is less radiographic progression in comparison with published data from the OASIS cohort (4.4 within 4 yrs). Definite radiographic progression was found in 10/33 (30.3%) patients for BL–FU2. Patients with definite damage at BL developed more chronic changes at FU2 (2.3 ± 3.1, $P = 0.003$) than those with no damage at BL (0.7 ± 1.5, $P = 0.08$). Four out of seven patients with no damage at BL showed radiographic deterioration after 4 yrs. The change of the mean mSASSS in comparison with BL was significantly different after 2 ($P = 0.007$) but not after 4 yrs of infliximab therapy.
Conclusions. There is some radiographic progression after 2 and 4 yrs of infliximab therapy in AS patients. A comparison with the historical OASIS cohort suggests that infliximab may decelerate progression of structural changes. Larger studies are needed to confirm this finding.

KEY WORDS: Ankylosing spondylitis, Infliximab, X-rays, Chronic spinal changes, mSASSS.

Introduction

Ankylosing spondylitis (AS), the most frequent inflammatory rheumatic disorder that affects the axial skeleton, affects young male and female patients usually starting in the third decade of life. The leading clinical symptom is inflammatory back pain [1]. Structural changes in the axial skeleton are pathognomonic for AS: the features of new bone formation such as syndesmophytes and ankylosis are visualized by radiography. Imaging of active and structural changes is important for diagnosis, classification and monitoring of AS patients.

Therapy of active AS patients with the anti-TNF agent infliximab has shown clinical efficacy in randomized controlled trials (RCTs) [2, 3]. In accordance, improvement of active spinal lesions after therapy with infliximab has been demonstrated by MRI [4].

The modified Stokes ankylosing spondylitis spinal score (mSASSS, [5]) has been identified as the most sensitive and valid scoring method [6] for the evaluation of chronic spinal changes as assessed by conventional spinal radiographs in AS. In addition, the presence of radiographic damage at presentation has been reported to be the most sensitive predictive factor for future radiographic progression.

Recently we reported on the development of structural spinal changes in AS patients after 2 yrs of continuous treatment with infliximab. Patients who had participated in the first RCT of infliximab in AS performed in Germany [2, 7], showed less radiographic progression in comparison with patients followed up in historical cohorts who had been treated conventionally over the same time period. Similarly, definite radiographic progression was found to be best assessed by calculation of the proportion of patients with progression from no changes or simple structural changes (mSASSS '0' or '1') to syndesmophytes or ankylosis (mSASSS '2' or '3', respectively) [8].

In the present publication, we present the first long-term follow-up results of the radiographic progression in AS patients after 4 yrs of infliximab therapy.

Methods

Patients and study protocol

All 33 patients included in this study had participated in the original RCT on the clinical efficacy of infliximab in patients with active AS recently published [2, 3, 7]. Briefly, all AS patients were treated with 5 mg/kg infliximab i.v. continuously every 6 weeks for 3 yrs, showing rapid and persistent improvement of disease signs and symptoms over the entire study period. According to the clinical study protocol, all patients withdrew treatment after 3 yrs of continuous infliximab therapy and were re-infused with infliximab in the same dosage in case of a clinical relapse [9]. The median time to relapse had been relatively short: 14.6 weeks. According to the study protocol all patients gave informed consent and agreed to take part in this radiographic substudy of the clinical study [2]. The clinical study including the substudy was approved by the local Ethics Committees of each participating centre.

The main inclusion criterion for the evaluation of the radiographics was participation in the trial during the entire study period of 4 yrs. Another prerequisite for inclusion was the availability of complete sets of radiographs [both the cervical (CS) and the lumbar (LS) spine] at all time points: at the start of the clinical study (BL) and after 2 (FU1) and 4 yrs of the clinical study (FU2). Finally, the complete CS and LS had to be captured on the film (see subsequently).

Rheumazentrum Ruhrgebiet, Herne, Ruhr-University Bochum, [1]Rheumatology, Charité, Campus Benjamin Franklin and [2]German Rheumatism Research Center, Berlin, Germany.

Submitted 10 January 2007; revised version accepted 14 May 2007.

Correspondence to: Prof. Dr J. Braun, Rheumazentrum Ruhrgebiet, Landgrafenstr.15, 44652 Herne, Germany.
E-mail: j.braun@rheumazentrum-ruhrgebiet.de

TABLE 1. Baseline characteristics of the patients included in the present study in comparison with the patients included in the evaluation of the radiographic progression of the OASIS cohort [3]

		Infliximab study	OASIS cohort [3]
Age (yrs)	Mean	43.8 ± 7.6	44.6 ± 11.7
	Median	44.0	44.0
	Range	26–58	20–78
Time since diagnosis (yrs)	Mean	19.0 ± 23.4	11.7 ± 9.3
	Median	12.0	10.0
	Range	5.0–31.0	0.2–42.0
Duration of symptoms	Mean	19.4 ± 9.3	21.0 ± 11.6
	Median	19.0	18.2
	Range	6.0–39.0	0.4–51.0
mSASSS score	Mean	11.6 ± 15.3	12.7 ± 17.4
	Median	7.0	5.0
	Range	0.0–72.0	0.0–72.0
BASDAI score	Mean	6.6 ± 1.4	3.4 ± 2.1
	Median	6.4	2.3
	Range	4.1–9.0	0.0–8.5
BASFI score	Mean	3.5 ± 1.9	3.3–2.5
	Median	3.0	2.3
	Range	1.0 ± 7.0	0.0 - 9.7

With the exception of the baseline BASDAI score, all other baseline characteristics were similar for both cohorts. The difference in BASDAI values depends on the high BASDAI score of ≥4 as inclusion criterion in the infliximab study, in contrast to the OASIS cohort that did not have such inclusion criterion.

Radiographic assessment of structural spinal changes by using the mSASSS

All images were blinded by an independent person before they were scored by one experienced reader (X.B.) using the mSASSS [5]. The mSASSS has been described extensively elsewhere [10, 11]. Briefly, it evaluates the anterior vertebral edges of the CS and the LS by grading the presence of chronic changes using a score between 0 and 3 [12]. The total range of the score is 0–72 scoring points. Since not all radiographs are qualitatively equal (e.g. over- or underexposure of the radiograph) and not all spinal segments are always completely captured on the film, some sites may be missing for evaluation. Patients who had more than three vertebral sites missing were excluded, as previously reported [12, 13]. In cases with ≤3 vertebral edges missing, these scores were substituted by the mean score of the vertebra of the same spinal segment.

With respect to the definition of mSASSS, damage at BL was defined as a score of ≥1 (sclerosis or erosion), and *definite* radiographic damage was defined as a score of ≥2 (appearance of at least one syndesmophyte) in at least one vertebral edge, in accordance to a recent proposal [8].

Comparison of the radiographic progression was performed by evaluating the change of the mSASSS between time points. Any radiographic change was defined as worsening or improvement of ≥1 mSASSS units, and *definite* radiographic change as the change from mSASSS scorings of '0' (no damage) or '1' (sclerosis, squaring or erosion) to '2' (syndesmophyte') or '3' (bridging syndesmophyte/ankylosis) between time points.

Statistical analysis

The correlations at different time points were calculated by Pearson's correlation coefficient. Non-parametric tests were applied to identify radiographic progression. For comparisons between time points, the Wilcoxon test was used and for comparisons within patient subgroups, the McNemmar test.

Results

Patient's characteristics at baseline

Altogether, there were 33 patients with AS with a complete set of X-rays of both time points. The baseline characteristics of the patients included in the study are shown in Table 1. The baseline characteristics of the patients of the OASIS cohort [12] shown for comparison are similar—with the exception of the Bath AS disease activity index (BASDAI, [14]) (Table 1).

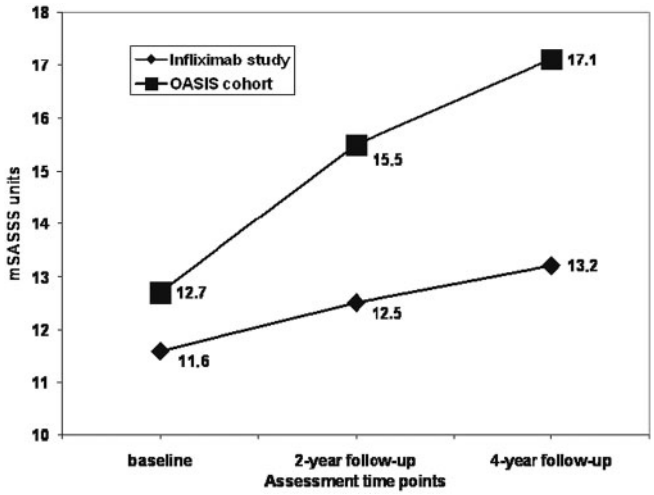

FIG. 1. Course of radiographic deterioration in all patients included in this study under infliximab therapy ('infliximab study') as compared with patients treated conventionally in the OASIS cohort.

Descriptive analysis of the radiographic evaluation

In the analysis of the entire patient population, the mean mSASSS was 11.6 ± 15.3 at BL, 12.5 ± 16.7 at FU1 ($P = 0.005$ as compared with BL) and 13.2 ± 16.7 at FU2 ($P = 0.001$ as compared with BL, $P = 0.02$ as compared to FU1) (Fig. 1).

Radiographic damage was detected in 26/33 patients (78.8%) at BL and in 30/33 patients at FU2 (90.1%). This means that 4/7 patients (57.1%) with no radiographic damage at BL showed signs of new chronic spinal lesions after 4 yrs. Of those four patients, only one patient showed definite radiographic deterioration, while the other three patients developed only minor changes.

Any radiographic progression was seen in 10/33 patients (30.3%) between BL and FU1, and in 9/33 patients (27.3%) between FU1 and FU2 (P = NS). Overall, 17/33 patients (51.5%) showed radiographic progression at FU2 in comparison with BL.

Definite radiographic progression, was found in only 7/33 patients (21.2%) between BL and FU1, in 5/33 (15.2%) between FU1 and FU and in 10/33 (30.3%) patients between BL and FU2. This is less than the proportion of patients with any radiographic progression.

Radiographic progression in relation to the degree of baseline damage

Patients with radiographic damage at BL showed significant worsening of chronic spinal changes after 4 yrs (2.3 ± 3.1, $P = 0.003$ as compared with BL), in contrast to patients with no definite radiographic damage at BL (mSASSS progression 0.7 ± 1.5, $P = 0.08$). Similarly, intermittent mSASSS change (change between BL and FU1) was only significant for patients with definite damage at BL (mSASSS change 1.7 ± 2.9, $P = 0.005$) but not for patients without BL damage (mSASSS change = 0).

The radiographic progression between FU1 and FU2 (0.6 ± 1.8 and 0.7 ± 1.5 for patients with and without BL damage, respectively) was not significant for either group.

Furthermore, the between-group comparison of the mean mSASSS change as compared with BL showed statistically significant differences after the first 2 yrs ($P = 0.007$) but not after 4 yrs of infliximab treatment ($P > 0.05$).

Finally, 7/18 patients (38.9%) with definite damage at BL but no patient with no definite BL damage showed definite deterioration between BL and FU1. At FU2, there was one additional patient (overall 8/18 patients, 44.4%) from the group with definite baseline damage but still no patient from the group with no baseline damage showing radiographic definite radiographic change.

Discussion

The present study suggests that treatment with the anti-TNF-α antibody infliximab does not completely inhibit, but may decelerate radiographic progression in patients with AS over 4 yrs. Recently, we reported that AS patients may benefit from anti-TNF therapy clinically [7] and also regarding structural damage [13] after 2 yrs in comparison with data from historical cohorts [13]. Here we extend this experience by reporting the radiographic scores after 4 yrs.

It seems clear now that, in contrast to RA [15], there is some radiographic progression in patients with AS over 2 and 4 yrs of anti-TNF therapy. This may be due to the rather different nature of structural changes in AS, as compared with RA where we are dealing with osteodestructive changes rather than new bone formation. TNF-α has been shown to play a key role in skeletal disease because it promotes reduced bone formation by mature osteoblasts and increased osteoclastic resorption [16–18]. Patients with prevalent definite radiographic damage at BL had more radiographic progression than patients with no damage at BL, but this was only significant after 2, but not after 4 yrs. Importantly, there was no significant radiographic progression in the group without baseline radiographic damage after 4 yrs. This suggests that there was no new bone formation in this patient group in the present study. However, it is unclear whether this is due to anti-TNF therapy or rather represents the natural course of disease since it is well established that many AS patients do not progress—at least as assessed by the mSASSS [19].

Since the mean mSASSS change in the between-group comparison was only significant between BL and yr 2 but not between yrs 2 and 4 of the study, the study design deserves special attention because the protocol had been to discontinue infliximab after 3 yrs of continuous therapy and restart only after clinical relapse [9].

Furthermore, we have reported that spinal inflammation was not completely suppressed after 2 yrs of anti-TNF therapy [20]. The small amount of inflammation still present after 2 yrs of anti-TNF therapy may be independent of TNF-α and may be responsible for the incomplete inhibition of new bone formation. This is similar to recent results from animal models, where evidence for partial uncoupling of inflammation and new bone formation was found [21].

Second, the comparison to the historical OASIS cohort [12] suggests that the mean scores of radiographic change are less pronounced in the infliximab-treated patients (mSASSS change 1.6 ± 2.6 after 4 yrs) as compared with the patients of the OASIS cohort (mSASSS change 4.4). However, these were consecutive patients not included on the basis of high disease activity as it was the case in our patients. Thus, these conventionally treated patients are at least in part not comparable with those in our study. However, the baseline data of the two groups were similar except for the BASDAI scores. Thus, it is even more likely that the observed difference in radiographic progression may reflect a real difference. This would indicate that the speed of progression of structural changes may be reduced by infliximab therapy.

Furthermore, there are differences in the scoring process which deserve attention. The radiographs of the OASIS cohort have also been scored by the mSASSS but in a chronological time order—in contrast to the concealed time order used in our study, and the former is known to be more sensitive to change [22]. In a more recent study on a 2-yr therapy with etanercept, radiographs of the OASIS cohort have been systematically mixed with trial images [23]. Since often new readers do the scoring, the numbers indicating the rate of progression tend to vary substantially [12, 22]. This makes the interpretation and comparison of data even more difficult. However, the OASIS data are the only 4-yr X-ray data in AS available for comparison at present.

As already mentioned, the number of patients with definite radiographic change after 2 yrs was less in the group with no definite radiographic damage at BL ($n = 0$ at FU1, $n = 2$ at FU2) as compared with the group with definite baseline damage ($n = 3$ at FU1, $n = 4$ at FU2). Although these numbers are rather small, the thus derived possible hypothesis is that the overall radiographic progression in AS patients could have been even less if anti-TNF therapy would have been initiated in an earlier phase of disease before radiographic damage has occurred.

In summary, this study suggests that infliximab may decelerate but not inhibit structural progression in patients with AS. The ongoing large trials with the anti-TNF compounds—infliximab, etanercept and adalimumab—will hopefully shed further light on these important questions.

Rheumatology key message

- Long-term infliximab treatment seems to decelerate but not inhibit structural deterioration in patients with AS

M.R, J.S and J.B participated in advisory board meetings by Schering-Plough, Essex, Abbott and received speaker's honoraria from Schering-Plough, Essex, Wyeth, Abbot and Pfizer.

References

1 Calin A, Porta J, Fries JF, Schurman DJ. Clinical history as a screening test for ankylosing spondylitis. JAMA 1977;237:2613–4.
2 Braun J, Brandt J, Listing J *et al.* Treatment of active ankylosing spondylitis with infliximab: a randomised controlled multicentre trial. Lancet 2002;359:1187–93.
3 Braun J, Baraliakos X, Brandt J *et al.* Persistent clinical response to the anti-TNF antibody infliximab in patients with ankylosing spondylitis over 3 years. Rheumatology 2005;44:670–6.
4 Braun J, Baraliakos X, Golder W *et al.* Magnetic resonance imaging examinations of the spine in patients with ankylosing spondylitis, before and after successful therapy with infliximab: evaluation of a new scoring system. Arthritis Rheum 2003;48:1126–36.
5 Creemers MC, Franssen MJ, van't Hof MA, Gribnau FW, van de Putte LB, van Riel PL. Assessment of outcome in ankylosing spondylitis: an extended radiographic scoring system. Ann Rheum Dis 2005;64:127–9.
6 Wanders A, van der Heijde D, Landewe R *et al.* Inhibition of radiographic progression in ankylosing spondylitis (AS) by continuous use of NSAIDs. Arthritis Rheum 2005;52(6):1756–65.
7 Braun J, Brandt J, Listing J *et al.* Two year maintenance of efficacy and safety of infliximab in the treatment of ankylosing spondylitis. Ann Rheum Dis 2005;64:229–34.
8 Baraliakos X, Listing J, Rudwaleit M, Brandt J, Sieper J, Braun J. Progression of radiographic damage in patients with AS-assessment of definite change and definition of predictive factors 2005; Annual Meeting of the American College of Rheumatology, San Antonio, TX, 12–17 November 2005.
9 Baraliakos X, Listing J, Brandt J *et al.* Clinical response to discontinuation of anti-TNF therapy in patients with ankylosing spondylitis after 3 years of continuous treatment with infliximab. Arthritis Res Ther 2005;7:R439–44.
10 Averns HL, Oxtoby J, Taylor HG, Jones PW, Dziedzic K, Dawes PT. Radiological outcome in ankylosing spondylitis: use of the Stoke Ankylosing Spondylitis Spine Score (SASSS). Br J Rheumatol 1996;35:373–6.
11 Taylor HG, Beswick EJ, Dawes PT. Sulphasalazine in ankylosing spondylitis. A radiological, clinical and laboratory assessment. Clin Rheumatol 1991;10:43–8.
12 Wanders AJ, Landewe RB, Spoorenberg A *et al.* What is the most appropriate radiologic scoring method for ankylosing spondylitis? A comparison of the available methods based on the outcome measures in rheumatology clinical trials filter. Arthritis Rheum 2004;50:2622–32.
13 Baraliakos X, Listing J, Rudwaleit M, Brandt J, Sieper J, Braun J. Radiographic progression in patients with ankylosing spondylitis after 2 years of treatment with the tumour necrosis factor alpha antibody infliximab. Ann Rheum Dis 2005;64:1462–6.
14 Garrett S, Jenkinson T, Kennedy LG, Whitelock H, Gaisford P, Calin A. A new approach to defining disease status in ankylosing spondylitis: the Bath Ankylosing Spondylitis Disease Activity Index. J Rheumatol 1994;21:2286–91.
15 Smolen JS, Van Der Heijde DM, St Clair EW *et al.* Predictors of joint damage in patients with early rheumatoid arthritis treated with high-dose methotrexate with or

without concomitant infliximab: results from the ASPIRE trial. Arthritis Rheum 2006;54:702–10.
16 Gilbert L, He X, Farmer P *et al.* Inhibition of osteoblast differentiation by tumor necrosis factor-alpha. Endocrinology 2000;141:3956–64.
17 Gilbert L, He X, Farmer P *et al.* Expression of the osteoblast differentiation factor RUNX2 (Cbfa1/AML3/Pebp2alpha A) is inhibited by tumor necrosis factor-alpha. J Biol Chem 2002;277:2695–701; Epub 26 November 2001.
18 Kaneki H, Guo R, Chen D *et al.* Tumor necrosis factor promotes Runx2 degradation through up-regulation of Smurf1 and Smurf2 in osteoblasts. J Biol Chem 2006;281:4326–33; Epub 22 December 2005.
19 Martensson K, Chrysis D, Savendahl L. Interleukin-1beta and TNF-alpha act in synergy to inhibit longitudinal growth in fetal rat metatarsal bones. J Bone Miner Res 2004;19:1805–12; Epub 16 August 2004.
20 Sieper J, Baraliakos X, Listing J *et al.* Persistent reduction of spinal inflammation as assessed by magnetic resonance imaging in patients with ankylosing spondylitis after 2 yrs of treatment with the anti-tumour necrosis factor agent infliximab. Rheumatology 2005;44:1525–30.
21 Lories RJ, Derese I, de Bari C, Luyten FP. Evidence for uncoupling of inflammation and joint remodeling in a mouse model of spondylarthritis. Arthritis Rheum 2007;56:489–97.
22 Wanders A, Landewe R, Spoorenberg A *et al.* Scoring of radiographic progression in randomised clinical trials in ankylosing spondylitis: a preference for paired reading order. Ann Rheum Dis 2004;63:1601–4.
23 van der Heijde D, Landewe R, Ory P *et al.* Two-year etanercept therapy does not inhibit radiographic progession in patients with ankylosing spondylitis. Ann Rheum Dis 2006;65(Suppl. II):81.