

Review

Takayasu arteritis in children and adolescents

Juergen Brunner¹, Brian M. Feldman^{2,3}, Pascal N. Tyrrell²,
Jasmin B. Kuemmerle-Deschner^{4,5}, Lothar B. Zimmerhackl¹,
Ingmar Gassner⁵ and Susanne M. Benseler²

Abstract

Takayasu arteritis is a devastating vasculitis of the aorta and its major branches. The clinical manifestations in paediatric patients are less specific than in adults: in children the disease presents with fever, arthralgias and hypertension. Intramural inflammation results in narrowing of the blood vessel lumen and therefore hypoperfusion of the parenchyma. Conventional angiography is the gold standard diagnostic procedure. Corticosteroids, cyclophosphamide, MTX and biological therapies such as TNF- α blocking agents are treatment options.

Key words: Vasculitis, Angiitis, Children, Takayasu arteritis.

Introduction

Takayasu arteritis (TA) is the most common, granulomatous inflammation of large arteries; it is potentially life threatening. TA appears to have an acute early phase, with non-specific symptoms—such as hypertension, headache, fever, muscle pain, arthralgia, night sweats and weight loss. Due to the non-specific symptoms and the absence of specific laboratory parameters, the disease is often unrecognized in this phase, although the diagnosis should be made early if possible. If untreated, during the next phase the disease affects the aorta and its main branches. Vessel wall inflammation leads to concentric wall thickening, fibrosis and thrombus formation. Affected vessels may become stenotic or may develop aneurysms and vascular remodelling. Presenting symptoms at this stage commonly reflect end-organ ischaemia—such as renal infarction and stroke [1, 2]. Since large-vessel biopsies are most often not possible, the diagnosis of TA is based on clinical criteria. Laboratory investigations should support the diagnosis of TA and imaging results must be confirmatory. The diagnosis of TA remains a challenge to clinicians.

To date, few studies on TA in childhood have been published [3–5]. This review focuses on the clinical presentation and diagnosis of TA in childhood and adolescence, differential diagnosis and therapeutic approach.

Epidemiology

The incidence of TA in adults is estimated to be 2.6/1 000 000/year in North America and 1/1 000 000/year in Europe overall [6–8]. The incidence in Sweden is reported at 1.2/1 000 000, in the UK 0.8/1 000 000 and in Kuwait 2.2/1 000 000 [9–12]. The incidence reported for Japan is 2/1 000 000 [13]. Studies show that the disease is distributed all over the world and is not restricted to any one ethnic group. The reported female: male ratio ranges from 1.2:1 in Israel to 6.9:1 in Mexico [13–15]. The incidence of TA in children is unknown. Kerr *et al.* [7] included 30% paediatric patients in their study and reported an incidence in all ages of 2.6/1 000 000.

Classification and diagnosis

Classification criteria

In 1978, Ishikawa proposed criteria for the clinical diagnosis of TA based on an analysis of 96 Japanese patients. The patients' age had to be <30 years. Fulfilling the two major and at minimum one minor criteria or one major and at least four of nine minor criteria (representing vessel involvement) resulted in a diagnostic sensitivity of 84% and a specificity of 95% [16]. The patients were only compared with a control group of 12 persons with other aortic diseases but not with a control group with other inflammatory vascular diseases [17]. The Ishikawa criteria

¹Department of Pediatrics, Medical University Innsbruck, Innsbruck, Austria, ²Division of Rheumatology, Department of Pediatrics, The Hospital for Sick Children, ³Department of Health Policy Management and Evaluation, Medicine and the Dalla Lana School of Public Health, University of Toronto, Toronto, Canada, ⁴Department of Pediatrics, Eberhard-Karls University, Tuebingen, Germany and ⁵Department of Radiology, Medical University Innsbruck, Innsbruck, Austria.

Submitted 10 March 2010; revised version accepted 28 April 2010.

Correspondence to: Juergen Brunner, Department of Pediatrics, Pediatric Rheumatology, Medical University Innsbruck, Anichstrasse 35, 6020 Innsbruck, Austria. E-mail: juergen.brunner@uki.at

are very detailed and therefore considered somewhat impractical for clinical practice.

In 1990, the ACR TA classification criteria were proposed, which consisted of: (i) age at disease onset <40 years; (ii) claudication of the extremities; (iii) decreased brachial artery pulse; (iv) blood pressure difference >10 mmHg between arms; (v) bruit over subclavian arteries or aorta; and (vi) arteriogram abnormality, which is not related to arteriosclerosis or fibromuscular dysplasia (FMD) [18].

The ACR TA criteria were validated by comparing 63 TA patients with 744 people suffering from other types of vasculitis. The addition of laboratory markers including elevated ESR, anaemia and hypergammaglobulinaemia improved the test characteristics. Evidence of three or more criteria led to a specificity of 97.8% and a sensitivity of 90.5% for TA. A classification tree was constructed with five of these six criteria, omitting claudication of an extremity. The classification tree demonstrated a sensitivity of 92.1% and a specificity of 97.0%. Eighteen TA patients were children or adolescents [18]. In an effort to optimize the Ishikawa criteria, Sharma *et al.* [19] published a modification in 1995. Their modifications likely made the Ishikawa criteria even more impractical. In 2007, members of a consensus conference of the Pediatric Rheumatology European Society (PRES) suggested consensus criteria for the classification of childhood vasculitis subtypes including TA [20, 21]. These were endorsed by the European League Against Rheumatism. The PRES classification criteria for childhood TA mandate the evidence of angiographic abnormalities plus the presence of at least one of the TA features: (i) decreased peripheral artery pulse(s) or claudication of extremities; (ii) a blood pressure difference >10 mmHg; (iii) bruits over the aorta or its major branches; and (iv) hypertension (related to childhood normative data) [21]. These criteria have yet to be validated within cases of childhood vasculitis and TA mimics.

Researchers have attempted to define distinct subtypes of TA based on angiographic characteristics, which then could provide a basis for therapeutic decision making [17, 22–24]. These approaches have not had a great impact on clinical practice so far.

Clinical features

Clinical diagnosis of TA commonly presents a challenge to the clinician. It is estimated that one-third of children present with inactive, so-called 'burnt-out' disease, in which clinical features represent vascular sequelae rather than active vasculitis. Both the natural history and the time from onset of symptoms to diagnosis are variable. It is likely that the non-specific clinical presentation of childhood TA contributes to a delay in diagnosis. The clinical spectrum at presentation of children with TA differs from that of adults; however, hypertension is the most common symptom in both groups. Children frequently have hypertension, headaches, fever and weight loss at diagnosis of TA [2, 16, 25–54]. The most common presenting features in adulthood are hypertension and bruits [6, 7, 55–61].

General features

The most frequent presentation in childhood is hypertension (82.6%), followed by headaches (31%), fever (29%), dyspnoea (23%), weight loss (22%) and vomiting (20.1%) [2, 16, 25–54]. Non-specific symptoms such as abdominal pain (16.6%) and vomiting can herald TA in children [3, 4]. Musculoskeletal symptoms are, overall, observed in only 14% of children with TA [2, 16, 25–54]. However, in South American TA patients, arthritis appears to be more common and has been noted in 65% [4]. In contrast, adult patients rarely report arthritis or arthralgia at diagnosis of TA [6, 7, 61, 62]. Clinical data are summarized in Table 1. TA has been found to be associated with RA and chronic IBD [59, 63].

Organ-specific features

Organ manifestations result from decreased blood supply due to vascular stenosis and subsequent ischaemia in the vascular territory. Claudication (13%) and poor or absent arterial pulses (13%) occur in areas of vessel involvement [2, 16, 25–54]. Bruits are uncommonly described. Secondary cardiac disease is reported in 19% of paediatric patients [2, 16, 25–54]. In contrast, the most common vascular symptoms in adults are bruits (48%) and claudication (27%) [6, 7, 55–61]. In paediatric TA, neurological manifestations include headaches (31%) and stroke (17%) [2, 16, 25–54]. Skin manifestations including nodules and rashes are uncommon [4, 64–66]. Skin ulcers are not reported in children. Lymphadenopathy is uncommon [4]. Ocular manifestations such as retinopathy are rare in children [3, 67, 68].

The diagnosis of childhood TA remains challenging due to the often non-specific character of symptoms including headaches, fever, dyspnoea, weight loss, vomiting, abdominal pain and musculoskeletal symptoms. The combination of systemic symptoms of inflammation, decreased or absent pulses and possibly intermittent or activity-related features of organ ischaemia should raise the level of suspicion for TA. Suspicion of the diagnosis mandates additional testing.

Common laboratory tests

There is no specific laboratory marker for TA. Classical inflammatory markers are commonly tested; 53% of children had an elevated ESR compared with 45% of adult TA patients overall. ESR is considered the best available routine laboratory indicator for disease activity of TA in adolescents [7, 17, 69–71]. However, the ESR may continue to be elevated in disease remission [7, 69]. CRP is increasingly measured as a disease activity marker in TA. It appears to correlate well with active TA. High CRP levels have also been found to be associated with a higher risk of thrombotic complications in TA [72–74].

Novel laboratory markers

Novel TA markers including tissue plasminogen activator, intercellular adhesion molecule-1, vascular cell adhesion molecule-1, E-selectin and platelet endothelial cell adhesion molecule-1 were evaluated in TA and appear to

TABLE 1 Clinical and laboratory characteristics of paediatric patients with TA

Patients Author	Paediatric										Case series		
	Cakar	D'Souza	Fieldstone	Hahn	Hong	Jain	Morales	Muranjan	Case reports	Summary, n (%)	Adult, n (%)		
Year of publication	2008	1998	2003	1998	1992	2000	1991	2000	1994–2008				
Number of patients, n	19	11	6	31	70	24	26	17	41	241	844		
Sex female: male	2.8:1	1.2:1	7.0:1	1.3:1	4.3:1	5.0:1	3.3:1	0.8:1	2.0:1	3.0:1	Total		
Age (mean), years	8–17 (13)	4–17 (9.6)	1.7–17 (9.9)	2.4–14.5 (8.4)	3–15 (9.4)	<18 (14)	3–15 (11.7)	5–11 (9.3)	1–18 (8.5)	1–18 (10)			
Location (country)	Turkey	Canada	USA	South Africa	Korea	India	Mexico	India	Distributed				
General, n (%)													
Fever	5 (26)	NR	5 (83)	2 (6)	NR	1 (4)	17 (65)	3 (17)	14 (34)	47/160 (29.4)	125 (14.8)		
Weight loss	2 (11)	NR	4 (66)	NR	11 (15)	1 (4)	17 (65)		9 (22)	44/199 (22.1)	80 (9.4)		
Chest pain		NR	2 (33)	NR	5 (7)			2 (11)	6 (15)	15/199 (7.5)	83 (9.8)		
Abdominal pain	7 (37)	NR		NR	4 (5)		13 (50)		9 (22)	33/199 (16.6)	6 (0.7)		
Vomiting		NR	2 (33)	NR	13 (18)	4 (16)	13 (50)	3 (17)	5 (12)	40/199 (20.1)	11 (1.3)		
Epistaxis		NR		NR	2 (2)		7 (26)			9/199 (4.5)			
Palpitations		NR	2 (33)	NR	22 (31)	3 (12)		2 (11)		29/199 (14.6)			
Cough		NR		NR	11 (15)			2 (11)	2 (5)	15/199 (7.5)			
Headache	16 (84)	2 (18)		NR	29 (41)	13 (54)		3 (17)	3 (7)	66/210 (31.4)	212 (25.0)		
Syncope		NR		NR		4 (16)				4/199 (2.0)			
Hypertension	17 (89)	11 (100)	4 (66)	26 (84)	65 (93)	20 (83)	22 (85)	11 (65)	23 (56)	199/241 (82.6)	445 (52.5)		
Dermal manifestation		NR	3 (50)	2 (6)			5 (19)		2 (5)	12/230 (5.2)	31 (3.7)		
Arthralgia/arthritis	3 (16)	NR		2 (6)	1 (1)	1 (4)	17 (65)	2 (11)	7 (17)	33/230 (14.3)	143 (16.9)		
Dyspnoea		NR		NR	37 (52)	5 (20)		4 (23)	3 (7)	49/210 (23.3)	83 (9.8)		
Organ specific, n (%)													
Poor pulses anywhere	11 (58)	NR		10 (32)				7 (41)	2 (5)	30/230 (13.0)	191 (22.5)		
Bruits	5 (26)	NR	1 (16)	12 (38)		14 (58)			6 (15)	38/230 (16.5)	410 (48.4)		
Claudication	6 (32)	4 (36)	4 (66)	4 (12)	5 (7)		8 (30)		1 (2)	32/241 (13.3)	229 (27.0)		
Stroke/encephalopathy		NR	2 (33)	7 (22)	15 (21)	4 (16)		6 (35)	5 (12)	39/230 (16.9)	64 (7.6)		
Cardiac disease	8 (42)	NR		20 (64)		4 (16)		8 (47)	12 (29)	52/230 (22.6)	172 (20.3)		
Respiratory disease		2 (18)		NR						2/210 (0.9)			
Uveitis		NR	3 (50)	2 (6)			5 (19)		2 (5)	12/230 (5.2)			
Laboratory, n (%)													
ESR	19 (100)	NR	6 (100)	23 (83)	37 (52)	10 (42)	19 (73)	11 (65)	16 (39)	141/230 (61.0)	383 (45.2)		

The patients reported in clinical studies [3, 4, 64, 65, 67, 83, 84] and case series [2, 24, 54] are compared with clinical presentation of adult patients [6, 7, 55–61]. The percentage of clinical manifestations is related to the amount of paediatric patients enrolled in studies asking for the manifestation. NR: not reported.

correlate with other measurements of vascular inflammation and disease activity [75, 76]. Specific AECA have been found in patients with TA in recent studies; their pathogenic role remains unclear [73, 77, 78]. AECA may cause endothelial cell activation and expression of adhesion molecules, assisting and continuing the inflammation in TA [79]. Anti-monocyte antibodies and AECA are present in a significant proportion of adult patients with TA and correlate with disease activity [7, 77, 78]. Annexin V is a regulatory protein in apoptosis. Antibodies directed against annexin V have been shown to lead to apoptosis of vascular endothelial cells [80]. Antibodies against annexin V have been demonstrated in adult patients in conjunction with AECA [81]. Platelets and pro-coagulatory markers are frequently increased in TA, possibly causing a hypercoagulable state and increased risk of thrombus formation [76, 82].

So far, no TA-specific laboratory marker of disease activity is available. Classical inflammatory markers have limited sensitivity and lack specificity. Raised inflammatory markers are more often than not associated with active inflammation in TA.

Imaging

A combination of imaging modalities is commonly required for diagnosis and monitoring of TA in children. Vascular imaging is accomplished by conventional angiography, magnetic resonance angiography (MRA), CT angiography (CTA) or Doppler ultrasound. Distinct vessel wall imaging techniques include gadolinium-enhanced MRA and more recently fluorodeoxyglucose PET.

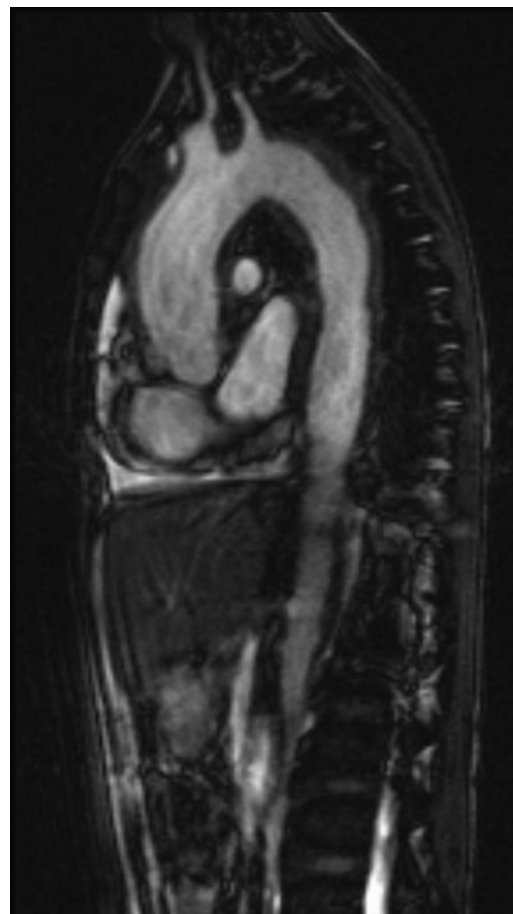The thoracic and abdominal aorta are the vessels most often involved in childhood TA [3, 4, 64, 65, 67, 83, 84]; the characteristic appearance on angiography is diffuse aortic involvement [4]. Recent studies have included 19 patients investigated with conventional angiography [15] or MRA [4]. One hundred and thirty-seven vascular lesions were detected, with stenosis being the most common type of lesion (53%). Occlusion was present in 21%, dilatation in 16% and aneurysm in 10% of patients. In this series of studies, the most frequently involved vessels were the renal arteries (in 73% of the patients), the subclavian arteries (in 57%) and the carotid arteries (in 52%). The thoracic or abdominal aorta was affected in ~50% of the children [29]. Several classifications have been proposed based on the distribution of angiographic abnormalities seen in TA [17, 23, 24, 85].

The diagnosis of TA in children is often based on the findings of conventional angiography of the aorta and its branches, which is considered the gold standard [22]. Conventional angiography is invasive, is associated with exposure to a significant radiation dose, requires iodinated contrast material and can be difficult to perform—especially in young children or patients with high degree of vascular stenosis. The strength of the conventional angiogram is the exact visualization of flow in the blood vessels and the extent of collateralization. It provides an estimate of ischaemic risk. Conventional angiography does not provide information about the vessel wall

itself [86–89]. Vascular narrowing may be due to acute intramural inflammation or chronic wall fibrosis [90], which are indistinguishable by conventional angiography.

MRA is a less invasive imaging technique. It can provide calculated, non-dynamic blood flow information. Its strength is that MRA provides important additional information about the vessel wall. Mild inflammation of the wall without associated significant stenosis will be missed by conventional angiography but may be picked up by MRA [87, 88]. Axial T_1 -weighted MRA best demonstrates abnormal wall thickening of the vessels. The inflammatory oedema of the wall causes a bright T_2 -weighted signal. Contrast-enhanced MRA further depicts vessel wall irregularity (Fig. 1). Focal TA disease activity can be determined in contrast-enhanced MRI, which has been shown to correlate with clinical and laboratory findings in some patients [88]. Designated 'oedema-weighted' images in MRI detect fluid, representing inflammation, within the vessel wall. Evidence of new anatomical lesions with evidence of vessel wall oedema is thought to represent active disease [91]. Clinical and laboratory features plus

Fig. 1 14 2/12-year-old girl with TA. MRI: sagittal oblique section: pronounced thickening of the aortic wall in its entire length Ectasia of the ascending aorta, aortic arch and descending aorta.



conventional angiography and MRA represent the most commonly utilized diagnostic tool set of TA. [91].

CTA provides similar information about disease to MRA [92]. Spiral CTA with breath-hold technique makes well-enhanced, thin-section transaxial images available and reveals luminal narrowing. Additionally, it points out mural changes as high-attenuation wall changes in pre-contrast CT images, circumferential wall thickening with inhomogeneous enhancement or a concentric low-attenuation ring inside the aortic wall [7, 93]. Maximal intensity projection images show luminal obstruction or narrowing or dilatation of the vessels as well. In the delayed phase mural enhancement is also present [7, 92, 94]. Radiation exposure has to be considered as CTA involves a large dose of radiation.

Ultrasonography is useful in establishing an early diagnosis of TA [95, 96]. Comparison of ultrasound with angiography has shown agreement on stenosis in 97% when examining the common carotids, 95% for the brachiocephalic trunks and 97% for the vertebral arteries [97]. Sonography reveals thickening of affected vessel walls, occlusion and dilatation. Sonography might help to establish early disease of TA in a pre-stenotic phase in the extracranial vessels [96]. Alterations in flow velocity can be determined (Fig. 2A and B). The method is inexpensive and without radiation exposure. Limitations include the investigator-dependent quality of the examination.

18FDG-PET is an imaging technique used to assess the increased glucose metabolism in inflammatory cells. Some recent studies have concluded that there is a possible role for 18FDG-PET as a screening method in early TA, especially for those patients presenting with uncharacteristic symptoms [98–100]. It appears that 18FDG-PET can identify more vascular regions affected by the inflammatory process than MRA [101]. However, the PET results

are not specific for vasculitis [102]. Although PET scanning may provide valuable information about inflammation in the arterial wall, it cannot show changes in the structure (and therefore the damage) of the vessel wall nor it can show luminal blood flow. PET access is limited to large medical centres; for this reason there is a lack of standardization of PET imaging for TA.

In conclusion, conventional angiography is still the gold standard for the diagnosis of TA. MRA and MRI are helpful in monitoring the disease. Standardized high-resolution sonography might become an important addition to the diagnostic armamentarium.

Differential diagnosis

In children with suspected TA, some more common diagnoses have to be considered. The differential diagnosis includes developmental disorders (coarctation and Marfan syndrome), other autoimmune disorders [primary vasculitides (Behçet's disease, Kawasaki disease and thrombangiitis obliterans), secondary vasculitides (SLE, SpA and sarcoidosis) or infectious aortitis (tuberculosis, syphilis, *Staphylococcus aureus*, *Salmonella*, *Treponema*, CMV or herpes virus) [103–106]. An association of true TA with tuberculosis, in some regions, has been suggested [104, 107]. Both TA and tuberculosis are chronic granulomatous diseases. Active tuberculosis has been recognized in up to 20% of patients with TA [55]. TA and tuberculosis have been associated with HLA-B alleles; however, these have different distributions in TA and tuberculosis [108]. The role of tuberculosis in the pathogenesis of TA is therefore unclear. Cross-reactivity between *Mycobacteria* and human HSP may play a role [109]. TA is associated more often with vascular stenosis, whereas tuberculosis is more often associated with erosion of the vessel wall and aneurysm development. TB particularly affects the descending thoracic and abdominal aorta [1]. Regarding hypertension, FMD is an important differential diagnosis [1]. Differentiating TA from FMD may be a challenge; however, FMD is not an inflammatory disease.

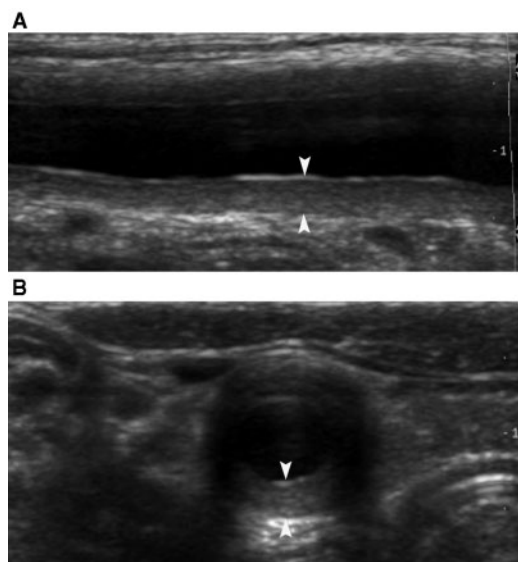
Therapy

Adequate therapy in TA is important to prevent irreversible vessel damage with resulting insufficiency of vital organs. Corticosteroids are still the mainstay of treatment [1]. Other immunosuppressive agents are a therapeutic option [1].

Glucocorticoids are an effective agent for most patients with active TA. Remission has been achieved in 60% of patients treated with glucocorticoids alone [6, 7, 110, 111]. Although improvement of symptoms in TA usually follows glucocorticoid therapy, relapses usually occur with dosage reduction [73].

In the most recent survey, 19 children with TA all received prednisone (2 mg/kg/day). The dose was tapered after 1–2 months and was thereafter continued at alternate day dosing; the lowest dose was 5–10 mg/alternate days. Nine patients received additional

Fig. 2 Ultrasound examination of the right carotid artery in (A) longitudinal and (B) cross-section: marked echogenic mural thickening (arrowheads).



cyclophosphamide and one patient received infliximab. MTX (10–12.5 mg/m²/week) was used in 11 patients and AZA (2 mg/kg/day) was used in 5 patients. All 17 patients with hypertension were treated for their hypertension. Ten patients with renal artery stenosis underwent surgery or interventional radiographical stenting [29]. There are no randomized therapeutic trials in TA. Immunomodulatory drugs, such as MTX and mycophenolate mofetil, are believed to be of some benefit in TA [6, 7, 52, 110–112]. The best observational evidence for treatment is for corticosteroids (to which 50% appear to respond) and MTX (to which a further 50% appear to respond) [1].

In about one-fourth of the treated patients, remission is never achieved [111]. Anti-TNF therapy may be a possible beneficial agent for these patients. The initial series have shown seemingly successful results with improvement in patients with therapy-resistant TA. In an open-label trial of anti-TNF therapy, including 15 patients with active, relapsing TA, addition of anti-TNF resulted in improvement in 14 of 15 patients [113].

The role of intravenous immunoglobulin, recombinant IL-1 receptor antagonists, IL-4 and transforming growth factor is speculative [113]. In patients with TA, platelet and coagulation activities may be increased resulting in a hypercoagulable state and sometimes in thrombus formation. Therefore, some have advocated including heparin or anti-platelet agents when treating PA [76, 82].

Percutaneous transluminal angioplasty (PCTA) is the commonest palliative procedure performed, with a success rate varying from 56 to 80% [7]. Stenosis in TA can be effectively dilated by PCTA [114, 115]. However, despite providing short-term benefit, endovascular revascularization procedures (bypass grafts, patch angioplasty, endarterectomy, PTA, stent placement) are associated with a high failure rate in patients with TA [116–118].

Outcome

Anti-inflammatory therapy can lead to dramatic improvement in TA. The 5-year survival rate in adults is as high as 94% [119]. The mortality rate in children, though, is as high as 35% [4]. The outcome depends on the vessel involvement and on the severity of hypertension [3]. In a Turkish survey, one patient with pulmonary artery stenosis died within the first 3 years and two patients underwent nephrectomy [29]. In South Africa, the mortality rate was 22.5%; 7 of 31 patients died because of hypertension or complications after kidney transplantation. One patient died after EBV-associated haemophagocytic syndrome [65]. In India, 2 of 24 patients (8.3%) died because of renal failure and congestive heart failure [84]. Prevention of organ damage may avoid worse outcome.

Summary

TA in children and adolescents is a potentially life-threatening condition. The diagnosis should be suspected in a child presenting with symptoms of hypertension, fever, weight loss and vomiting. An awareness of TA,

and appropriate suspicion, is the first step for clinical diagnosis. TA is thought to require early diagnosis for the best outcome. Each child with suspected TA requires a thorough diagnostic evaluation to exclude other conditions on the differential diagnosis and to confirm the diagnosis of TA. Classical inflammatory markers have limited sensitivity. Angiography is the standard for establishing the diagnosis. Non-invasive methods such as ultrasound may be considered, and may become more useful in the future. Corticosteroids are the standard therapy. Corticosteroids are frequently combined with other immunomodulatory treatments especially for therapy-resistant disease.

Rheumatology key messages

- In children with fever, vomiting and weight loss, TA should be considered in the differential diagnosis.
- Musculoskeletal symptoms, cardiovascular signs, headaches, dyspnoea and abdominal pain may point to TA.
- The diagnosis of TA is supported by elevated inflammatory markers. Suspected TA mandates vascular imaging.

Disclosure statement: The authors have declared no conflicts of interest.

References

- 1 Johnston SL, Lock RJ, Gompels MM. Takayasu arteritis: a review. *J Clin Pathol* 2002;55:481–6.
- 2 Brunner J, Armstrong D, Feldman BM, Schneider R, Benseler S. Childhood stroke as the presentation of Takayasu's arteritis: diagnostic delay can cause catastrophic complications. *J Rheumatol* 2008;35:1228–30.
- 3 Hong CY, Yun YS, Choi JY *et al.* Takayasu arteritis in Korean children: clinical report of seventy cases. *Heart Vessels* 1992;7(Suppl. 7):91–6.
- 4 Morales E, Pineda C, Martinez-Lavin M. Takayasu's arteritis in children. *J Rheumatol* 1991;18:1081–4.
- 5 Vanoli M, Miani S, Amft N, Bacchiani G, Radelli L, Scorza R. Takayasu's arteritis in Italian patients. *Clin Exp Rheumatol* 1995;13:45–50.
- 6 Hall S, Barr W, Lie JT, Stanson AW, Kazmier FJ, Hunder GG. Takayasu arteritis. A study of 32 North American patients. *Medicine* 1985;64:89–99.
- 7 Kerr GS, Hallahan CW, Giordano J *et al.* Takayasu arteritis. *Ann Intern Med* 1994;120:919–29.
- 8 Reinhold-Keller E, Herlyn K, Wagner-Bastmeyer R, Gross WL. Stable incidence of primary systemic vasculitides over five years: results from the German vasculitis register. *Arthritis Rheum* 2005;53:93–9.
- 9 El-Reshaid K, Varro J, al-Duwairi Q, Anim JT. Takayasu's arteritis in Kuwait. *J Trop Med Hyg* 1995;98:299–305.
- 10 Waern AU, Andersson P, Hemmingsson A. Takayasu's arteritis: a hospital-region based study on occurrence, treatment and prognosis. *Angiology* 1983;34:311–20.

- 11 Watts RA, Lane S, Scott DG. What is known about the epidemiology of the vasculitides? *Best Pract Res Clin Rheumatol* 2005;19:191–207.
- 12 Watts R, Al-Taiar A, Mooney J, Scott D, Macgregor A. The epidemiology of Takayasu arteritis in the UK. *Rheumatology* 2009;48:1008–11.
- 13 Koide K. Takayasu arteritis in Japan. *Heart Vessels* 1992;7(Suppl. 7):48–54.
- 14 Dabague J, Reyes PA. Takayasu arteritis in Mexico: a 38-year clinical perspective through literature review. *Int J Cardiol* 1996;54(Suppl.):S103–9.
- 15 Rosenthal T, Morag B, Itzhak Y. Takayasu arteritis in Israel. *Heart Vessels* 1992;7(Suppl. 7):44–7.
- 16 Rossor E. Takayasu's arteritis as a differential diagnosis of systemic juvenile chronic arthritis. *Arch Dis Child* 1979;54:798–800.
- 17 Ishikawa K. Natural history and classification of occlusive thromboasopathy (Takayasu's disease). *Circulation* 1978;57:27–35.
- 18 Arend WP, Michel BA, Bloch DA *et al.* The American College of Rheumatology 1990 criteria for the classification of Takayasu arteritis. *Arthritis Rheum* 1990;33:1129–34.
- 19 Sharma BK, Jain S, Suri S, Numano F. Diagnostic criteria for Takayasu arteritis. *Int J Cardiol* 1996;54(Suppl.):S141–7.
- 20 Dillon MJ, Ozen S. A new international classification of childhood vasculitis. *Pediatr Nephrol* 2006;21:1219–22.
- 21 Ozen S, Ruperto N, Dillon MJ *et al.* EULAR/PRReS endorsed consensus criteria for the classification of childhood vasculitides. *Ann Rheum Dis* 2006;65:936–41.
- 22 Lupi-Herrera E, Sanchez-Torres G, Marcushamer J, Mispireta J, Horwitz S, Vela JE. Takayasu's arteritis. Clinical study of 107 cases. *Am Heart J* 1977;93:94–103.
- 23 Moriwaki R, Noda M, Yajima M, Sharma BK, Numano F. Clinical manifestations of Takayasu arteritis in India and Japan—new classification of angiographic findings. *Angiology* 1997;48:369–79.
- 24 Nasu T. Aortic syndrome: pathologic aspect. *Gendai Iryo* 1976;8:1143–50.
- 25 Adderson EE, Shultz PK, Bohnsack JF. Radiological case of the month. Takayasu arteritis. *Arch Pediatr Adolesc Med* 1999;153:995–6.
- 26 Al AS, Fouillet-Desjonqueres M, David L, Barral X, Cochat P, Cimaz R. Takayasu arteritis in children. *Pediatr Rheumatol Online J* 2008;6:17.
- 27 Arslan N, Buyukgebiz B, Ozturk Y. Celiac disease with Takayasu arteritis. *Pediatr Int* 2005;47:708–10.
- 28 Becker RW, Sohn RL, Poulik JM, Berguer R. Takayasu's arteritis presenting as uveitis in a 5-year-old girl. *Ann Vasc Surg* 2005;19:258–62.
- 29 Cakar N, Yalcinkaya F, Duzova A *et al.* Takayasu arteritis in children. *J Rheumatol* 2008;35:913–9.
- 30 Campos LM, Castellanos AL, Afiune JY, Kiss MH, Silva CA. Takayasu's arteritis with aortic aneurysm associated with Sweet's syndrome in childhood. *Ann Rheum Dis* 2005;64:168–9.
- 31 Dourmishev AL, Serafimova DK, Vassileva SG, Dourmishev LA, Schwartz RA. Segmental ulcerative vasculitis: a cutaneous manifestation of Takayasu's arteritis. *Int Wound J* 2005;2:340–5.
- 32 Ehrlich G. Takayasu's arteritis and Still's disease. *Arthritis Rheum* 1979;22:1422.
- 33 Eke F, Balfe JW, Hardy BE. Three patients with arteritis. *Arch Dis Child* 1984;59:877–83.
- 34 Gerhardt RT, De Lorenzo RA. Takayasu arteritis presenting as a recurrent respiratory tract infection: a diagnosis facilitated by bedside echocardiography and increased erythrocyte sedimentation rate. *Mil Med* 2002;167:170–1.
- 35 Goodman D, Shulman S, Fenik J *et al.* A 19-month-old girl with congestive heart failure, hypertension, and coronary artery dilatations. Interview by Robert Listernick. *Pediatr Ann* 2005;34:14–9.
- 36 Hall S, Nelson AM. Takayasu's arteritis and juvenile rheumatoid arthritis. *J Rheumatol* 1986;13:431–3.
- 37 Hijazi R, Chandar J, Nwobi O, Muneeruddin S, Zilleruelo G, Abitbol CL. Renal manifestations in toddlers with Takayasu's arteritis and malignant hypertension. *Pediatr Nephrol* 2009;24:1227–30.
- 38 Iga K, Hori K, Matsumura T, Kijima K, Miyamoto T, Gen H. Multiple peripheral pulmonary artery branch stenosis in a young Japanese girl with systemic hypertension. *Chest* 1994;105:1294–5.
- 39 Kalangos A, Baldovinos A, Beghetti M, Vala D, Faidutti B. Ascending aortic aneurysm associated with aortic insufficiency due to Takayasu's arteritis. *Ann Thorac Surg* 1999;68:248–50.
- 40 Kausman JY, Walker A, Piper S. Acute panuveitis and Takayasu's arteritis. *Arch Dis Child* 2003;88:938–9.
- 41 Kohrman MH, Huttenlocher PR. Takayasu arteritis: a treatable cause of stroke in infancy. *Pediatr Neurol* 1986;2:154–8.
- 42 Limsuwan A, Khowsathit P, Pienvichit P. Left main coronary occlusion from Takayasu arteritis in an 8-year-old child. *Pediatr Cardiol* 2007;28:234–7.
- 43 Millar AJ, Gilbert RD, Brown RA, Immelman EJ, Burkimsher DA, Cywes S. Abdominal aortic aneurysms in children. *J Pediatr Surg* 1996;31:1624–8.
- 44 Murakami K, Ohsawa M, Hu SX, Kanno H, Aozasa K, Nose M. Large-vessel arteritis associated with chronic active Epstein-Barr virus infection. *Arthritis Rheum* 1998;41:369–73.
- 45 Noyer B, Guerin B, Delarche N, Estrade G, Monlun E, Doireau V. [Takayasu disease revealed by dorsalgia]. *Arch Pediatr* 2004;11:1462–4.
- 46 Opastirakul S, Chartapisak W, Sirivanichai C. A girl with Takayasu arteritis associated with possible systemic lupus erythematosus. *Pediatr Nephrol* 2004;19:463–6.
- 47 Ostrov BE, Frazer TB. Sudden death in a 14-year-old girl. *J Clin Rheumatol* 1997;3:41–4.
- 48 Rath B, Gupta S, Tyagi S, Mathur RP, Talukdar B. Pulseless disease with renal amyloidosis. *Pediatr Nephrol* 1996;10:129–30.
- 49 Ravelli A, Pedroni E, Perrone S, Tramarin R, Martini A, Burgio GR. Aortic valve regurgitation as the presenting sign of Takayasu arteritis. *Eur J Pediatr* 1999;158:281–3.
- 50 Sato R, Sato Y, Ishikawa H *et al.* Takayasu's disease associated with ulcerative colitis. *Intern Med* 1994;33:759–63.
- 51 Sebnem Kilic S, Bostan O, Cil E. Takayasu arteritis. *Ann Rheum Dis* 2002;61:92–3.

- 52 Shetty AK, Stopa AR, Gedalia A. Low-dose methotrexate as a steroid-sparing agent in a child with Takayasu's arteritis. *Clin Exp Rheumatol* 1998;16:335–6.
- 53 Tsai MJ, Lin SC, Wang JK, Chou CC, Chiang BL. A patient with familial Takayasu's arteritis presenting with fever of unknown origin. *J Formos Med Assoc* 1998;97:351–3.
- 54 Wolf RL, Gould NS, Green CA. Unusual arteritis causing myocardial infarction in a child. *Arch Pathol Lab Med* 1987;111:968–71.
- 55 Mwipatayi BP, Jeffery PC, Beningfield SJ *et al.* Takayasu arteritis: clinical features and management: report of 272 cases. *ANZ J Surg* 2005;75:110–7.
- 56 Park MC, Lee SW, Park YB, Chung NS, Lee SK. Clinical characteristics and outcomes of Takayasu's arteritis: analysis of 108 patients using standardized criteria for diagnosis, activity assessment, and angiographic classification. *Scand J Rheumatol* 2005;34:284–92.
- 57 Park YB, Hong SK, Choi KJ *et al.* Takayasu arteritis in Korea: clinical and angiographic features. *Heart Vessels* 1992;7(Suppl. 7):55–9.
- 58 Petrovic-Rackov L, Pejnovic N, Jevtic M, Damjanov N. Longitudinal study of 16 patients with Takayasu's arteritis: clinical features and therapeutic management. *Clin Rheumatol* 2009;28:179–85.
- 59 Reny JL, Paul JF, Lefebvre C *et al.* Association of Takayasu's arteritis and Crohn's disease. Results of a study on 44 Takayasu patients and review of the literature. *Ann Med Interne* 2003;154:85–90.
- 60 Sharma BK, Sagar S, Singh AP, Suri S. Takayasu arteritis in India. *Heart Vessels* 1992;7(Suppl. 7):37–43.
- 61 Vanoli M, Daina E, Salvarani C *et al.* Takayasu's arteritis: a study of 104 Italian patients. *Arthritis Rheum* 2005;53:100–7.
- 62 Korkmaz C, Zubaroglu I, Kaya T, Akay OM. Takayasu's arteritis associated with rheumatoid arthritis: a case report and review of the literature. *Rheumatology* 2001;40:1420–2.
- 63 Roberti I, Reisman L, Chung J. Vasculitis in childhood. *Pediatr Nephrol* 1993;7:479–89.
- 64 Fieldston E, Albert D, Finkel T. Hypertension and elevated ESR as diagnostic features of Takayasu arteritis in children. *J Clin Rheumatol* 2003;9:150–63.
- 65 Hahn D, Thomson PD, Kala U, Beale PG, Levin SE. A review of Takayasu's arteritis in children in Gauteng, South Africa. *Pediatr Nephrol* 1998;12:668–75.
- 66 Yajima M, Moriaki R, Numano F, Park YB, Cho YD. Comparative studies between Japanese and Korean patients: comparison of the findings of angiography, HLA-Bw52, and clinical manifestations. *Heart Vessels* 1992;7(Suppl. 7):102–5.
- 67 Muranjan MN, Bavdekar SB, More V, Deshmukh H, Tripathi M, Vaswani R. Study of Takayasu's arteritis in children: clinical profile and management. *J Postgrad Med* 2000;46:3–8.
- 68 Ozen S. The spectrum of vasculitis in children. *Best Pract Res Clin Rheumatol* 2002;16:411–25.
- 69 Hoffman GS, Ahmed AE. Surrogate markers of disease activity in patients with Takayasu arteritis. A preliminary report from The International Network for the Study of the Systemic Vasculitides (INSSYS). *Int J Cardiol* 1998;66(Suppl. 1):S191–4.
- 70 Martini A. Behcet's disease and Takayasu's disease in children. *Curr Opin Rheumatol* 1995;7:449–54.
- 71 Salvarani C, Cantini F, Boiardi L, Hunder GG. Laboratory investigations useful in giant cell arteritis and Takayasu's arteritis. *Clin Exp Rheumatol* 2003;21:S23–8.
- 72 Lindsley CB, Laxer RM. Granulomatous vasculitis, giant cell arteritis, and sarcoidosis. In: Cassidy JT, Petty RE, Laxer RM, Lindsley CB, eds. *Textbook of pediatric rheumatology*. 5th edition. Philadelphia: Elsevier Saunders, 2005:539–60.
- 73 Maksimowicz-McKinnon K, Bhatt DL, Calabrese LH. Recent advances in vascular inflammation: C-reactive protein and other inflammatory biomarkers. *Curr Opin Rheumatol* 2004;16:18–24.
- 74 Ozen S, Bakkaloglu A, Dusunsal R *et al.* Childhood vasculitides in Turkey: a nationwide survey. *Clin Rheumatol* 2007;26:196–200.
- 75 Arnaud L, Kahn JE, Girszyn N, Piette AM, Bletty O. Takayasu's arteritis: an update on physiopathology. *Eur J Intern Med* 2006;17:241–6.
- 76 Kasuya N, Kishi Y, Isobe M, Yoshida M, Numano F. P-selectin expression, but not GPIIb/IIIa activation, is enhanced in the inflammatory stage of Takayasu's arteritis. *Circ J* 2006;70:600–4.
- 77 Eichhorn J, Sima D, Thiele B *et al.* Anti-endothelial cell antibodies in Takayasu arteritis. *Circulation* 1996;94:2396–401.
- 78 Park MC, Park YB, Jung SY, Lee KH, Lee SK. Anti-endothelial cell antibodies and antiphospholipid antibodies in Takayasu's arteritis: correlations of their titers and isotype distributions with disease activity. *Clin Exp Rheumatol* 2006;24:S10–6.
- 79 Noris M. Pathogenesis of Takayasu's arteritis. *J Nephrol* 2001;14:506–13.
- 80 Nakamura N, Ban T, Yamaji K, Yoneda Y, Wada Y. Localization of the apoptosis-inducing activity of lupus anticoagulant in an annexin V-binding antibody subset. *J Clin Invest* 1998;101:1951–9.
- 81 Tripathy NK, Sinha N, Nityanand S. Anti-annexin V antibodies in Takayasu's arteritis: prevalence and relationship with disease activity. *Clin Exp Immunol* 2003;134:360–4.
- 82 Akazawa H, Ikeda U, Yamamoto K, Kuroda T, Shimada K. Hypercoagulable state in patients with Takayasu's arteritis. *Thromb Haemost* 1996;75:712–6.
- 83 D'Souza SJ, Tsai WS, Silver MM *et al.* Diagnosis and management of stenotic aorto-arteriopathy in childhood. *J Pediatr* 1998;132:1016–22.
- 84 Jain S, Kumari S, Ganguly NK, Sharma BK. Current status of Takayasu arteritis in India. *Int J Cardiol* 1996;54(Suppl.):S111–6.
- 85 Ueno A, Awane Y, Wakabayashi A, Shimizu K. Successfully operated obliterative brachiocephalic arteritis (Takayasu) associated with the elongated coarctation. *Jpn Heart J* 1967;8:538–44.
- 86 Aluquin VP, Albano SA, Chan F, Sandborg C, Pitlick PT. Magnetic resonance imaging in the diagnosis and follow up of Takayasu's arteritis in children. *Ann Rheum Dis* 2002;61:526–9.
- 87 Choe YH, Lee WR. Magnetic resonance imaging diagnosis of Takayasu arteritis. *Int J Cardiol* 1998;66(Suppl. 1):S175–9.

- 88 Choe YH, Han BK, Koh EM, Kim DK, Do YS, Lee WR. Takayasu's arteritis: assessment of disease activity with contrast-enhanced MR imaging. *AJR Am J Roentgenol* 2000;175:505–11.
- 89 Flamm SD, White RD, Hoffman GS. The clinical application of 'edema-weighted' magnetic resonance imaging in the assessment of Takayasu's arteritis. *Int J Cardiol* 1998;66(Suppl. 1):S151–9.
- 90 Fiessinger JN. Juvenile arteritis revisited. Buerger's disease-Takayasu's disease. *Pathophysiol Haemost Thromb* 2002;32:295–8.
- 91 Tso E, Flamm SD, White RD, Schwartzman PR, Mascha E, Hoffman GS. Takayasu arteritis: utility and limitations of magnetic resonance imaging in diagnosis and treatment. *Arthritis Rheum* 2002;46:1634–42.
- 92 Park JH. Conventional and CT angiographic diagnosis of Takayasu arteritis. *Int J Cardiol* 1996;54(Suppl.):S165–71.
- 93 Kissin EY, Merkel PA. Diagnostic imaging in Takayasu arteritis. *Curr Opin Rheumatol* 2004;16:31–7.
- 94 Park JH, Chung JW, Im JG, Kim SK, Park YB, Han MC. Takayasu arteritis: evaluation of mural changes in the aorta and pulmonary artery with CT angiography. *Radiology* 1995;196:89–93.
- 95 Lefebvre C, Rance A, Paul JF *et al.* The role of B-mode ultrasonography and electron beam computed tomography in evaluation of Takayasu's arteritis: a study of 43 patients. *Semin Arthritis Rheum* 2000;30:25–32.
- 96 Schmidt WA, Nerenheim A, Seipelt E, Poehls C, Gromnica-Ihle E. Diagnosis of early Takayasu arteritis with sonography. *Rheumatology* 2002;41:496–502.
- 97 Cantu C, Pineda C, Barinagarrementeria F *et al.* Noninvasive cerebrovascular assessment of Takayasu arteritis. *Stroke* 2000;31:2197–202.
- 98 Andrews J, Al-Nahhas A, Pennell DJ *et al.* Non-invasive imaging in the diagnosis and management of Takayasu's arteritis. *Ann Rheum Dis* 2004;63:995–1000.
- 99 Meller J, Grabbe E, Becker W, Vosschenrich R. Value of F-18 FDG hybrid camera PET and MRI in early Takayasu aortitis. *Eur Radiol* 2003;13:400–5.
- 100 Umekita K, Takajo I, Miyauchi S *et al.* [(18)F]fluorodeoxyglucose positron emission tomography is a useful tool to diagnose the early stage of Takayasu's arteritis and to evaluate the activity of the disease. *Mod Rheumatol* 2006;16:243–7.
- 101 Moreno D, Yuste JR, Rodriguez M, Garcia-Velloso MJ, Prieto J. Positron emission tomography use in the diagnosis and follow up of Takayasu's arteritis. *Ann Rheum Dis* 2005;64:1091–3.
- 102 Belhocine T, Blockmans D, Hustinx R, Vandevivere J, Mortelmans L. Imaging of large vessel vasculitis with (18)FDG PET: illusion or reality? A critical review of the literature data. *Eur J Nucl Med Mol Imaging* 2003;30:1305–13.
- 103 Heggveit HA. Syphilitic aortitis. A clinicopathologic autopsy study of 100 cases, 1950 to 1960. *Circulation* 1964;29:346–55.
- 104 Oz MC, Brener BJ, Buda JA *et al.* A ten-year experience with bacterial aortitis. *J Vasc Surg* 1989;10:439–49.
- 105 Sackier JM, Kelly SB, Clarke D, Rees AJ, Wood CB. Small bowel haemorrhage due to cytomegalovirus vasculitis. *Gut* 1991;32:1419–20.
- 106 Weck KE, Dal Canto AJ, Gould JD *et al.* Murine gamma-herpesvirus 68 causes severe large-vessel arteritis in mice lacking interferon-gamma responsiveness: a new model for virus-induced vascular disease. *Nat Med* 1997;3:1346–53.
- 107 Pantell RH, Goodman BW Jr. Takayasu's arteritis: the relationship with tuberculosis. *Pediatrics* 1981;67:84–8.
- 108 Vargas-Alarcon G, Soto ME, Perez-Hernandez N *et al.* Comparative study of the residues 63 and 67 on the HLA-B molecule in patients with Takayasu's arteritis and tuberculosis. *Cell Biochem Funct* 2008;26:820–3.
- 109 Seko Y, Minota S, Kawasaki A *et al.* Perforin-secreting killer cell infiltration and expression of a 65-kD heat-shock protein in aortic tissue of patients with Takayasu's arteritis. *J Clin Invest* 1994;93:750–8.
- 110 Hoffman GS. Treatment of resistant Takayasu's arteritis. *Rheum Dis Clin North Am* 1995;21:73–80.
- 111 Hoffman GS. Takayasu arteritis: lessons from the American National Institutes of Health experience. *Int J Cardiol* 1996;54(Suppl.):S99–102.
- 112 Daina E, Schieppati A, Remuzzi G. Mycophenolate mofetil for the treatment of Takayasu arteritis: report of three cases. *Ann Intern Med* 1999;130:422–6.
- 113 Hoffman GS, Merkel PA, Brasington RD, Lenschow DJ, Liang P. Anti-tumor necrosis factor therapy in patients with difficult to treat Takayasu arteritis. *Arthritis Rheum* 2004;50:2296–304.
- 114 Tyagi S, Khan AA, Kaul UA, Arora R. Percutaneous transluminal angioplasty for stenosis of the aorta due to aortic arteritis in children. *Pediatr Cardiol* 1999;20:404–10.
- 115 Tyagi S, Sharma VP, Arora R. Stenting of the aorta for recurrent, long stenosis due to Takayasu's arteritis in a child. *Pediatr Cardiol* 1999;20:215–7.
- 116 Giordano JM. Surgical treatment of Takayasu's arteritis. *Int J Cardiol* 2000;75(Suppl. 1):S123–8.
- 117 Liang P, Tan-Ong M, Hoffman GS. Takayasu's arteritis: vascular interventions and outcomes. *J Rheumatol* 2004;31:102–6.
- 118 Liang P, Hoffman GS. Advances in the medical and surgical treatment of Takayasu arteritis. *Curr Opin Rheumatol* 2005;17:16–24.
- 119 Hotchi M. Pathological studies on Takayasu arteritis. *Heart Vessels* 1992;7(Suppl. 7):11–7.