

# Clinical Responses to a Mega-dose of Vitamin D3 in Infants and Toddlers With Vitamin D Deficiency Rickets

by Ashraf T. Soliman,<sup>a</sup> Mohamed El-Dabbagh,<sup>a</sup> Ashraf Adel,<sup>a</sup> Maryam Al Ali,<sup>a</sup> Elsaid M. Aziz Bedair,<sup>b</sup> and Rania K. ElAlaily<sup>a</sup>

<sup>a</sup>*Division of Pediatric Endocrinology, Hamad Medical Centre, Doha, Qatar*

<sup>b</sup>*Division of Radiology, Hamad Medical Centre, Doha, Qatar*

## Summary

**Objectives:** Was to investigate the effect of treatment with an IM injection, a mega dose of vitamin D3 (10 000 IU/kg) on the clinical, biochemical and radiological parameters of 40 rachitic children with vitamin D deficiency (VDD) over a period of 3 months.

**Design:** In this prospective study we evaluated the clinical, biochemical and radiological responses of an IM injection of cholecalciferol (10 000 IU/kg) for 3 months.

**Results:** At presentation, the most frequent manifestations were enlarged wrist joints, hypotonia, irritability, cranial bossing, wide anterior fontanel, bow legs, delayed teething and walking and Harrison's sulcus with chest rosaries. Short stature (length SDS < -2) was recorded in 30% of patients. Craniotabes and hypocalcemic tetany were the least common presentations. In VDD children the most frequent biochemical abnormality was high alkaline phosphatase (ALP) (100%), followed by low phosphate (PO<sub>4</sub>) (75%) and low calcium (Ca) (12.5%). One month after treatment, serum Ca, PO<sub>4</sub> and 25(OH)D concentrations were normal. Three months after the injection, serum level of ALP and parathormone (PTH) decreased to normal. The majority of patients (87.5%) had serum 25(OH)D level ≥ 20 ng/ml, but some (12.5%) had level <20 ng/ml. Hypercalcemia was not recorded in any patient during the 3-month-period. Significant cure of all symptoms and signs related to vitamin D deficiency had been achieved in all children. Leg bowing showed significant improvement in all patients but was still evident in one third. Complete healing of the radiological evidence of rickets was achieved in 95% of all children.

**Conclusion:** An IM injection of a mega dose of cholecalciferol is a safe and effective therapy for treatment of VDD rickets in infants and toddlers with normalization of all the biochemical parameters and healing of radiological manifestations. Measurement of serum 25(OH)D level is highly recommended in all short children with a clear need for a general vitamin D supplementation for all infants and young children in Qatar.

**Key words:** vitamin D3, mega dose, rickets, growth, calcium, phosphate, 25-hydroxy vitamin D, PTH.

## Introduction

Without vitamin D, only 10–15% of dietary calcium and about 60% of phosphorus is absorbed. The active form, 1,25-dihydroxyvitamin D markedly increases the efficiency of intestinal calcium and phosphorus absorption [1–5]. Serum levels of 25-hydroxyvitamin D are directly related to bone mineral density with a maximum density achieved when the 25-hydroxyvitamin D level reached

40 ng/ml or more [6]. Serum levels below 30 ng/ml are associated with a significant decrease in intestinal calcium absorption [5]. In adolescents, children and adults; this is associated with increased parathyroid hormone [7–9]. Parathyroid hormone enhances the tubular reabsorption of calcium and stimulates the kidneys to produce 1,25-dihydroxyvitamin D [1–4]. Parathyroid hormone also activates osteoblasts, which stimulate the transformation of preosteoclasts into mature osteoclasts [1–3]. Osteoclasts dissolve the mineralized collagen matrix in bone, causing osteopenia and osteoporosis and increasing the risk of fracture [10–13]. However, the available evidence is not sufficient to support the use of bone mineral content or parathyroid hormone concentrations in infants and young children as functional outcomes to define deficient or sufficient levels of 25(OH)D.

Correspondence: Prof. Ashraf T. Soliman MD PhD FRCP, Department of Pediatrics, Hamad Medical Centre, P O Box 3050, Doha, Qatar. Tel.: +974-5983874. E-mail: <atsoliman@yahoo.com>.

Children with vitamin D deficiency should be aggressively treated to prevent rickets [1, 14–16]. A cost-effective method of correcting vitamin D deficiency (VDD) and maintaining adequate levels is to give patients a large single dose of vitamin D, followed by a maintenance dose [2, 14–16]. In adults strategies such as having patients take 100 000 IU of vitamin D<sub>3</sub> once every 3 months have been shown to be effective in maintaining 25-hydroxyvitamin D levels at 20 ng/ml or higher and are also effective in reducing the risk of fracture [17].

Higher doses of 100 000–300 000 IU have been administered orally or intramuscularly 6-monthly or once-yearly quite safely without causing hypercalcemia or renal impairment. [18–20]. A Turkish study by Cesur *et al.* [22], compared the effects of oral administration of 150 000, 300 000 and 600 000 IU of vitamin D in 56 infants and toddlers with nutritional vitamin D rickets. The authors reported resolution of the disease process with all three doses, but six of the patients in the 600 000 IU–dose group ( $n=28$ ) and two of the patients in the 300 000 IU–dose group ( $n=28$ ) developed hypercalcemia, although none of these patients had symptoms of hypercalcemia. Therefore, the authors suggested that administering 150 000 IU of vitamin D might be sufficient to treat rickets [21].

The effect of treatment using a single intramuscular mega-doses of vitamin D 3 on the clinical, biochemical and radiological manifestations of infantile rickets has not been well-studied. Intramuscular mega-dose of vitamin D was used in two studies both in children and adults (300 000 U and 600 000 U, respectively) with vitamin D deficiency and reported improvement of biochemical and radiological abnormalities [19, 20].

The objective of this study was to evaluate the clinical, biochemical and radiological response to a single intramuscular large dose of vitamin D 3 (10 000 IU/kg) in infants and toddlers presented with VDD rickets.

### Patients and Methods

In this prospective study 40 infants and toddlers up to and including 3 years of age with nutritional rickets attending the Pediatric outpatient Clinic at Hamad Medical Centre, Doha, Qatar, between January 2007 and December 2007 were studied. Qatar has a sunny hot weather all over the year with no seasonal variation in the incidence of rickets. Mothers breast feeding their infants are advised to give oral vitamin D in the form of drops (400 IU/day) starting on the fourth month of life. However, rickets is still a common disease in Qatar because of lack of exposure to the sun (avoiding the hot humid weather by being indoors, with the majority of mothers completely covered and veiled when outdoors). No

vitamin D supplementation is offered in stable food. All cases of rickets included in this study were referred from primary health care units and Pediatric emergency units to Pediatric Endocrinology Clinic from all over the country.

Inclusion criteria included clinical manifestations of rickets with:

- (1) low serum 25-hydroxyvitamin D [25(OH)D] and
- (2) elevated serum alkaline phosphatase (ALP).

Lab investigations done prior to treatment included:

- (1) serum calcium (Ca) (normal or low),
- (2) serum phosphate (PO<sub>4</sub>) (normal or low),
- (3) serum parathormone (intact molecule) (PTH), and
- (4) X-ray confirmation of rickets at the distal ulnar or femoral epiphysis.

Exclusion criteria included:

- (1) Vitamin D deficiency rickets associated with underlying disease, such as fat malabsorption, liver disease and renal insufficiency. Patients with malnutrition or those receiving total parenteral nutrition are also excluded.
- (2) Vitamin D deficiency secondary to congenital disorders of vitamin D metabolism, including:
  - 1 alpha hydroxylase deficiency (pseudo-vitamin D deficiency rickets)
  - vitamin D receptor defects (hypocalcemic vitamin D resistant rickets)
  - phosphopenic rickets of any etiology (where hypophosphatemia is the primary cause of the rickets, and not due to calcipenic rickets with secondary hyperparathyroidism).

### Ethical approval

Research Ethics Board, Hamad Medical Centre, Doha Qatar approved the protocol of the study and informed consents were obtained from all the parents of the children included in this study.

All patients were subjected to the following:

- (1) Detailed history taking including nutritional intake and exposure to sun.
- (2) Physical examination including clinical manifestations of rickets.
- (3) Anthropometric measurements included weight, length, and head circumference.
- (4) Length standard deviation scores (LSDS), length growth velocity standard deviation scores (GVSDS) and body mass index were calculated prospectively before and at least 6 months or more after treatment. Annualized length velocity (GV) was calculated from length measurements taken 6 months apart. Length was measured with a infant/child height/length measuring board: this board has 130 cm capacity (collapses to 75 cm)

and has 0.1 cm increments, with the sliding head-foot piece. (Shorr Productions; 17802 Shotley Bridge Place; Olney, MD 20832, USA). The standard deviation of the difference between blind triplicate length measurements of 20 children was 0.12 cm. Weight (child lightly clothed) was measured using an electronic scale with Digital Display. Standard deviation scores (SDS) were calculated for length and length velocity (using Tanner, Whitehouse, and Takaishi standards [11, 12] and body mass index (BMI) (using Cole, Freeman, and Preece standards) [13].

- (5) Investigations included: measurement of serum creatinine, bicarbonate, Ca, PO<sub>4</sub>, albumin, ALP, PTH and 25(OH)D concentrations. Serum calcium was corrected for individual variations in serum albumin using the formula: corrected serum calcium (mmol/l) = measured serum calcium (mmol/l) + 0.02 × [40 – measured albumin (g/l)].

During clinic visits the anthropometric parameters were assessed and recorded and the laboratory tests repeated. Serum Ca, PO<sub>4</sub>, ALP concentrations were measured every 4 weeks. Serum PTH and 25(OH)D concentrations were measured after 3 and 6 months.

Children with plasma 25(OH)D levels less than 10 ng/ml were considered to have VDD. The presence or absence of radiological evidence of rickets was determined from routine radiological reports.

The radiographs were read by a single radiologist (EMB) who was blind for the biochemical data of the patients.

PTH and 25(OH)D were measured by radio-immunometric assay using reagents purchased from Mediagnost; Reutlingen, Germany [21]. Intraassay coefficient of variations (CVs) were 6.9% and 5.8%, respectively, and interassay CVs were 8.9% and 8.2%, respectively. Results are expressed as the mean ± SD and analyzed by paired student *t*-test to compare growth parameters and analyte concentrations before vs. after treatment. Correlation and linear regression analysis were used to investigate the relation between variables.

Infants with VDD rickets were treated with a mega-dose of vitamin D<sub>3</sub> (10 000 U/kg, maximum 150 000 U) intramuscularly in the gluteal region [22]. The intramuscular route was selected to avoid the poor compliance to oral medication experienced in our clinics. Parents preferred this mode of therapy for their children vs. daily oral doses of vitamin D. None of the patients received oral vitamin D supplements after the injection. They were not maintained on oral vitamin D after the initial injection for the duration of the study. The diet in Qatar is deficient in vitamin D with no vitamin D added to food products that a toddler might eat apart from the fortified milk formula.

## Results

A total of 40 children were identified with vitamin D deficiency rickets during the study period between the age of 7 and 23 months (mean age 16.1 ± 4.5 months). The majority of infants were exclusively breast-fed (35/40) for more than 6 months. Ninety percent (36/40) of them were still on breast feeding at presentation but only 60% (24/40) were still on breast feeding after 6 months of follow-up. Major clinical manifestations (Table 1) included: enlarged wrist joints, hypotonia, irritability, skull bossing, wide anterior fontanel, bow legs, delayed teething and walking and Harrison's sulcus with chest rosaries. Short stature (length SDS < -2) was recorded in 30% of patients. Craniotabes and hypocalcemic tetany were the least common presentations. Improvement of all these manifestations occurred after treatment. However, leg bowing was still evident in one-third of patients who presented with bow legs.

At presentation hypophosphatemia was present in 75% of whereas hypocalcemia was present in 12.5% of patients. One month after treatment serum PO<sub>4</sub> and Ca concentrations were normal in all patients. After 3 and 6 months of treatment, anthropometrics (Table 2) showed significant improvement. Both the LSDS and annualized GVSIDS increased significantly (3-month-data shown). Circulating concentrations of ALP and PTH decreased significantly to normal values. The circulating 25(OH)D concentrations were >20 ng/ml in the majority of children (87.5%) but was <20 ng/ml in 12.5% of them. Only one child had 25(OH)D level <10 ng/ml. None of the children had hypercalcemia or elevated serum creatinine at any measurement after the injection.

The changes in serum concentrations of 25(OH)D correlated significantly with the changes of serum calcium and negatively with changes of ALP. Changes in the circulating PTH concentrations correlated significantly with changes of ALP and negatively with changes in PO<sub>4</sub> levels (Table 3).

Radiological manifestations including the epiphysis were present in all cases but diaphyseal changes were present in 82.5% at presentation. VDD patients with normal serum calcium and phosphate concentrations had mild broadening of the joint space, mild or no epiphyseal changes and normal metaphyseal calcification and diaphyseal thickness (Fig. 2). VDD patients with low serum phosphate but normal serum calcium concentrations had irregular/faint (fraying) line of ossification at metaphyseal front with excessive osteoid (cupping) and some metaphyseal and diaphyseal demineralization. VDD patients with low phosphate and calcium concentrations (dysadapted) had absent line of ossification at metaphyseal front, excessive osteoid deposition (very wide wrist space) with cupping, marked decalcification of the metaphysis and diaphysis of long bones (very thin cortex) with subperiosteal erosion of the shafts (Fig. 4).

TABLE 1  
Clinical data before and 6 months after vitamin D3 injection

	Data (%)	
	Before	After
Wide ant. Fontanel	55	5
Craniotables	2.5	0
Skull bossing	57.5	2.5
Large head	25	2.5
Delayed teething	37.5	2.5
Delayed walking	50	5
Chest rosaries	50	2.5
Harrison Sulcus	82.5	2.5
Hypotonia	62.5	0
Abd. Distention	42.5	7.5
Bow legs	70	25
Wide wrist joint	90	15
Marfan's sign	75	7.5
Sweating	57.5	2.5
Irritability	55	2.5
Tetany/seizure	10	0
Upper/Lower respiratory infections	45	15
Short stature (LSDS < -2)	30	0
Radiologic epiphyseal changes	100	5
Radiologic diaphyseal changes	82.5	2.5
Breast fed	90	60

All the clinical variables after treatment were significantly different vs. before treatment.

TABLE 2  
Anthropometric and Biochemical data of rachitic children before vs. after treatment with vitamin D

	Mean (SD)	
	Before	After
Age (month)	16.14 (4.5)	22.1 (4.4)
L SDS	-1.48 (0.62)	-0.95 (0.35)
GV SDS	-1.35 (0.45)	1.9* (0.56)
25(OH)D (ng/ml)	6.24 (4.91)	28.19* (8.73)
PTH (pg/ml)	250* (154.2)	42 (18.07)
ALP (U/l)	1099* (568)	421 (187)
Ca (mmol/l)	2.19 (0.19)	2.4* (0.14)
PO <sub>4</sub> (mmol l)	1.1 (0.39)	1.92* (0.21)

Anthropometric data after 6 months of injecting the mega dose of vitamin D. Biochemical data after 3 months of injecting the mega dose of vitamin D. L SDS, length standard deviation score; GV, Growth velocity; Ca, calcium; PO<sub>4</sub>, phosphate; ALP, alkaline phosphatase concentrations in serum; Vit D, 25(OH)D; PTH, parathormone; IGF-I, insulin-like growth factor-I concentrations in serum.

\* =  $P < 0.05$  after vs before treatment

TABLE 3  
Correlations between the changes (D) that occurred in the different biochemical variables after treatment

	D-Calcium	D-PO <sub>4</sub>	D- ALP	D-PTH	D-25(OH)D
D-Calcium	1	0.256*	-0.156	0.016	0.217*
D-PO <sub>4</sub>	0.256*	1	0.276*	-0.366*	0.067
D- ALP	-0.156	-0.276*	1	0.32*	-0.277*
D-PTH	0.016	-0.366	0.32*	1	0.027
D-25(OH)D	0.217	0.067	-0.277*	0.027	1

D-: the change of the variable after vs. before treatment.

\*  $P = 0.05$ .

Three months after the injection both the epiphyseal and diaphyseal changes were normalized in the majority of cases (95%). Six months after the injection, 25(OH)D decreased significantly in 39 of the 40 children to a level below 20 ng/ml. Four out of the 40 had serum 25(OH)D level <10 ng/ml (Fig. 1).

## Discussion

Ultraviolet radiation and/or dietary vitamin D are required to prevent rickets in children. Qatar is a sunny country all over the year however, even with this amount of sunshine, vitamin D deficiency still prevalent, for various reasons. Children are born with low vitamin D stores because mothers are deficient in vitamin D (completely veiled) resulting in poor materno-fetal transfer of vitamin D during pregnancy. They receive little or no sun exposure because they are kept in doors to avoid the prevalent hot weather, their darkly pigmented skin decreases vitamin D synthesis, and their inadequate dietary intake of vitamin D. Breast milk is a poor source of dietary vitamin D, especially when the lactating woman is vitamin D deficient [22-28].

We have presented 40 cases of vitamin D deficiency in children managed by hospital pediatric department over a 1-year period. Vitamin D deficiency remains the commonest cause of newly presenting hypocalcaemia in our pediatric



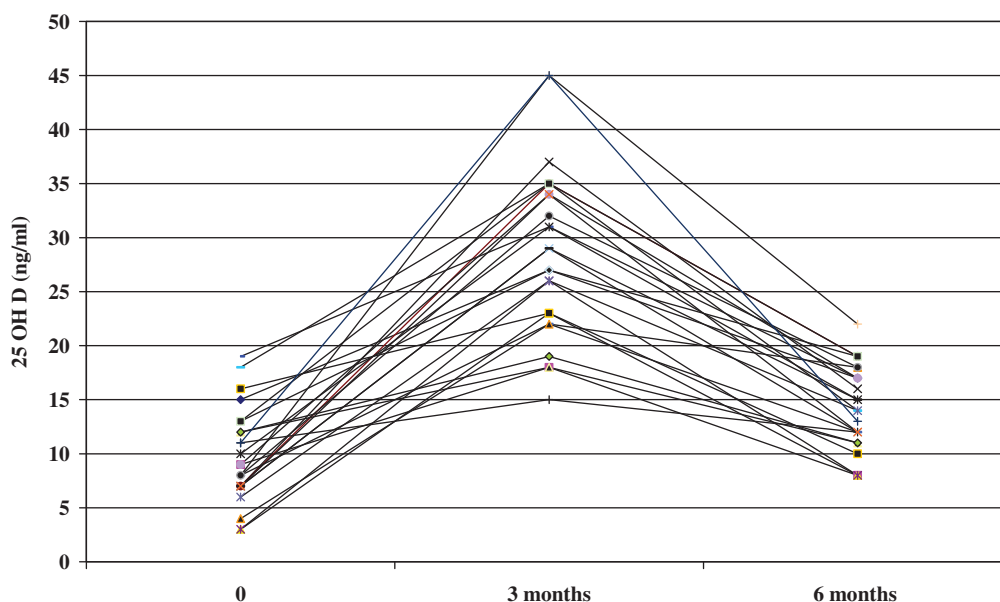


FIG. 1. Serum 25(OH)D before vs. after injection of a mega dose of vitamin D3 (10 000 U/kg). None of the children was on oral vitamin D after the injection.

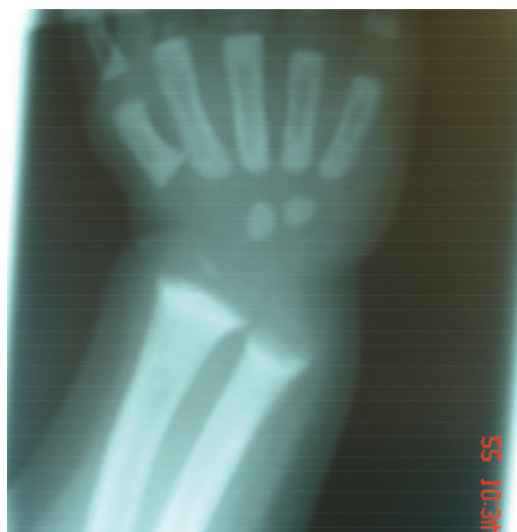

FIG. 2. Normal serum calcium and phosphate concentrations and high PTH and alkaline phosphatase concentrations. Near normal epiphyseal and metaphyseal calcification without cupping or fraying with mild broadening of the joint space. Normal diaphyseal thickness.

department after the neonatal period. However, hypocalcemia was less prevalent (12.5%) in our rachitic children compared to hypophosphatemia (75%). This is expected because of the protective

effect of secondary hyperparathyroidism on maintaining serum calcium concentration in the normal range. In a VDD state, only 10–15% of dietary calcium and 50–60% of dietary phosphorus are absorbed. The poor absorption of calcium causes a decrease in serum-ionized calcium levels. This is immediately recognized by the calcium sensor in the parathyroid glands, resulting in an increase in the secretion of parathyroid hormone (PTH). PTH conserves calcium by increasing tubular reabsorption of calcium in both the proximal and distal convoluted tubules. However, PTH enhances the expression of Receptor Activator for Nuclear  $\kappa$  B Ligand (RANKL) on osteoblasts to increase the production of mature osteoclasts to mobilize calcium stores from the skeleton. PTH also decreases phosphorus reabsorption in the kidney, causing loss of phosphorus into the urine and hypophosphatemia [1, 29–32].

Although serum calcium level is usually normal in the majority of VDD with rickets, it is the low serum phosphorus that leads to an inadequate calcium-phosphorus product, which is necessary to mineralize the osteoid laid down by osteoblasts [1, 29–32]. This explains the florid appearance of radiological rachitic manifestations in our VDD patients with hypophosphatemia vs. those with normophosphatemia. The secondary hyperparathyroidism stimulates the kidneys to produce 1,25(OH)<sub>2</sub>D. Only when the calcium stores in the skeleton are totally depleted will the infant or child become hypocalcemic. This is evident

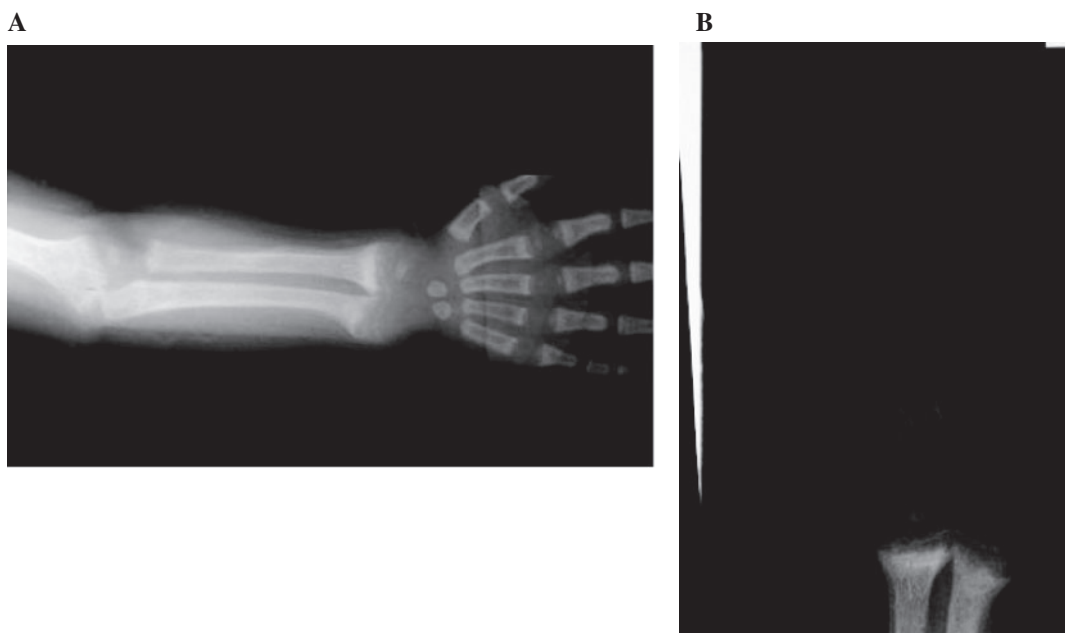


FIG. 3. Normal serum calcium, low serum phosphate concentrations and high PTH and ALP. Clear line of ossification at metaphyseal front with irregular/faint (freying) and excessive osteoid (cupping).

in our patients with hypocalcemia, who had more severe osteoporotic changes in the diaphysis compared with normocalcemic patients.

Thirty percent of our rachitic children were significantly short (LSDS  $< -2$ ) at presentation, with slow growth velocity. Many factors can contribute to impaired linear growth in these children including: (i) defective mineralization and increased size of the hypertrophic layer of the growth plate with the deposition of excessive osteoid (100% of patients), (ii) deformities of the long bones of the lower limbs with bowing of both femur and tibia due to weakening of the shafts (70% of our patients), (iii) hypotonia (of the back muscles and ligaments with tendency to postural kyphosis or kyphoscoliosis) (62.5% of our patients) (iv) possible effect of vitamin D deficiency on growth hormone (GH)/insulin like growth factor I (IGF-I) axis [28] and (v) repeated infections (45% of our patients) that might be due to the lack of vitamin D effect on immune system with subsequent effect on the nutritional status of the infant. Marked improvement of linear growth after therapy implements the necessity to investigate vitamin D status in every short child in countries where vitamin D deficiency is still prevalent. Some data suggest that in infants and children VDD may induce an adaptive state associated with slow growth and decreased metabolic demands for Ca before the appearance of clinical rickets [3, 11, 13].

Following intramuscular cholecalciferol injection, serum 25(OH)D levels increased in all participants and after 3 months of the injection it was  $t$  was  $>20$  ng/ml in 87.5% of patients. Serum Ca and  $PO_4$  concentrations were normal 1 month after the injection. Three months after the injection, all biochemical and radiological manifestations were normalized. Clinical improvement was complete in all the patients with a residual degree of bow-legs in a minority. None of the patients had hypercalcemia or increased serum creatinine at any time after injecting vitamin D. However, the significant decrease of circulating 25(OH)D level 6 months after the injection proved that this dose may not be enough to maintain normal level of 25(OH)D in these children for 6 months.

### Conclusion

An IM injection of a mega dose of cholecalciferol is a safe and effective therapy for treatment of rachitic infants and toddlers with VDD for 3 months had normalization of all the biochemical parameters and healing of radiological manifestations. Measurement of serum 25(OH)D level is highly recommended in the screening of all short children; especially during the first 3 years of life, in countries where rickets is still prevalent. There is a clear need for a general

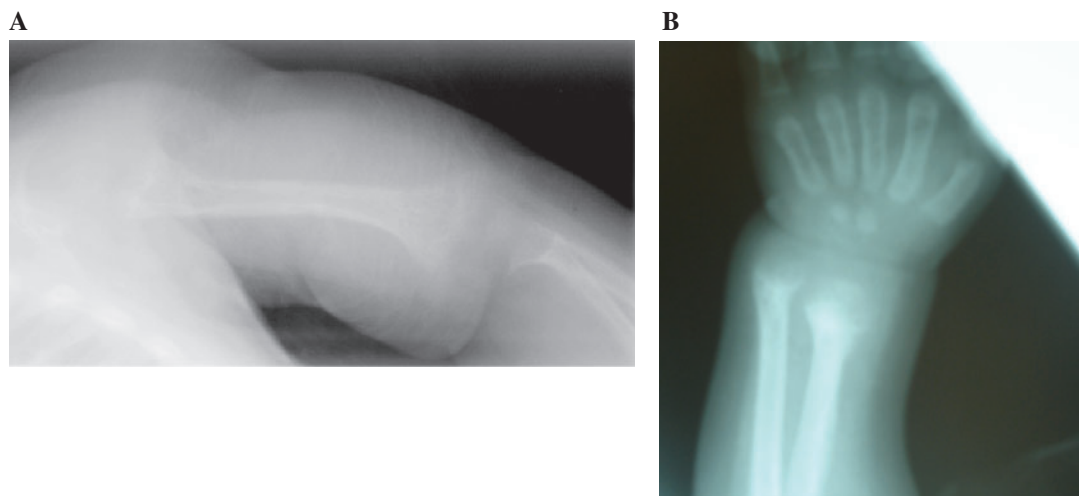


FIG. 4. Two different patients with low serum calcium and phosphate concentrations and high PTH and ALP concentrations. Absent line of ossification at metaphyseal front, excessive osteoid deposition (very wide wrist space) with cupping, decalcification of the metaphysis and shafts of long bones (very thin cortex) with subperiosteal erosion of the shafts.

vitamin D supplementation for all infants and children in Qatar. In addition supplementing children food with vitamin D appears to be useful means of prevention of rickets in Qatar.

### References

- Holick MF. Resurrection of vitamin D deficiency and rickets. *J Clin Invest* 2006;116:2062–72.
- Holick MF, Garabedian M. Vitamin D: photobiology, metabolism, mechanism of action, and clinical applications. In: Favus MJ (ed). *Primer on the Metabolic Bone Diseases and Disorders of Mineral Metabolism*. 6th edn. Washington, DC: American Society for Bone and Mineral Research, 2006, 129–37.
- Bouillon R. Vitamin D: from photosynthesis, metabolism, and action to clinical applications. In: DeGroot LJ, Jameson JL (eds). *Endocrinology*. Philadelphia: W.B. Saunders, 2001, 1009–28.
- DeLuca HF. Overview of general physiologic features and functions of vitamin D. *Am J Clin Nutr* 2004;80(Suppl):1689S–96S.
- Heaney RP, Dowell MS, Hale CA, Bendich A. Calcium absorption varies within the reference range for serum 25-hydroxyvitamin D. *J Am Coll Nutr* 2003;22:142–6.
- Bischoff-Ferrari HA, Giovannucci E, Willett WC, *et al.* Estimation of optimal serum concentrations of 25-hydroxyvitamin D for multiple health outcomes. *Am J Clin Nutr* 2006;84:18–28. [Erratum, *Am J Clin Nutr* 2006;84:1253].
- Pettifor JM. Rickets and vitamin D deficiency in children and adolescents. *Endocrinol Metab Clin North Am* 2005;34:537–53, vii.
- Chapuy MC, Preziosi P, Maamer M, *et al.* Prevalence of vitamin D insufficiency in an adult normal population. *Osteoporos Int* 1997;7:439–43.
- Holick MF, Siris ES, Binkley N, *et al.* Prevalence of vitamin D inadequacy among postmenopausal North American women receiving osteoporosis therapy. *J Clin Endocrinol Metab* 2005;90:3215–224.
- Boonen S, Bischoff-Ferrari HA, Cooper C, *et al.* Addressing the musculoskeletal components of fracture risk with calcium and vitamin D: a review of the evidence. *Calcif Tissue Int* 2006;78:257–70.
- Lips P. Vitamin D deficiency and secondary hyperparathyroidism in the elderly: consequences for bone loss and fractures and therapeutic implications. *Endocr Rev* 2001;22:477–501.
- Bakhtiyarova S, Lesnyak O, Kyznesova N, *et al.* Vitamin D status among patients with hip fracture and elderly control subjects in Yekaterinburg, Russia. *Osteoporos Int* 2006;17:441–46.
- McKenna MJ. Differences in vitamin D status between countries in young adults and the elderly. *Am J Med* 1992;93:69–77.
- Shah BR, Finberg L. Single-dose therapy for nutritional vitamin D-deficiency rickets: a preferred method. *J Pediatr* 1994;125:487–90.
- Thacher TD, Fischer PR, Pettifor JM, *et al.* A comparison of calcium, vitamin D, or both for nutritional rickets in Nigerian children. *N Engl J Med* 1999;341:563–8.
- Markestad T, Halvorsen S, Halvorsen KS, *et al.* Plasma concentrations of vitamin D metabolites before and during treatment of vitamin D deficiency rickets in children. *Acta Padiatr Scand* 1984;73:225–31.
- Trivedi DP, Doll R, Khaw KT. Effect of four monthly oral vitamin D<sub>3</sub> (cholecalciferol) supplementation on fractures and mortality in men and women living in the community: randomised double blind controlled trial. *Br Med J* 2003;326:469–75.
- Vieth R. Vitamin D supplementation, 25-hydroxyvitamin D concentrations, and safety. *Am J Clin Nutr* 1999;69:842–56.

19. Khaw KT, Scragg R, Murphy S. Single-dose cholecalciferol suppresses the winter increase in parathyroid hormone concentrations in healthy older men and women. *Am J Clin Nutr* 1994;59:1040–4.
20. Wu F, Staykova T, Horne A, *et al.* Efficacy of an oral, 10-day course of high-dose calciferol in correcting vitamin D deficiency. *NZ J Med* 2003;116:536–9.
21. Hollis B. Measuring 25-hydroxyvitamin D in a clinical environment: challenges and needs. *Am J Clin Nutr* 2008;88(Suppl):507S–10S.
22. Cesur Y, Caksen H, Gundem A, *et al.* Comparison of low and high dose of vitamin D treatment in nutritional vitamin D deficiency rickets. *J Pediatr Endocrinol Metab* 2003;16:1105–9.
23. Kutluk G, Cetinkaya F, Basak M. Comparisons of oral calcium, high dose vitamin D and a combination of these in the treatment of nutritional rickets in children. *J Tropical Pediatr* 2002;48:351–3.
24. Terrence H Diamond, Kenneth W Ho, Peter G Rohl, Matthew Meerkin. Annual intramuscular injection of a megadose of cholecalciferol for treatment of vitamin D deficiency: efficacy and safety data. *MJA* 2005; 183:10–2.
25. Bachrach S, Fisher J, Parks JS. An outbreak of vitamin D deficiency rickets in a susceptible population. *Pediatrics* 1979;64:871–7.
26. Welch TR, Bergstrom WH, Tsang RC. Vitamin D deficient rickets: the reemergence of a once conquered disease. *J Pediatr* 2000;137:143–5.
27. Siam A, Rahim M, Hammoudeh M, *et al.* Vitamin-D deficiency in Qatar: APLAR J Rheumatol, 2006;(Suppl 1):A32–3, P032.
28. Soliman AT, Al Khalaf F, Alhemaidi N, *et al.* Linear growth in relation to the circulating concentrations of insulin-like growth factor I, parathyroid hormone, and 25-hydroxy vitamin D in children with nutritional rickets before and after treatment: endocrine adaptation to vitamin D deficiency. *Metabolism* 2008;57:95–102.
29. Eid M. Osteomalacia as a contributing factor in fracture of the femoral neck in the elderly in Qatar. *Clin Orthop* 1978;132:129–35.
30. Binet A, Kooh SW. Persistence of vitamin D-deficiency in Toronto in the 1990s. *Can J Public Health* 1996;87:227–30.
31. Lo CW, Paris PW, Holick MF. Indian and Pakistani immigrants have the same capacity as Caucasian to produce vitamin D in response to ultraviolet irradiation. *Am J Clin Nutr* 1986;44:683–5.
32. DeLuca HF. Overview of general physiologic features and functions of vitamin D. *Am. J. Clin. Nutr* 2004;80(Suppl.): 1689S–96S.