

CASE REPORT

Meningioma presenting as bilateral parkinsonism

VEDAMURTHY ADHIYAMAN, JOLYON MEARA

University Department of Geriatric Medicine (North Wales), Glan Clwyd District Hospital, Rhyl, Denbighshire LL18 5UJ, UK

Address correspondence to: V. Adhiyaman. Fax: (+44) 1745 534668. Email: adhiyamanv@yahoo.co.uk

Abstract

Background: a 63-year-old woman presented with an 18-year history of tremor, rigidity and akinesia. There was no response to treatment with either levodopa or pergolide. Later a focal neurological deficit developed, which led to a diagnosis of fronto-parietal meningioma.

Outcome: surgical excision of the meningioma abolished the parkinsonism.

Conclusion: cerebral tumour is an uncommon cause of parkinsonism. Symptoms probably occur due to compression and distortion of the basal ganglia and nigrostriatal pathway. Diagnosis of the underlying pathology can be delayed by this presentation. Since complete recovery is possible parkinsonian patients with atypical symptoms, poor response to dopaminergic drugs, and focal neurological signs should undergo neuroimaging.

Keywords: *parkinsonian disorders, meningioma*

Presentation

Cerebral tumour is an uncommon but easily overlooked cause of parkinsonism. We present a case of meningioma presenting as parkinsonism in a 63-year-old woman. The patient first noticed a rest tremor of the left hand at the age of 45. The tremor gradually worsened over the next 5 years, leading to a hospital referral. On examination there was a pill-rolling rest tremor of the left hand, akinesia and rigidity at the wrist, which led to a diagnosis of probable Parkinson's disease. There was no improvement with orphenadrine hydrochloride, amantidine or levodopa.

She was re-referred to a movement disorder clinic at the age of 61 for the same problem. Examination revealed bilateral upper limb tremors, rigidity and akinesia, more marked on the left side. Tremor was the dominant feature. There was no benefit from pergolide at a dose of 750 µg per day. Higher doses were not tolerated due to nausea and dizziness.

A few months later she collapsed due to sudden weakness of the left arm and leg. A CT brain scan revealed a 4 cm densely calcified lesion with surrounding oedema in the right fronto-parietal region with some mass effect (Figure 1). The tumour was surgically excised. Post-operatively the left hemiparesis persisted

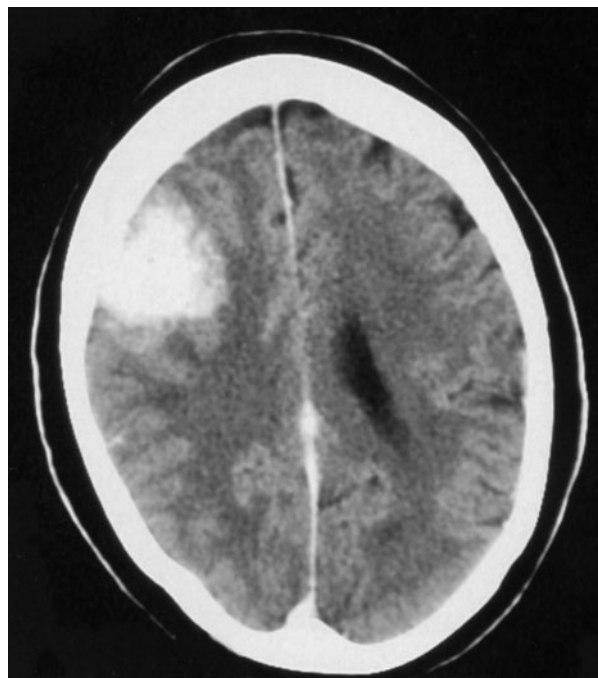


Figure 1. A non-contrast CT showing a right fronto-parietal tumour causing mass effect and slight midline shift.

and recovery was complicated by focal seizures. Tremor and akinesia resolved completely. Histopathological examination confirmed the tumour to be a meningioma. The lady made a near full recovery after a programme of rehabilitation.

Discussion

Parkinsonian symptoms due to tumours directly involving the basal ganglia and due to supratentorial tumours sparing the basal ganglia have both been described [1–5]. Bilateral parkinsonism has been less commonly reported than unilateral contralesional parkinsonism [6]. Mechanical compression and distortion of the basal ganglia and nigrostriatal pathway, tumour infiltration and impaired tissue perfusion due to tumour oedema have been proposed as causative mechanisms [1, 7]. None of the published cases have reported a good response to levodopa.

Although parkinsonism can occur with any brain tumour, meningioma located at the sphenoid ridge or at the frontal convexity is the most commonly associated tumour [8]. Other tumours presenting as parkinsonism include primary brain lymphoma, astrocytoma, epidermoid, oligodendroglioma, and glioblastoma [5, 9, 10]. In a large series of 907 patients with supratentorial tumours, 0.3% of the patients were found to have parkinsonism and rest tremor. In the majority of these patients parkinsonism preceded other symptoms, leading to a delay in the diagnosis of intracranial neoplasm. Half of these patients made a complete recovery after surgical excision [5]. Interestingly a patient with levodopa responsive parkinsonism associated with a low-grade astrocytoma was subsequently found to have idiopathic Parkinson's disease 9 years later based on SPECT scanning [11, 12].

Meningiomas account for 20% of all brain tumours and arise from cells of the pia-arachnoid either in the cranium or in the spinal canal. Common sites include the midline along the falx cerebri and the lateral cerebral convexity, the olfactory groove, along the sphenoid ridge, the tuberculum sellae, foramen magnum and tentorium of the cerebellum. Meningiomas are often incidental findings on neuroimaging or at post-mortem. Symptomatic meningiomas usually present in the fifth or the sixth decade, and as these are slow growing tumours it can take years before neurological symptoms develop due to compression and irritation. Parasagittal and frontal tumours may produce seizures, spastic paraparesis, gait disorders and urinary incontinence.

In our patient compression of the right basal ganglia by the fronto-parietal meningioma was the cause for the initial left sided parkinsonian symptoms. The mass effect due to the gradual growth of the tumour and associated oedema led to an increase in intra-cranial pressure and midline shift. This resulted in compression and distortion of the left basal ganglia, which explains

the progression of the symptoms to the right hand, mimicking the natural course of Parkinson's disease. Neuroimaging has a place in the assessment of patients with parkinsonism particularly if symptoms are atypical, the response to anti-parkinson medications is poor, and there are focal neurological signs. Early recognition of an intracranial tumour as a cause of parkinsonism is important to prevent further neurological deficit.

Key points

- Cerebral tumour is an uncommon cause of parkinsonism.
 - Meningiomas are the most commonly associated tumours.
 - Isolated extra-pyramidal symptoms may lead to a delay in diagnosis.
 - Most patients make a good recovery following surgical excision of the meningioma.
 - Neuroimaging should be considered in patients with atypical parkinsonian symptoms, with a poor response to anti-parkinson medications and in the presence of focal neurological signs.
-

References

1. Polyzoidis KS, McQueen JD, Rajput AH, MacFadyen DJ. Parkinsonism as a manifestation of brain tumour. *Surg Neurol* 1985; 23: 59–63.
2. Lesoin F, Thomas CE 3rd, Montagne B, Destee A, Jomin M. Meningioma of the lesser sphenoid wing presenting like Parkinson's disease. *Surg Neurol* 1985; 23: 452–3.
3. Barbosa ER, Teixeira MJ, Chaves CJ, Scaff M. Parkinson disease associated to a brain tumour: a case report. [Portuguese]. *Arq Neuropsiquiatr* 1991; 49: 338–41.
4. Saleem SM, Shah S, Kirmani A, Dhobi GN. An unusual case of parkinsonism secondary to right parasagittal meningioma. *Neurol India* 2000; 48: 190–1.
5. Krauss JK, Paduch TH, Munding F, Seeger W. Parkinsonism and rest tremor secondary to supratentorial tumours sparing the basal ganglia. *Acta Neurochir* 1995; 133: 22–9.
6. Pall HS, Williams A. 74 year old lady who developed bilateral parkinsonism secondary to an intrinsic brain tumour. *J Neurol Neurosurg Psychiatry* 1987; 50: 1386–7.
7. Leenders KL, Findley LJ, Cleeves L. PET before and after surgery for tumour-induced parkinsonism. *Neurology* 1986; 36: 1074–8.
8. Kondo T. Brain tumour and parkinsonism. *Nippon Rinsho* 1997; 55: 118–22.
9. Sanchez-Guerra M, Cerezal L, Leno C, Diez C, Figols J, Berciano J. Primary brain lymphoma presenting as Parkinson's disease. *Neuroradiology* 2001; 43: 36–40.

V. Adhiyaman, J. Meara

10. Kulali A, Tugtekin M, Utkur Y, Erkurt S. Ipsilateral hemiparkinsonism secondary to an astrocytoma. *J Neurol Neurosurg Psychiatry* 1991; 54: 653.

11. Straube A, Sigel K. Parkinsonian syndrome caused by a tumour of the left supplementary motor area. *J Neurol Neurosurg Psychiatry* 1988; 51: 730–1.

12. Kupsch A, Pogarell O, Schwarz J *et al.* Parkinson's disease and tumour in the supplementary motor area: a re-evaluation. *J Neurol Neurosurg Psychiatry* 1997; 63: 811–2.

Received 11 November 2002; accepted in revised form 28 November 2002