

Beyond “Cirrhosis”

A Proposal From the International Liver Pathology Study Group

Prodromos Hytioglou, MD,¹ Dale C. Snover, MD,² Venancio Alves, MD,³ Charles Balabaud, MD,⁴ Prithi S. Bhathal, MD,⁵ Paulette Bioulac-Sage, MD,⁶ James M. Crawford, MD,⁷ Amar P. Dhillon, MD,⁸ Linda Ferrell, MD,⁹ Maria Guido, MD,¹⁰ Yasuni Nakanuma, MD,¹¹ Valerie Paradis, MD,¹² Alberto Quaglia, MD,¹³ Neil D. Theise, MD,¹⁴ Swan N. Thung, MD,¹⁵ Wilson M.S. Tsui, MD,¹⁶ and Dirk J. van Leeuwen, MD¹⁷

Key Words: Cirrhosis; Classification; Disease; Liver; Nomenclature; Regression; Stage

DOI: 10.1309/AJCP2T2OHTAPBTMP

Upon completion of this activity you will be able to:

- define advanced-stage chronic liver diseases as dynamic conditions, characterized by remodeling of the hepatic pathologic changes.
- discuss the relevance of various approaches in assessing advanced chronic liver diseases, such as liver biopsy, hepatic venous pressure gradient, and transient elastography.
- compare the benefits of the contemporary clinicopathologic approach vs the traditional approach of assessment of the presence or absence of cirrhosis, in managing patients with advanced-stage chronic liver disease.

The ASCP is accredited by the Accreditation Council for Continuing Medical Education to provide continuing medical education for physicians. The ASCP designates this journal-based CME activity for a maximum of 1 *AMA PRA Category 1 Credit*[™] per article. Physicians should claim only the credit commensurate with the extent of their participation in the activity. This activity qualifies as an American Board of Pathology Maintenance of Certification Part II Self-Assessment Module.

The authors of this article and the planning committee members and staff have no relevant financial relationships with commercial interests to disclose. Questions appear on p 156. Exam is located at www.ascp.org/ajcpeme.

Abstract

“Cirrhosis” is a morphologic term that has been used for almost 200 years to denote the end stage of a variety of chronic liver diseases. The term implies a condition with adverse prognosis due to the well-known complications of portal hypertension, hepatocellular carcinoma, and liver failure. However, recent advances in the diagnosis and treatment of chronic liver diseases have changed the natural history of cirrhosis significantly. This consensus document by the International Liver Pathology Study Group challenges the usefulness of the word cirrhosis in modern medicine and suggests that this is an appropriate time to consider discontinuing the use of this term. The role of pathologists should evolve to the diagnosis of advanced stage of chronic liver disease, with emphasis on etiology, grade of activity, features suggestive of progression or regression, presence of other diseases, and risk factors for malignancy, within the perspective of an integrated clinicopathologic assessment.

Definition and Current Understanding of Cirrhosis

“Cirrhosis” derives from the Greek word κίρρος, meaning tawny, and was initially used to describe the gross (tawny, nodular, and firm) and, afterwards, the microscopic appearance of the chronically diseased and physiologically burned out and dysfunctional liver.^{1,2} For almost 2 centuries, the emphasis was placed on the irreversible, “end-stage” nature of these livers; etiology was not considered very important because there was no cure, and survival was usually short. In 1977, an international panel, sponsored by the World Health Organization, defined cirrhosis as “a diffuse process characterized by fibrosis and the conversion of normal liver architecture into structurally abnormal nodules.”³ The panel also noted that “cirrhosis is a chronic progressive condition that results in liver cell failure and portal hypertension.” Furthermore, the panel stated that vascular abnormalities were a very important feature of cirrhosis. The latter include thrombosis, obliteration, and recanalization of veins; formation of arteriovenous shunts; and “capillarization” of sinusoids.⁴

The natural history of cirrhosis has changed significantly in recent years, as therapeutic advances in the field of chronic liver diseases allow patients with cirrhosis to survive long-term, often with their conditions improving clinically and histologically, in the course of time. Therefore, it is becoming obvious that, by modern standards, all cases of cirrhosis do not inevitably “result in liver cell failure and portal hypertension.” Furthermore, the possibility of regression of cirrhosis has been considered⁵ and is now thought likely by several

investigators. From a practical viewpoint, a need to redefine cirrhosis as a pathologic condition that evolves through more than one stage has been acknowledged.⁶

Using a morphology-based unitary term, such as cirrhosis, for a part of the evolutionary spectrum of a variety of diseases is unusual in modern medicine because disease classification, diagnosis, and treatment are primarily based on etiology. Indeed, it is difficult to find any term referring to a pathologic condition of other organs that is conceptually similar to cirrhosis of the liver. Furthermore, the concept of cirrhosis as an end-stage and irreversible process is so widely known to the public that the implication of the word itself is often problematic.

Recent discussions by the International Liver Pathology Study Group (San Francisco, CA, 2009, and London, England, 2010) have suggested that this is an appropriate time to consider discontinuing use of the word cirrhosis. The role of pathologists should evolve to the diagnosis of advanced stage of chronic liver disease, with emphasis on etiology, grade of activity, features suggestive of progression or regression, presence of other diseases, and risk factors for malignancy, within the perspective of an integrated clinicopathologic assessment. The current article elaborates on this suggestion.

Cirrhosis and Cirrheses

Cirrhosis is a heterogeneous condition with differing clinical manifestations and prognosis depending on the etiology and the severity of hepatic architectural distortion. The main causes of cirrhosis include chronic hepatitis B, chronic hepatitis C, autoimmune hepatitis, fatty liver diseases, chronic biliary diseases, and several inherited metabolic disorders.^{4,7} Each one of these diseases has a relatively well-understood natural history and may cause significant liver injury, accompanied over time by regeneration, scarring, and vascular alterations, leading to an advanced stage characterized by nodularity and fibrous septation. Many of them now have specific therapies not available in the past.

Different etiologies cause different patterns of scarring and regeneration and have different rates of progression. Furthermore, within each disease entity, the magnitude of architectural distortion and the resultant clinical implications vary in severity among patients and over time. The clinical spectrum of cirrhosis is indeed wide, ranging from patients who feel no burden in their regular daily activities (a typical scenario with cirrhosis secondary to nonalcoholic steatohepatitis, for example) to severely ill patients with complications such as portal hypertension, hepatic encephalopathy, and hepatocellular carcinoma. On the other hand, there are similarities among cirrhotic livers of different etiologies extending all the way to the cellular level, reflecting common pathogenic

mechanisms: stellate cells and fibroblasts are the effectors of fibrogenesis, while parenchymal regeneration relies on hepatocytes and hepatic stem/progenitor cells.^{8,9}

Until recently, fibrosis occurring in chronic liver diseases was considered a relentless process that could sometimes be halted but would not regress. However, modern treatment of chronic liver diseases has made clear that hepatic fibrosis can regress over time. Depending on the type of disease, successful treatment may involve eradication of a virus (eg, chronic hepatitis C)¹⁰; control of the inflammatory process following inhibition of viral replication (eg, chronic hepatitis B)¹¹ or suppression of autoimmunity (autoimmune hepatitis)¹²; and removal of the offending agent (eg, alcohol, iron¹³). Regression of fibrosis may take place in precirrhotic and cirrhotic livers.⁵

In recently published series regarding patients with chronic viral hepatitis undergoing treatment, there are subsets of patients with cirrhosis who show significant histologic improvement (in necroinflammatory activity and fibrosis) in repeated biopsies.^{10,11,14} Although regression of cirrhosis may indeed occur in some patients,¹⁵⁻¹⁷ evolution to incomplete septal cirrhosis (a condition that, despite its name, does not meet the criteria for the traditional definition of cirrhosis) has been suggested as a likely explanation for others.⁵ In such cases, incomplete septal cirrhosis may result from thinning and loss of the fibrous septa surrounding the nodules (ie, regression of fibrosis), with persistence of at least some degree of the vascular changes characteristic of cirrhosis (eg, arteriovenous shunts, portal vein branch obliteration). Making this diagnosis in any particular case may have significant clinical implications, as patients with incomplete septal cirrhosis may not require orthotopic liver transplantation, as many patients with cirrhosis do, but may instead benefit from a vascular shunting procedure.

A Contemporary Approach for the Assessment of Advanced Chronic Liver Diseases

At present, there is increasing recognition of the need for a pathophysiologic staging of cirrhosis that will incorporate the clinical, histologic, and hemodynamic findings of each particular patient.⁶ For example, the hepatic venous pressure gradient (HVPG) is emerging as an important parameter of a proposed classification⁶ because HVPG levels have a good correlation with the complications of portal hypertension. As HVPG measurements are not widely available, surrogate histologic markers of this parameter would be desirable. For example, there is evidence that small parenchymal nodules and thick fibrous septa are associated with increased HVPG.^{18,19} Therefore, the thickness of the fibrous septa has been suggested as a tool to stage advanced chronic liver

disease.^{18,20} Furthermore, a significant correlation between HVPG and collagen proportionate area, a novel marker of fibrosis that can be assessed in histologic material by image analysis, has been found.²¹ In addition, liver stiffness measurement, assessed by transient elastography, a noninvasive method, has been found to be in excellent correlation with HVPG values up to the level of 10 to 12 mm Hg in patients with chronic hepatitis C.^{22,23}

We consider this pathophysiologic approach entirely appropriate for the present, but we suggest that it is applied to each advanced chronic liver disease independent of the term cirrhosis. For example, a pathologist examining a liver biopsy specimen from a patient with chronic hepatitis B may simply state that the patient has chronic hepatitis B of advanced stage (eg, corresponding to the descriptions for stages 5 and 6 of the Ishak staging system²⁴), without using the word cirrhosis

Figure 1. The pathology report should also include the grade of necroinflammatory activity and a statement regarding risk factors for hepatocellular carcinoma (such as small cell change and large cell change), if present. This information should be sufficient for providing appropriate treatment and follow-up. Whether the advanced stage seen in the biopsy material actually represents end-stage liver disease will be determined by clinicopathologic correlation and response to treatment. Treatment adjustments can then be decided on the basis of the clinical course and subsequent biopsies, as needed.

This proposal emphasizes the etiology of liver disease in each case and has the advantage that each disease process is addressed without the negative connotations of irreversibility and end-stage nature that have traditionally been associated with the word cirrhosis. Furthermore, our approach acknowledges the fact that histologic examination alone is insufficient to document liver disease that is likely to be irreversible, while clinical assessment of advanced chronic liver disease without histologic support may not differentiate between the various causes of portal hypertension (eg, advanced chronic liver disease due to virus or steatohepatitis vs hepatoportal sclerosis). In addition, this etiology-based approach may facilitate the development of new screening strategies for early detection of hepatocellular carcinoma because there are significant differences in the incidence of this neoplasm among chronic hepatic diseases of differing etiologies.

In some cases of advanced chronic liver disease, histologic features indicative of fibrosis resorption and architectural improvement may be detected over time. The detection of histologic features suggestive of regression may represent useful information, with therapeutic and prognostic implications. Wanless et al⁵ provided a detailed account of such regressive changes, which they termed “hepatic repair complex.” These include delicate, perforated fibrous septa; isolated, thick collagen fibers; delicate periportal fibrous spikes; portal tract remnants; hepatic vein remnants with prolapsed hepatocytes;

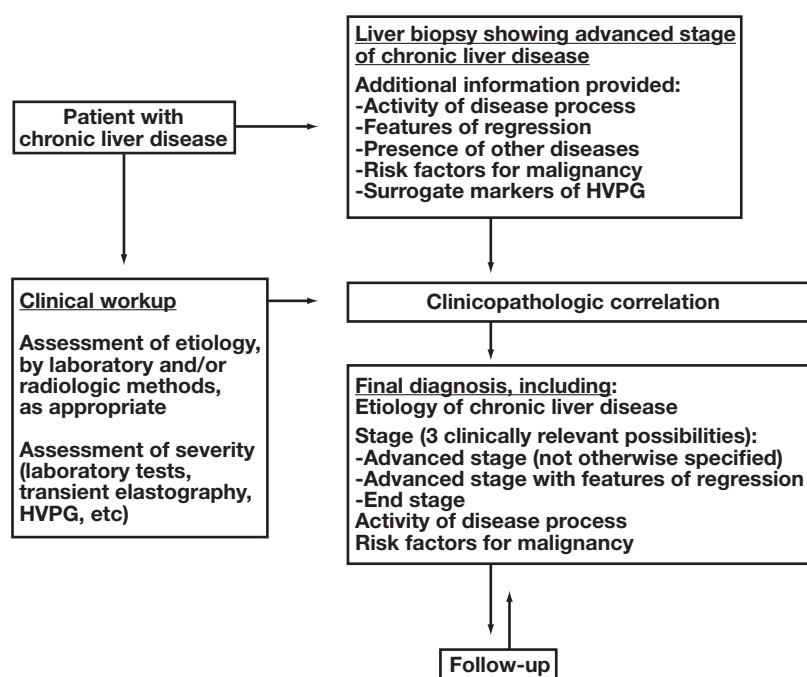


Figure 1 A contemporary approach for the assessment of advanced chronic liver diseases. The stage is determined or confirmed by liver biopsy. The final diagnosis is derived from clinicopathologic correlation (assisted by follow-up, as needed), and includes the etiology, the stage, the activity of the disease process, and risk factors for malignancy. HVPG, hepatic venous pressure gradient.

hepatocytes within portal tracts or splitting septa; minute regenerative nodules; and aberrant parenchymal veins.⁵ Additional studies may further clarify the histologic features that are predictive of progression or regression of each chronic liver disease, thus aiding clinicians in patient management.

Putting Our Proposal Into Practice

Terminology changes are difficult to accomplish, especially for medical terms in widespread use, such as the word cirrhosis. Although the contemporary approach for the assessment of advanced chronic liver diseases delineated herein clearly suggests that this term has outlived its usefulness, wide consensus of pathologists and clinicians will be required for such a terminology change to become successful. This process may take some time to materialize. In the meantime, physicians involved in the diagnosis and treatment of liver diseases may explore the benefits of the recommended change.

In each patient with chronic liver disease, identification of the etiology and determination of stage are the 2 most important factors regarding prognosis and treatment. Determination of stage should be disease-specific (ie, the same staging system is not applicable for all diseases) but is often difficult to accomplish with accuracy in a small biopsy specimen, which is one more reason why a combined clinicopathologic approach seems more reasonable.²⁵ Keeping in mind that staging systems reflect the knowledge and the needs of the period when each of them was invented, our proposal may be considered as a starting point for a fresh look at staging chronic liver diseases in the era of regressing fibrosis.

Therefore, we recommend replacing the word cirrhosis with the term "advanced stage," when reporting the diagnosis of chronic liver diseases. Advanced stage includes cases previously diagnosed as cirrhosis, but also those with significant fibrosis and architectural distortion, which fall short of traditional cirrhosis. In cases with regression of fibrosis and architectural improvement, the term "advanced stage with features of regression" is appropriate. Assessment of fibrosis regression in biopsy material is not an easy task for practicing pathologists at present; this is best accomplished when previous biopsy specimens from the same patient are available for comparison. For cases of advanced-stage chronic liver disease with clinically significant portal hypertension, the term "end stage" may be appropriate. Obviously, carefully designed clinicopathologic studies will be needed to address the definition of end stage in each chronic liver disease. Until then, it is reasonable to associate end stage with an HVPG of 10 to 12 mm Hg or more,

representing a critical threshold beyond which chronic liver disease becomes a systemic disorder with involvement of other organs and systems.^{6,26}

Some examples of how to use these diagnostic terms in pathology reporting include the following: (1) liver biopsy: autoimmune hepatitis, advanced stage, with severe activity; (2) liver biopsy: chronic hepatitis C, advanced stage, with moderate activity, and large cell change of hepatocytes; (3) liver biopsy: chronic hepatitis B, advanced stage, with features of regression, without activity; and (4) liver biopsy: nonalcoholic steatohepatitis, advanced stage (clinically, end stage), with mild activity.

Conclusion

We propose that use of the word cirrhosis should be discontinued and that each patient with chronic liver disease of advanced stage should be provided treatment on the basis of clinicopathologic correlation of all available findings (Figure 1). This proposal is consistent with our current understanding of the evolution of chronic liver diseases and will also remove an unnecessary psychological burden from patients. In addition, research into the pathogenesis and evolution of chronic liver diseases will be facilitated if an etiology-based perspective extends all the way to the end stage. In the past, ignorance was a good reason to lump the advanced stages of different liver diseases together; the opposite may prove to be more useful in the future.

*From the*¹*Department of Pathology, Aristotle University Medical School, Thessaloniki, Greece;*²*Department of Pathology, Fairview Southdale Hospital, Edina, MN;*³*Department of Pathology, University of São Paulo School of Medicine, São Paulo, Brazil;*⁴*Inserm, U1053, Bordeaux University 2, Bordeaux, France;*⁵*Department of Pathology, University of Melbourne, Victoria, Australia;*⁶*Department of Pathology, CHU Bordeaux, Bordeaux, France;*⁷*Department of Pathology and Laboratory Medicine, Hofstra North Shore-LIJ School of Medicine, Hempstead, NY;*⁸*Department of Cellular Pathology, UCL Medical School, London, England;*⁹*Department of Pathology, University of California San Francisco;*¹⁰*Department of Medical Sciences and Special Therapies, Pathology Unit, University of Padova, Padova, Italy;*¹¹*Department of Human Pathology, Kanazawa University Graduate School of Medicine, Kanazawa, Japan;*¹²*Pathology Department, Beaujon Hospital, Clichy, France;*¹³*Institute of Liver Studies, King's College Hospital, London, England;*¹⁴*Departments of Pathology and Medicine (Division of Digestive Diseases), Beth Israel Medical Center of Albert Einstein College of Medicine, New York, NY;*¹⁵*Department of Pathology, Mount Sinai School of Medicine, New York, NY;*¹⁶*Department of Pathology, Caritas Medical Centre, Hong Kong, China; and*¹⁷*Section of Gastroenterology and Hepatology, Dartmouth Medical School, Hanover, NH, and the Onze Lieve Vrouwe Gasthuis, Amsterdam, the Netherlands.*

Address reprint requests to Dr Snover: Dept of Pathology, Fairview Southdale Hospital, 6401 France Ave S, Edina, MN 55435.

References

- Laennec RTH. *De l'auscultation médiate*. Volume 1. Paris, France: Brosson et Claude; 1819:368-369.
- Popper H, Zak FG. Pathologic aspects of cirrhosis. *Am J Med*. 1958;24:593-619.
- Anthony PP, Ishak KG, Nayack NC, et al. The morphology of cirrhosis: definition, nomenclature and classification. *Bull World Health Organ*. 1977;55:521-540.
- Crawford JM. Liver cirrhosis. In: MacSween RNM, Burt AD, Portmann BC, et al, eds. *Pathology of the Liver*. 4th ed. London, England: Churchill Livingstone; 2002:575-619.
- Wanless IR, Nakashima E, Sherman M. Regression of human cirrhosis: morphologic features and the genesis of incomplete septal cirrhosis. *Arch Pathol Lab Med*. 2000;124:1599-1607.
- Garcia-Tsao G, Friedman S, Iredale J, et al. Now there are many (stages) where before there was one: in search of a pathophysiological classification of cirrhosis. *Hepatology*. 2010;51:1445-1449.
- Brunt EM. Non-alcoholic fatty liver disease. In: Burt AD, Portmann BC, Ferrell LD, eds. *MacSween's Pathology of the Liver*. 5th ed. Philadelphia, PA: Churchill Livingstone; 2007:367-397.
- Friedman SL. Mechanisms of hepatic fibrogenesis. *Gastroenterology*. 2008;134:1655-1669.
- Roskams TA, Theise ND, Balabaud C, et al. Nomenclature of the finer branches of the biliary tree: canals, ductules and ductular reactions in human livers. *Hepatology*. 2004;39:1739-1745.
- Poynard T, McHutchison J, Manns M, et al. Impact of pegylated interferon alfa-2b and ribavirin on liver fibrosis in patients with chronic hepatitis C. *Gastroenterology*. 2002;122:1303-1313.
- Dienstag JL, Goldin RD, Heathcote EJ, et al. Histological outcome during long-term lamivudine therapy. *Gastroenterology*. 2003;124:105-117.
- Czaja AJ, Carpenter HA. Decreased fibrosis during corticosteroid therapy of autoimmune hepatitis. *J Hepatol*. 2004;40:646-652.
- Falize L, Guillygomarc'h A, Perrin M, et al. Reversibility of hepatic fibrosis in treated genetic hemochromatosis: a study of 36 cases. *Hepatology*. 2006;44:472-477.
- Chang TT, Liaw YF, Wu SS, et al. Long-term entecavir therapy results in the reversal of fibrosis/cirrhosis and continued histological improvement in patients with chronic hepatitis B. *Hepatology*. 2010;52:886-893.
- Malekzadeh R, Mohamadnejad M, Rakhshani N, et al. Reversibility of cirrhosis in chronic hepatitis B. *Clin Gastroenterol Hepatol*. 2004;2:344-347.
- Bortolotti F, Guido M, Cadrobbi P, et al. Spontaneous regression of hepatitis B virus-associated cirrhosis developed in childhood. *Dig Liver Dis*. 2005;37:964-967.
- Serpaggi J, Carnot F, Nalpas B, et al. Direct and indirect evidence for the reversibility of cirrhosis. *Hum Pathol*. 2006;37:1519-1526.
- Kutami R, Girrahn N, Wanless IR, et al. The Laennec grading system for assessment of hepatic fibrosis: validation by correlation with wedged hepatic vein pressure and clinical features [abstract]. *Hepatology*. 2000;32(suppl):407A.
- Nagula S, Jain D, Groszmann RJ, et al. Histological-hemodynamic correlation in cirrhosis: a histological classification of the severity of cirrhosis. *J Hepatol*. 2006;44:111-117.
- Wanless IR, Crawford JM. Cirrhosis. In: Odze RD, Goldblum JR, eds. *Surgical Pathology of the GI Tract, Liver, Biliary Tract, and Pancreas*. 2nd ed. Philadelphia, PA: Saunders; 2009:1115-1145.
- Calvaruso V, Burroughs AK, Standish R, et al. Computer-assisted image analysis of liver collagen: relationship to Ishak scoring and hepatic venous pressure gradient. *Hepatology*. 2009;49:1236-1244.
- Carrion JA, Navasa M, Bosch J, et al. Transient elastography for diagnosis of advanced fibrosis and portal hypertension in patients with hepatitis C recurrence after liver transplantation. *Liver Transpl*. 2006;12:1791-1798.
- Vizzutti F, Arena U, Romanelli RG, et al. Liver stiffness measurement predicts severe portal hypertension in patients with HCV-related cirrhosis. *Hepatology*. 2007;45:1290-1297.
- Ishak K, Baptista A, Bianchi L, et al. Histological grading and staging of chronic hepatitis. *J Hepatol*. 1995;22:696-699.
- Germani G, Hytioglou P, Fotiadu A, et al. Assessment of fibrosis and cirrhosis in liver biopsies: an update. *Semin Liver Dis*. 2011;31:82-90.
- Pinzani M, Rosselli M, Zuckermann M. Liver cirrhosis. *Best Pract Res Clin Gastroenterol*. 2011;25:281-290.

First and Only FDA Cleared Digital Cytology System

Genius™ Cervical AI

Genius™ Review Station

Genius™ Digital Imager



Empower Your Genius With Ours

Make a Greater Impact on Cervical Cancer
with the Advanced Technology of the
Genius™ Digital Diagnostics System



Click or Scan
to discover more

ADS-04159-001 Rev 001 © 2024 Hologic, Inc. All rights reserved. Hologic, Genius, and associated logos are trademarks and/or registered trademarks of Hologic, Inc. and/or its subsidiaries in the United States and/or other countries. This information is intended for medical professionals in the U.S. and other markets and is not intended as a product solicitation or promotion where such activities are prohibited. Because Hologic materials are distributed through websites, podcasts and tradeshows, it is not always possible to control where such materials appear. For specific information on what products are available for sale in a particular country, please contact your Hologic representative or write to diagnostic.solutions@hologic.com.

genius™
DIGITAL DIAGNOSTICS