

---

## REVIEW ARTICLE

---

# A review of paroxysmal hemicranias, SUNCT syndrome and other short-lasting headaches with autonomic feature, including new cases

---

Peter J. Goadsby<sup>1</sup> and Richard B. Lipton<sup>2,3</sup>

<sup>1</sup>*Institute of Neurology, The National Hospital for Neurology and Neurosurgery, London, UK and*

<sup>2</sup>*Department of Neurology, Albert Einstein College of Medicine and* <sup>3</sup>*Headache Unit, Montefiore Medical Centre, New York, USA*

*Correspondence to: Dr Peter J. Goadsby, Institute of Neurology, Queen Square, London WC1N 3BG, UK*

### Summary

*The short-lasting primary headache syndromes may be conveniently divided into those exhibiting marked autonomic activation and those without autonomic activation. The former group comprise chronic and episodic paroxysmal hemicrania, short-lasting unilateral neuralgiform headache with conjunctival injection and tearing (SUNCT syndrome) and cluster headache. These headache syndromes are compared with other short-lasting headache disorders, such as hypnic headache, and persistent headache with milder autonomic features such as hemicrania continua. Cluster headache is included with the shorter-lasting headaches to attempt a nosological analysis of these syndromes. The paroxysmal hemicranias are characterized by frequent short-lasting attacks of unilateral pain usually in the orbital, supra-orbital or temporal region that typically last minutes. The attack frequency usually ranges from 5 to 40 attacks per day. The pain is severe and associated with autonomic symptoms*

*such as conjunctival injection, lacrimation, nasal congestion, rhinorrhoea, ptosis or eyelid oedema. Almost all reported cases respond to treatment with indomethacin, but respond poorly to other treatments including other nonsteroidal anti-inflammatory drugs. A recent case study demonstrated the release of both trigeminal and parasympathetic neuropeptides during a bout of pain in the same pattern previously described in cluster headache. The SUNCT syndrome is a distinctive rare condition characterized by less severe pain but marked autonomic activation during attacks. Consistent with previous reports, the present case of SUNCT syndrome was intractable to therapy. The similarities of these syndromes suggests a considerable shared pathophysiology. It is suggested that the syndromes are sufficiently well established for inclusion in the International Headache Society Classification system and that trigeminal–autonomic cephalalgias should be classified as a group together. A proposed re-classification is presented.*

**Keywords:** parasympathetic; cluster headache; chronic paroxysmal hemicrania; hypnic headache; hemicrania continua

**Abbreviations:** CGRP = calcitonin-gene related peptide; CPH = chronic paroxysmal hemicrania; EPH = episodic paroxysmal hemicrania; HC = hemicrania continua; IHS = International Headache Society; NSAIDs = non-steroidal anti-inflammatory drugs; SUNCT syndrome = short-lasting unilateral neuralgiform headache with conjunctival injection and tearing; TAC = trigeminal–autonomic cephalgia; VIP = vasoactive intestinal polypeptide

---

### Introduction

Though migraine and tension-type headache are extraordinarily common, some primary headache syndromes are relatively rare and poorly recognized in mainstream neurological practice. Despite the diagnostic challenges, the short-

lasting primary headaches are important to recognize because of their excellent but highly selective response to treatment. Accurate diagnosis will often lead to appropriate treatment and the rapid relief of the patient's pain problem. It is also

**Table 1** Primary short-lasting headaches

Prominent autonomic features	Sparse or no autonomic features
Cluster headache*	Trigeminal neuralgia*
Chronic paroxysmal hemicrania*	Idiopathic stabbing headache*
Episodic paroxysmal hemicrania	Cough headache*
SUNCT syndrome <sup>†</sup>	Benign exertional headache*
Cluster-tic syndrome	Headache associated with sexual activity*
	Hypnic headache

\*Denotes inclusion in current IHS criteria (Headache Classification Committee of the IHS, 1988). <sup>†</sup>SUNCT = shortlasting unilateral neuralgiform headache with conjunctival injection and tearing.

possible that some of these syndromes are not as rare as currently believed. Finally, the curious associated features of these disorders may help us to understand better the mechanisms of the more common primary headaches.

In this article, we discuss a group of primary headache disorders characterized by short-lived unilateral pain and ipsilateral autonomic features. A more comprehensive list of short-lasting headaches is provided in Table 1. Idiopathic stabbing headache, cough headache, exertional headache, sexual headache and trigeminal neuralgia are not reviewed as these disorders have no autonomic component. Cluster headache (Kudrow, 1980; Sjaastad, 1992; Lance, 1993) and its treatment is extensively reviewed elsewhere (Goadsby, 1994). We hypothesize that the short-lasting headaches with autonomic features are characterized by a nexus of activation between trigeminal afferents (giving rise to pain) and cranial parasympathetic efferents (giving rise to autonomic features), a trigeminal–autonomic activation. A linked pathophysiology is the hallmark of these syndromes which we shall term trigeminal–autonomic cephalgias (TACs), connecting their clinical phenotype but not necessarily implying a common underlying pathogenesis. Given that all head pain involves trigeminal afferent activity, and that trigeminal–autonomic connections are likely to be present and functional (Goadsby and Lance, 1988), it is a peculiarity of these syndromes that there is relatively marked cranial parasympathetic outflow.

Some short-lived headaches have serious underlying causes. Structural disease may give rise to short-lived headaches sometimes triggered by a Valsalva or postural change. Mass lesions, including those which interfere with cerebrospinal fluid egress, and pathology in the posterior fossa or base of the skull are particularly associated with short-lived Valsalva or cough-related headache. Even subarachnoid haemorrhage can give rise to brief headache. These secondary headaches are outside the scope of the present discussion and have been reviewed recently (Edmeads, 1997).

We review here the clinical features, laboratory investigations and pathophysiology of the TACs including chronic paroxysmal hemicrania (CPH), episodic paroxysmal hemicrania (EPH) and short-lasting unilateral neuralgiform headache with conjunctival injection and tearing (SUNCT). We

contrast these disorders with cluster headache, the prototypic TAC, as well as hypnic headache and hemicrania continua (HC). Following clinical descriptions we discuss the pathophysiology of the TACs. Of the disorders discussed the International Headache Society (IHS) does not provide criteria for EPH, SUNCT, hypnic headache or HC. We propose criteria for these disorders for consideration by the wider headache and neurological community.

## Headache syndromes

### *Chronic paroxysmal hemicrania (CPH)*

CPH, a relatively well-characterized disorder (Russell, 1984; Antonaci and Sjaastad, 1989; Sjaastad and Shen, 1991; Sjaastad, 1992; Spierings, 1992), was first described in 1974 (Sjaastad and Dale, 1974; Sjaastad, 1986) and appears in the International Headache Society classification (Headache Classification Committee of the IHS, 1988). The condition is defined by operational diagnostic criteria including frequent short-lasting attacks of unilateral pain, usually in the orbital, supra-orbital or temporal region that last 2–45 min. The characteristic attack frequency is  $\geq 5$  per day, but there are literature reports of between 1 and 40 attacks per day. The pain is associated with at least one autonomic symptom such as conjunctival injection, lacrimation, nasal congestion, rhinorrhoea, ptosis or eyelid oedema. The IHS criteria require that the attacks should rapidly resolve following treatment with indomethacin. The dose is up to 150 mg/day orally and the response is usually within days of initiating an adequate dose. The IHS diagnostic criteria have proved to be very reliable in their practical application in CPH (Leone *et al.*, 1994). Although the attack frequency may vary, by definition, the chronic form should not remit. The IHS classification noted that 'the chronic stage may be preceded by an episodic stage similar to the pattern seen in cluster headache, but this has not yet been sufficiently validated'.

The relationship between CPH and cluster headache is uncertain. The many clinical similarities between cluster headache and chronic paroxysmal hemicrania argue that the disorders should be broadly classified together. CPH is distinguished from cluster headache primarily by the shorter duration and higher frequency of headache attacks, by the female preponderance of the disorder and by the selective response to indomethacin. As cases have emerged (Price and Posner, 1978; Russell *et al.*, 1978; Hochman, 1981; Rapoport *et al.*, 1981) the clinical boundaries have become somewhat less distinct. It seems inappropriate at a biological level, and perhaps a clinical level, to insist on the absolute response to indomethacin as a diagnostic indicator. This would be better reduced to a strong indicator to the diagnosis until the biological basis for that response is better understood.

### *Clinical features*

CPH has no racial boundaries and is well described in black South Africans (Joubert *et al.*, 1987; Joubert, 1988). The age

of onset is usually in the twenties (Sjaastad, 1986), although there have also been reports of the condition in children at the ages of 3 (Broske *et al.*, 1993), 9 (Kudrow and Kudrow, 1989) and 8 years (Gladstein *et al.*, 1994). At least one of these cases (Gladstein *et al.*, 1994) may be better characterized as a cluster headache (Solomon and Newman, 1995). In paediatric cases, the syndrome may be characterized by daily attacks. The natural history will ultimately be determined by long-term observations. The sex distribution is a 3:1 female to male ratio (Antonaci and Sjaastad, 1989). Although the pain is usually in the distribution of the ophthalmic division of the trigeminal nerve, it has been reported in the occipital region in a single case (Sjaastad, 1986). Although occipital pain may seem curious on anatomical grounds, this clinical finding has an experimental correlate. In animal experiments, stimulation of the greater occipital nerve leads to release of vasoactive peptides, such as vasoactive intestinal polypeptide (VIP) (Vincent *et al.*, 1992). Moreover, although the syndrome is almost invariably unilateral, one patient with bilateral pain responded to indomethacin (Pollmann and Pfaffenrath, 1986). The pain is excruciating and may be throbbing as it builds up, although it is usually stabbing or boring. In contrast to patients with cluster headache some with CPH sit quietly holding their heads or may take to their beds (Stein and Rogado, 1980). This behaviour is rare in cluster headache. The attack frequency ranges from 1 to 40 per day with a median frequency of about 5–10 per day. Patients may have soreness or tenderness in the interval between attacks, especially if the attacks are frequent. This is not a special feature of CPH but is a generic feature of severe frequent headache which may be expected with the significant nociceptive load being placed on the trigeminal pain system. The 2–45 min-duration (Russell, 1984) is shorter than the 15–180 min duration usually accepted for cluster headache (Headache Classification Committee of the IHS, 1988), although the overlap can add diagnostic problems. The associated autonomic symptoms are almost completely accounted for by cranial parasympathetic activation, as has been documented in cluster headache (Goadsby and Edvinsson, 1994*b*) save the ptosis which is likely to be a partial Horner's syndrome due to a functional sympathetic deficit (Drummond, 1985). Parasympathetic activation may cause oedema of the wall of the internal carotid artery and subsequent compression of the cervical sympathetic nerves as they pass through the base of the skull. Interestingly, there are patients with otherwise typical CPH, including a good indomethacin response, with no autonomic features (Bogucki *et al.*, 1984; Pareja, 1995*b*). Attacks may be precipitated by mechanical stimulation, particularly with head movement (Sjaastad *et al.*, 1979, 1982, 1984) in some patients.

#### *Pathophysiology and investigations*

The essential pathophysiology of CPH is quite unknown. The comparative rarity of the syndrome as well as the short-lasting nature of the individual attacks make it a difficult

disorder to study. The available observations suggest similarities with cluster headache.

*Blood and neuropeptide changes.* Alterations in cyclic release of catecholamines and  $\beta$ -endorphin are observed in CPH (Micieli *et al.*, 1989), and are similar to those reported in cluster headache. Recently, we observed an increased level of calcitonin-gene related peptide (CGRP) and VIP in the cranial venous blood of a patient with CPH. The levels returned to normal with successful treatment using indomethacin (Goadsby and Edvinsson, 1996). These data are discussed in the section 'Pathophysiology of TACS' below. Other observations in CPH include relative thrombocythaemia (MacMillan and Nukada, 1989) and increased phosphatidylserine labelling in neutrophils (Fragoso *et al.*, 1988). The relationship of these changes to the underlying problem is not clear. Blood dyscrasias would not be a widespread experience of physicians treating primary headache syndromes and the neutrophil studies seem of doubtful significance.

*Electrophysiological and autonomic studies.* In electrophysiological studies, patients with CPH are reported to have reduced pain thresholds, reduced corneal reflex thresholds and normal blink reflexes (Antonaci *et al.*, 1994). Studies of autonomic function, including salivation and nasal secretion did not demonstrate consistent abnormalities (Saunte, 1984). Facial sweating is normal in CPH (Antonaci, 1991), although facial sweating abnormalities have been documented in cluster headache (Drummond and Lance, 1992). Pupillometric studies in CPH demonstrate that the pupil ipsilateral to the pain is consistently smaller than its unaffected counterpart (Carvalho *et al.*, 1988), most likely reflecting a partial Horner's syndrome. Similar findings were observed in careful studies of patients with cluster headache (Drummond, 1988). Bradycardia has been observed in CPH and one of five patients studied developed a bundle branch block and atrial fibrillation during attacks (Russell and Storstein, 1984). Whether the bradycardia ultimately reflects a response to the very severe pain or is part of an underlying autonomic problem requires further study.

*Blood flow studies.* Facial thermographic studies have shown either cold spots over the supraorbital margin or inner canthus interictally (Mongini *et al.*, 1990) or increases in temperature over the affected area during the headache (Drummond, 1985). The thermographic results of Mongini (Mongini *et al.*, 1990) were identical for patients with CPH and cluster headache. Cerebral blood flow studies of CO<sub>2</sub> reactivity, as measured by transcranial Doppler, were abnormal in three patients (Shen, 1993) while ocular blood flow was increased during attacks in a single patient (Horven *et al.*, 1989). The low numbers of patients in these studies effectively mean that no judgement can usefully be made about the results. However, the modest changes that are seen are in line with what is reported in regional (Krabbe *et al.*,

**Table 2** Secondary chronic paroxysmal hemicrania and clinical associations

---

Gangliocytoma of the sella turcica (Vijayan, 1992)
Collagen vascular disease (Medina, 1992)
Cerebrovascular disease (Newman <i>et al.</i> , 1992b)
Pancoast tumour (Delreux <i>et al.</i> , 1989)
Frontal lobe tumour (Medina, 1992)
Cavernous sinus meningioma (Sjaastad <i>et al.</i> , 1995)
Intracranial hypertension; increased CSF pressure (Hannerz and Jogestrand, 1993)
Associations:
trigeminal neuralgia (CPH-tic syndrome) (Hannerz, 1993)
cluster headache (Tehindranarivelo <i>et al.</i> , 1992)
migraine (Pareja and Pareja, 1992)

---

1984; Meyer *et al.*, 1991) or transcranial Doppler studies (Dahl *et al.*, 1990) in cluster headache in which the greater numbers of patients studied make the results more convincing. The ocular blood flow changes observed in CPH are similar to those in cluster headache although, in comparison with normals, cluster headache patients had relatively reduced flow between attacks (Horven *et al.*, 1989).

**Imaging.** MRI studies of patients with CPH have been normal (Antonaci, 1994), but segmental narrowing of ophthalmic veins on orbital phlebography has been reported (Antonaci, 1994), similar to the changes seen in cluster headache (Hoes *et al.*, 1981; Hannerz, 1988) and in the Tolosa-Hunt syndrome (Tolosa, 1954; Hunt *et al.*, 1961). The findings on orbital phlebography are neither specific nor likely to be pathophysiologically relevant and the test has no practical place in patient management.

There are, therefore, no specific diagnostic investigations for CPH. The only clear conclusion from the pathophysiological and imaging studies of CPH is that attacks are associated with parasympathetic activation most likely mediated through the greater superficial petrosal outflow with an associated mild partial Horner's syndrome. There is little to suggest a fundamental neurobiological separation between CPH and cluster headache in regard to the final common pathways activated. The shorter attack duration, greater attack frequency and different effect of indomethacin perhaps points to differences in the generation thus central nervous system mechanisms of these disorders.

**Differential diagnosis.** The differential diagnosis of CPH includes the other primary short-lasting headaches (Table 1) and the secondary causes of CPH (Table 2). Because secondary CPH is relatively common, investigations are required to identify or exclude treatable underlying causes. A reasonably complete screening of a patient with CPH, considering the associated clinical problems reported, would include a blood count, looking for thrombocythaemia (MacMillan and Nukada, 1989), ESR (erythrocyte sedimentation rate) and vasculitic investigations (Medina, 1992), and a brain imaging procedure looking for an intracranial tumour such as a lesion in the region of the sella turcica

(Gawel and Rothbart, 1992; Vijayan, 1992) or elsewhere (Medina, 1992). Other structural mimics of CPH include an arteriovenous malformation (Newman *et al.*, 1992b) or cavernous sinus meningioma, and secondary CPH is more likely if the patient requires high doses (>200 mg/day) of indomethacin (Sjaastad *et al.*, 1995). Should the pain become bilateral then a lumbar puncture should be carried out to look for intracranial hypertension, even in the face of a response to indomethacin (Hannerz and Jogestrand, 1993). When appropriate, an electrocardiogram and Holter monitor should be considered to look for bundle branch block or atrial fibrillation (Russell and Storstein, 1984) and a chest X-ray should be considered to look for a Pancoast Tumour (Delreux *et al.*, 1989).

### Treatment

The standard treatment for CPH is indomethacin in a dose of 25 mg t.d.s., increasing to 50 mg t.d.s. after a week if there is no response. Occasional patients require higher doses or slow-release indomethacin preparations at night to treat break through headaches. In some patients gastrointestinal side-effects require treatment with gastro-protective agents, such as histamine-2 or proton pump blockers. There seems to be no tachyphylaxis to the effects of indomethacin (Sjaastad and Antonaci, 1987). Although the IHS criteria require a response to indomethacin, this makes little clinical sense as an absolute rule. Certainly other drugs have been reported to favourably affect CPH favourably. Though less effective, other non-steroidal anti-inflammatory drugs (NSAIDs), such as naproxen (Hannerz *et al.*, 1987), have been used. Calcium-channel blockers have been reported to be useful in CPH, perhaps analagous to their use in cluster headache. This has been most convincingly suggested for verapamil (Schlake *et al.*, 1990; Shabbir and McAbee, 1994). There is a case report of a patient with an otherwise convincing clinical picture who failed to respond to indomethacin 300 mg t.d.s. but responded to acetazolamide 250 mg t.d.s. (Warner *et al.*, 1994). Sumatriptan was reported to be of benefit in a patient with bilateral CPH (Hannerz and Jogestrand, 1993) although it was ineffective in a more typical case (Dahlof, 1993). In the authors' experience, sumatriptan does not alter CPH in any substantial manner, in contrast to its striking effects in cluster headache (Goadsby, 1994). This apparent contrast, which may be a reverse of the indomethacin response, must be regarded as preliminary until there are sufficient reports of longer duration CPH that do not respond to sumatriptan. The lack of a response in very short headaches may be simply that, even in cluster headache, the response takes 7–10 min (Ekbom, 1991). It would be of great interest to treat a longer CPH attack with oxygen, which is certainly effective in cluster headache (Kudrow, 1981). The acute attack response should be contrasted with preventative treatment in cluster headache and CPH. The only consistent picture for a preventative in the literature is that verapamil is effective for both CPH and cluster headache.

### ***Episodic paroxysmal hemicrania (EPH)***

EPH is an extremely rare form of headache characterized by frequent, daily attacks of short-lived, unilateral very severe headache with accompanying ipsilateral autonomic features (Kudrow *et al.*, 1987; Newman *et al.*, 1992a; Spierings, 1992). Periods of frequent attacks are separated by relatively long remissions lasting weeks or months in a pattern similar to episodic cluster headache (Headache Classification Committee of the IHS, 1988). Named by Kudrow (Kudrow *et al.*, 1987) some consider this headache an episodic variant of CPH (Newman *et al.*, 1992a) but definitive classification will require more data. A new case of one the author's (P.J.G.) will serve to describe this condition.

**Case report.** A 35-year-old woman presented with an 8-year history of headache. She described stabbing severe left frontal and retro-orbital pains that would last 1–2 min and occur 3–5 times per day. The attacks were associated with marked watering of the left eye and left sided ptosis. She had no nasal stuffiness nor migrainous features. She would typically move rather than be still during an attack. The attacks came in bouts of 6 months with intervening breaks of 10–12 months. She had been tried on numerous medications, including, corticosteroids, methysergide, lithium, propranolol, pizotifen and amitriptyline, and had used ergotamine. All of these had been without effect. When she was first seen by the author she was 2 months into a bout. She was commenced on indomethacin 25 mg t.d.s. and her headaches ceased completely after 3 days. The drug was stopped 2 weeks later and the attacks recurred within 2 days, they again settled rapidly when indomethacin was restarted.

### ***Clinical features***

There are 13 cases of EPH in the literature (Geaney, 1983; Bogucki and Niewodniczy, 1984; Kudrow *et al.*, 1987; Spierings, 1988; Blau and Engel, 1990; Alberca *et al.*, 1991; Newman *et al.*, 1992a). The headache consists of bouts of short-lasting headache varying from 1 to 30 min which have been reported to occur from six to 30 times a day. The pain is described as severe, throbbing or stabbing and is localized to the orbital or temporal regions. There is no evidence for a sex-based predominance and the age of onset varies from 12 to 51 years. All published reports, and this author's (P.J.G.) single case experience, have an absolute response to indomethacin. Calcium-channel blockers have also been used (Coria *et al.*, 1992). The author has used naproxen in a single patient and the response was incomplete compared with indomethacin. Further reports are required to describe the condition more clearly with respect to its natural history and relationship to cluster headache and CPH. It is well recognized (*see above*) that EPH may evolve from a disorder with distinct intervals into a chronic unremitting form which is identical to CPH. It is likely that the two conditions are ends of a spectrum just as episodic and chronic cluster headache

form ends of a spectrum. The clinical cases of transformation from the episodic to the chronic phase are perhaps the clearest evidence that EPH and CPH are closely biologically related. However, following the analogy of cluster headache we prefer a nosology which distinguishes the two.

### ***Short-lasting unilateral neuralgiform headache with conjunctival injection and tearing (SUNCT)***

This form of short-lasting headache is also among the rarest of headache syndromes and again has curious autonomic associations (Sjaastad *et al.*, 1989). Several clinical features differentiate it from other short-lasting headaches. A new case of one of the author's (P.J.G.) will illustrate the clinical picture.

### ***Case report***

A 56-year-old woman presented with a 5-year history of daily episodic short-lasting headaches. Attacks occurred up to five times a day and lasted 15–20 s each. The attacks were left-sided, moderately severe and retro-orbital. They were associated with marked tearing and redness of the ipsilateral eye with mild rhinorrhoea. There was no nausea, photophobia or phonophobia. There was no history of migraine nor family history of headache. On examination, there were no physical signs of the nervous system and she was normotensive. MRI of the brain was normal. She had used amitriptyline, propranolol, pizotifen, methysergide, lithium and verapamil without success. The latter made the attacks longer and the pain more severe. She had had a trial of steroids and used ergots and sumatriptan without success. She also had an unsuccessful trial of indomethacin, valproate and carbamazepine. She was refractory when lost to follow-up.

### ***Clinical features***

The patients recognized with this problem are largely males with a gender ratio of 17 to 2 (Pareja and Sjaastad, 1994). The paroxysms of pain usually last between 5 and 250 s (Pareja *et al.*, 1996b) although longer duller interictal pains have been recognized, as have attacks up to 2 h in two patients (Pareja *et al.*, 1996a). Patients may have up to 30 episodes per hour although more usually they would have 5–6 per hour. The frequency may also vary in bouts. A frequency as low as once or twice in 1–4 weeks has been seen in a male patient who at other times had up to 20 attacks a day (Sjaastad *et al.*, 1991), while another reported case had almost continuous attacks for up to 3 h (Pareja *et al.*, 1994). A systematic study of attack frequency demonstrated a mean of 28 attacks per day with a range of 6–77 (Pareja *et al.*, 1996b). The conjunctival injection seen with SUNCT is often the most prominent autonomic

feature and tearing may also be very obvious. Other less prominent autonomic stigmata, include sweating of the forehead or rhinorrhoea. The attacks may become bilateral but the most severe pain remains unilateral. Most cases have some associated precipitating factors which may be mechanical movements of the neck (Becser and Berky, 1995). This latter feature is seen often in TACs including cluster headache (Cremer *et al.*, 1995).

### Secondary SUNCT and associations

There have been three patients reported to have secondary SUNCT syndrome. The first two patients had homolateral cerebellopontine angle arteriovenous malformations diagnosed on MRI (Bussone *et al.*, 1991; De Benedittis, 1995). The third patient had a cavernous hemangioma of the brainstem seen only on MRI (Morales *et al.*, 1994). A posterior fossa lesion causing otherwise typical SUNCT has also been noted in HIV/AIDS patients (S. Graff-Radford, personal communication). These cases highlight the need for cranial MRI in investigating secondary SUNCT patients.

The connections between posterior structures and the trigeminal system proper are well documented in the laboratory (Kaube *et al.*, 1993) and in clinical practice (Martins *et al.*, 1993). Just as there is a reported case of CPH associated with trigeminal neuralgia, there is also a single report of a patient with trigeminal neuralgia who developed a SUNCT syndrome (Bouhassira *et al.*, 1994). These cases suggest that the trigeminal pathways may be involved in the entire range of short-lasting headache syndromes.

### Investigations

Orbital phlebography is reported to be abnormal in SUNCT with a narrowed superior ophthalmic vein homolateral to the pain (Kruszewski, 1992). This finding leads to the suggestion that SUNCT may be a form of orbital venous vasculitis (Hannerz *et al.*, 1992), although there are similar reports in cluster headache, Tolosa-Hunt syndrome and in CPH (*see above*). Forehead sweating is usually increased during bouts (Kruszewski *et al.*, 1993) unlike CPH in which it is normal. Pupillary studies using pupillometry and pharmacological approaches have revealed no abnormalities (Zhao and Sjaastad, 1993). Since conjunctival injection occurs during SUNCT, it is not surprising that intraocular pressure and corneal temperatures are elevated during attacks (Sjaastad *et al.*, 1992). This most likely reflects marked parasympathetic activation with local vasodilatation. Similarly, a report of bradycardia in association with attacks of SUNCT may similarly indicate increased parasympathetic outflow (Kruszewski *et al.*, 1992). Systolic blood pressure is sometimes elevated (Kruszewski *et al.*, 1991), although ventilatory function is normal (Kruszewski *et al.*, 1995). The parasympathetic manifestations favour a central pathogenesis for SUNCT as a manifestation of the trigeminovascular reflex (Goadsby *et al.*, 1991), rather than a peripheral vasculitic

**Table 3** Treatments of SUNCT tried but ineffective

Treatment	Dosage (max/day)	Response	No. of reported patients
<b>Pharmacological</b>			
Aspirin	1800 mg	–	6
Paracetamol	4 g	–	6
Indomethacin	200 mg	–	9
Naproxen	1 g	–	3
Ibuprofen	1200 mg	–	3
Ergotamine (oral)	3 mg	–	7
Dihydroergotamine (i.v.i.)	3 mg	–	1
Sumatriptan (oral)	300 mg	–*	5
Sumatriptan (s.c.)	6 mg	–	1
Prednisone (oral)	100 mg	–	7
Methysergide	8 mg	–	4
Verapamil	480 mg	X	5
Valproate	1500 mg	–*	5
Lithium	900 mg	–	3
Propranolol	160 mg	–	3
Amitriptyline	100 mg	–	2
Carbamazepine	1200 mg	–	10
<b>Procedures or infusions</b>			
Lignocaine (i.v.i.)	4 mg/min	–	2
Greater occipital nerve	block	–	4

This summary is drawn from a recent excellent review (Pareja *et al.*, 1995) and the authors' personal experience. – = treatment had no effect; X = treatment worsened condition; s.c. = subcutaneous; i.v.i. = intravenous infusion. \*One patient with slight improvement.

cause. Transcranial Doppler and SPECT (single photon emission computed tomography) studies have not demonstrated convincing change in the vasomotor activity (Shen and Johnsen, 1994) or cerebral blood flow during attacks of pain (Poughias and Aasly, 1995).

### Treatment of SUNCT

Unlike CPH and EPH, which are highly responsive to indomethacin, SUNCT is remarkably refractory to all treatments so far described, including indomethacin (Table 3). Most drugs used in the treatment of other short-lasting headaches are not useful in SUNCT. Indeed it is the authors' experience, and well recognized in published series (Pareja *et al.*, 1995), that SUNCT can be very refractory to therapy. Drugs and procedures that have been reported to be either useful or without effect in SUNCT are recorded in Table 3. A recent report (Ghose, 1995) cites two patients with a provisional diagnosis of SUNCT which responded to sumatriptan. These are most likely to represent a spontaneous remission and are only described in a limited way. Indomethacin is not generally useful in SUNCT.

### Hemicrania continua (HC)

As its name implies, HC is characterized by a continuous, unilateral headache pain which is usually of moderate severity

(Sjaastad and Spierings, 1984). Three-fifths of patients have superimposed attacks of more intense pains which are often short-lived but may last up to several days. The painful exacerbations are often associated with autonomic features, including ptosis, conjunctival injection, lacrimation and nasal congestion, hence the inclusion of this headache syndrome in this review. In general, these features are less prominent than the autonomic features of cluster headache or of the paroxysmal hemicranias. An unpublished case of one of the author's (R.B.L.) will illustrate the clinical features.

### Case report

A 45-year-old woman presented with a 10-year history of daily unilateral headache. In the remote past, she had occasional periods of left-sided headache lasting from 1 month to 1 year. At the time of presentation, she had a constant, widely distributed, left-sided hemicranial headache which waxed and waned in severity. The pain was usually mild to moderate but from eight to 20 times a month she experienced exacerbations which lasted up to 12 h, characterized by more severe left periorbital and hemicranial pain accompanied by left-sided miosis, ptosis and nasal congestion. The exacerbations were also associated with nausea and sensitivity to sensory stimuli. Her past medical history was unremarkable. General medical and neurological examinations and routine laboratory studies were unremarkable. MRI of the head was normal in the past.

She had been treated with several beta-blockers, calcium-channel blockers, tricyclic antidepressants, serotonin re-uptake inhibitors, methysergide and divalproex sodium, without relief. Inpatient treatment with dihydroergotamine did not improve her headaches. Acute treatment with several NSAIDs, transnasal butorphanol and bupivacaine combination products were not helpful. Subcutaneous sumatriptan produced short-term relief during painful exacerbations.

Following a tentative diagnosis of HC, she was started on indomethacin 50 mg t.d.s. a day. Her daily headache resolved following each dose but recurred at the end of dosing intervals. Her regimen was gradually increased to a final dose of 75 mg t.d.s. daily with ranitidine (150 mg b.d.). Her other medications have been tapered and she is headache free unless she skips a dose of indomethacin.

### Clinical features

Newman *et al.* (1994) have classified patients with HC into three groups: (i) those with a remitting form with distinct headache phases lasting weeks to months with prolonged pain free remissions (Iordanidis and Sjaastad, 1989; Pareja *et al.*, 1990); (ii) those with an evolutive unremitting form which arises from the remitting form (Sjaastad and Tjorstad, 1987; Sjaastad and Antonaci, 1993); and (iii) those with an unremitting form characterized by continuous headache from the onset (Zukerman *et al.*, 1987). The proportion of patients in each group is as follows: remitting form (15%); evolutive

form (32%); and unremitting form (53%). Not surprisingly, a chronic form evolving to a remitting form (Pareja, 1995a), a bilateral case (Pasquier *et al.*, 1987) and a patient whose attacks alternated sides (Newman *et al.*, 1992c) have all been described. Like the short-lived trigeminal autonomic cephalgias, HC is characterized by episodic attacks of head pain associated with ipsilateral autonomic features. Like the paroxysmal hemicranias, HC is uniquely responsive to indomethacin although a series of four patients who did not respond, but fit the clinical phenotype, have been described (Kuritzky, 1992). A case responding to piroxicam- $\beta$ -cyclodextrin (Trucco *et al.*, 1992) further suggests that while the NSAID response is of great interest, it points to rather than expresses the pathophysiology.

HC is differentiated from the other trigeminal autonomic cephalgias primarily by its continuous moderate pain without autonomic features between the painful exacerbations. Although there are no reports of secondary HC, a C7 root irritation due to a disc herniation has been noted to aggravate the condition (Sjaastad *et al.*, 1995). A case of a mesenchymal tumour in the sphenoid bone has also been reported in which the response to indomethacin faded after 2 months (Antonaci and Sjaastad, 1992). These cases suggest that escalating doses or loss of efficacy of indomethacin should be treated with suspicion and the patient re-evaluated. The condition is seen in non-caucasian populations (Joubert, 1991).

### Pathophysiological studies

The relative rarity of HC has also made it difficult to study its pathophysiology. It is reported that pain pressure thresholds are reduced in patients with HC as they are in CPH (Antonaci *et al.*, 1994). In contrast, orbital phlebography is relatively normal compared with that in patients with CPH (Antonaci, 1994), although it should be observed that this area is controversial (Bovim *et al.*, 1992). Pupillometric studies have shown no clear abnormality in HC (Antonaci *et al.*, 1992) and studies of facial sweating have shown modest changes similar to those seen in CPH (Antonaci, 1991).

### Classification

The nosology of these headaches is a difficult issue. While they are clearly daily or near daily by definition and have thus been sensibly listed with other headache syndromes that cause daily headache (Silberstein *et al.*, 1994). Medication overuse, a common aggravating factor in headache syndromes (Mathew, 1987; Sheftell, 1992), may confuse the diagnosis of HC (Young and Silberstein, 1993). Whether medication overuse can produce HC is not settled. Given the overlap with the other trigeminal-autonomic cephalgias, we propose that HC be classified for the moment with those headaches. It is likely that the indomethacin response that is shared between the paroxysmal hemicranias and HC will have some clear linked pharmacological basis and further suggests that

a convenient classification of these headaches together may eventually have some biological basis.

### **Hypnic headache**

Hypnic headache is a rare short-lived primary headache disorder. Although it should be considered in the differential diagnosis of trigeminal autonomic cephalgias it is defined, in part, by the paucity of autonomic features. A case history will illustrate its main features.

#### *Case history*

An 84-year-old woman presented with a 2-year history of nocturnal headaches. The headache awakened her from sleep, usually three times a night, at ~2 h intervals. The headaches were diffuse in location and of pulsating quality, lasting 30 min. There were no autonomic features. Specifically ptosis, lacrimation and rhinorrhoea were absent. The headaches never occurred during the day. Treatment with antidepressants and sedative hypnotics had no effect. Her general medical and neurological examination, routine laboratory studies and a CT of the head were unremarkable. Treatment with lithium carbonate 600 mg at bedtime resulted in a sustained remission of her headaches.

Of the eight reported cases with hypnic headache reviewed by Newman *et al.* (1990), all had recurrent attacks of generalized headache which awakened them at a consistent time each night. The disorder enters into the differential diagnosis of trigeminal autonomic cephalgias because of the short-lived nature of the attacks and is differentiated by the lack of autonomic features.

### **Clinical features and differential diagnosis of trigeminal–autonomic cephalgias (TACs) and related disorders**

The TACs are characterized by short-lasting headaches with autonomic features. For CPH, EPH and the SUNCT syndrome, autonomic features accompany attacks of severe pain. In HC the autonomic features rarely present when the pain is mild and become more prominent during severe pain. Pain and autonomic features may be dissociated, as they may be in CPH (Pareja, 1995*b*). Hypnic headache attacks are short-lived, moderate in intensity and not accompanied by autonomic features. Thus, severe short-lived pain is the usual concomitant of autonomic features. Despite their common elements, the TACs differ in attack duration and frequency as well as the response to therapy (Table 4). Of the disorders discussed herein, the SUNCT syndrome has the shortest attack duration and the highest attack frequency. The paroxysmal hemicranias have intermediate durations (1–45 min) and intermediate attacks frequencies. Cluster headache has longer attack durations (15–180 min) and relatively low attack frequencies.

A point of diagnostic difficulty may arise with the cluster-tic syndrome (Solomon *et al.*, 1985; Watson and Evans, 1985). This syndrome is characterized by the combination of idiopathic trigeminal neuralgia and cluster headache. The pain of trigeminal neuralgia is lancinating, lasts for seconds, and is more common in the second and third divisions of the trigeminal nerve. It is often triggered by facial or buccal stimulation in the form of chewing, brushing teeth or touching the face. The cluster headache component spans the range of typical cluster headache, attacks lasting 45 min with autonomic features such as lacrimation and nasal blocking, through to shorter attacks of 30 s at a frequency of 40 per day, more suggestive of a paroxysmal hemicrania (Alberca and Ochoa, 1994). Carbamazepine may be useful in these patients as it is in trigeminal neuralgia. Given the report of the CPH-tic syndrome (Hannerz, 1993) which responded to indomethacin, it seems possible that various TACs may be associated with trigeminal neuralgia. To determine whether this is a distinct pathophysiological entity (Alberca and Ochoa, 1994) or the coincidental overlap of two entities, further study will be required (Solomon *et al.*, 1985; Watson and Evans, 1985). At this time we suggest that the disorder is classified under the TACs in a miscellaneous section until more data are available. Lastly, one is sometimes left with patients who have short-lasting pains not associated with autonomic features that are longer than a conventional stab. Such a patient may have episodic pains lasting 2–3 min that are severe, triggerable and responsive to carbamazepine (Mulleners and Verhagen, 1996). We would consider these part of the spectrum of trigeminal neuralgia.

While all of the TAC disorders may involve trigeminal–autonomic activation, the mechanisms which account for the differences in clinical profile and treatment response are unknown. There are simply insufficient data to answer these questions at the moment although it must be said, based on available data, that these headaches have more similarities than differences.

### **Pathophysiology of TACs**

We propose that the trigeminal–autonomic reflex can account for many of the features of cluster headache, CPH, EPH and SUNCT as well as the painful exacerbations of HC. This reflex pathway consists of a brainstem connection between the trigeminal nerve and facial (VIIth cranial nerve) parasympathetic outflow. It has been clearly shown in animal studies that stimulation of the trigeminal ganglion results in increased extracerebral (Goadsby *et al.*, 1986) and cerebral blood flow (Goadsby and Duckworth, 1987). For both the extracerebral (Lambert *et al.*, 1984) and the cerebral components (Goadsby and Duckworth, 1987), the major part of the vasodilator response is mediated via a reflex connection with the facial (VIIth cranial) nerve, the cranial parasympathetic outflow (Goadsby, 1989). Stimulation of the trigeminal ganglion leads to local release of trigeminal (CGRP and substance P) and parasympathetic (VIP) marker peptides



**Table 4** Differential diagnosis of short-lasting headache

Feature	Cluster headache	Chronic paroxysmal hemicrania	Episodic paroxysmal hemicrania	SUNCT	Idiopathic stabbing headache	Trigeminal neuralgia	Hemicrania continua	Hypnic headache
Gender(M:F)	9:1	1:3	1:1	8:1	F > M	F > M	1:1.8	5:3*
Pain								
Type	Boring	Throbbing/boring	Throbbing	Stabbing	Stabbing	Stabbing	Steady	Throbbing
Severity	Very severe	Very severe	Very severe	Mod. severe	Severe	Very severe	Mod. severe	Mod. severe
Location	Orbital	Orbital	Orbital	Orbital	Any part	V2/V3 > V1	Unilateral	Generalised
	Temporal	Temporal	Temporal	Temporal				
Attack duration	15–180 min	2–45 min	1–30 min	5–250 s	<1 s	<1 s	Continuous <sup>†</sup>	15–30 min
Attack frequency	1–8/day	1–40/day	3–30/day	1/day to 30/h	few to many/day	few to many/day	5–12/day	1–3/night
Autonomic features	+	+	+	+	–	–	+	–
Alcohol precipitated	+	+	+	+	–	–	–	–
Indomethacin	±	+	+	–	+	–	+	–*

\*Characteristically elderly patients aged 67–84 years (Newman *et al.*, 1990) responding to lithium (Raskin, 1988). <sup>†</sup>May have exacerbations (*see text*). V1/2/3 = ophthalmic/maxillary/mandibular divisions of the trigeminal innervation; + = effective; ± = effect not consistent; – = not effective.

in cats (Goadsby and Edvinsson, 1994a) and humans (Goadsby *et al.*, 1988). Moreover, trigeminal ganglion stimulation also leads to cerebral vasodilatation in humans (Tran-Dinh *et al.*, 1992). The trigeminal afferent arm of this reflex is clearly active in migraine (Goadsby *et al.*, 1990; Goadsby and Edvinsson, 1993; Gallai *et al.*, 1995) while the parasympathetic arm is active in cluster headache (Fig. 1) (Goadsby and Edvinsson, 1994b; Fanciullacci *et al.*, 1995). A single patient with CPH (Goadsby and Edvinsson, 1996) had elevated CGRP and VIP during a period of frequent severe attacks. The CGRP level rose from a control of 41 pmol/l while on indomethacin to a maximum of 123 pmol/l during pain. Similarly, the VIP level was 7 pmol/l on indomethacin rising to 32 pmol/l during an attack. These data are illustrated in Fig. 2 and compared with changes in migraine, which are less marked, and changes in cluster headache, which are similar. Based on these data, we believe that the trigemino-facial reflex is a key part of the pathophysiological expression of these syndromes. This anatomy links the clinical problems and suggests that these syndromes should broadly be classified together.

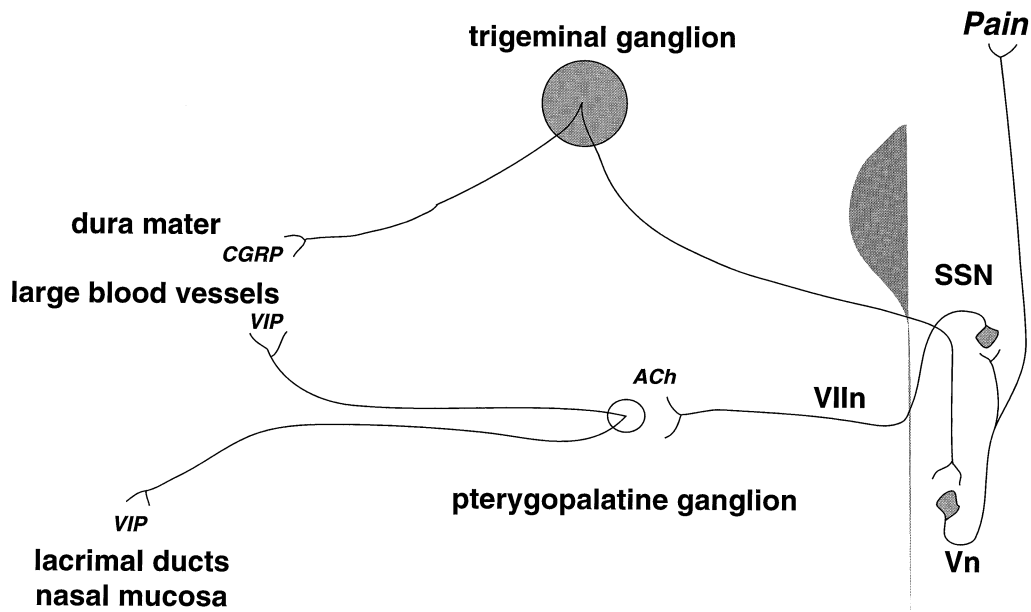
#### Issues surrounding the pathophysiology of TACs

If the biological model is correct, it should explain the available clinical and biological data and generate testable predictions. We postulated that trigeminal activation leads to reflex autonomic activation. At a clinical level, we would predict that there should be a pain threshold above which autonomic symptoms occur, modified by the highly somatotopic and functionally organized central connections of the trigeminovascular system. This roughly corresponds to the clinical observation of autonomic features during painful exacerbations of HC. It has been shown experimentally in cats (Lambert *et al.*, 1984) and in humans (Goadsby *et al.*, 1988) that, during trigeminal thermocoagulation, trigeminally

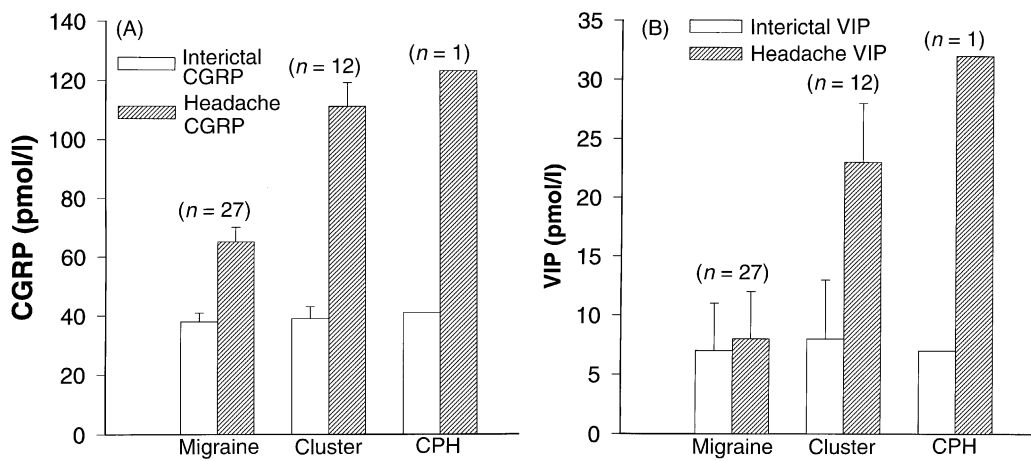
mediated changes in facial temperature or facial flushing respect the trigeminal somatotopic cutaneous innervation. Perhaps the trigemino-autonomic reflex follows a similar spatial pattern. Our most recent laboratory evidence suggests that intracranial pain-sensitive structures are indeed more potent at eliciting cerebral than non-cerebral changes in cranial blood flow when stimulated (Goadsby *et al.*, 1995). However, in both CPH and cluster pain, autonomic features and pain are sometimes dissociated. This dissociation requires either independent activation of trigeminal and parasympathetic pathways or differential modulation of their activity. At a biological level we would predict that, in animal models, changes in markers of trigeminal activation (i.e. CGRP) should predict changes in parasympathetic markers (i.e. VIP), which is what has been reported (Zagami *et al.*, 1990).

A clinical challenge to the model arises from the variation in patterns of autonomic symptoms from syndrome to syndrome. For example, conjunctival injection is usually quite prominent in SUNCT. There is also variation from individual to individual, just as in cluster headache patients lacrimation may be more prominent than nasal congestion and vice versa. Experimental studies must seek the anatomical or functional basis for such variation.

The triggering mechanism from the neck must be explained. Are there brainstem connections that again reflexly connect with the autonomic efferents? Is such activation prior to, or following, the activation of the second order trigeminal neurons? Lastly, what of indomethacin? What is so special in regard to the pharmacology of this NSAID? There is an old observation that indomethacin can alter the cerebral hypercapnic vasodilator response (Pickard *et al.*, 1977) which has a permissive component that involves generation of NO (nitric oxide) (Iadecola, 1992). Similarly, the facial (VIIth nerve) cranial parasympathetic outflow ganglia, sphenopalatine and otic ganglia contain NO synthase, and NO



**Fig. 1** Drawing of the anatomy of the trigemino-autonomic cephalgias. Both dura mater and large blood vessels are innervated largely by CGRP nerves that arise in the trigeminal ganglion. These bipolar nerves synapse in the trigeminal nucleus caudalis (Vn) including its caudal extension into the C<sub>1</sub> and C<sub>2</sub> dorsal horns of the cervical spinal cord. Pain signals are then transmitted via second order neurons to the thalamus and then to the cortex for appreciation as pain. There is a functional connection to the premotor parasympathetic neurons of the VIIth cranial (facial) nerve located in the superior salivatory nucleus (SSN). These neurons in turn give rise to preganglionic fibres that pass through the geniculate ganglion and synapse in the pterygopalatine (illustrated) and otic ganglia. Ganglionic transmission is by way of acetylcholine activating a nicotinic receptor. Postganglionic fibres transverse the greater superficial petrosal to innervate both the cranial vessels and provide parasympathetic autonomic innervation to structures, such as the lacrimal glands and nasal mucosa, accounting for the marked parasympathetic autonomic features seen in these headaches.



**Fig. 2** The figure demonstrates the changes in (A) calcitonin gene-related peptide (CGRP) and (B) vasoactive intestinal polypeptide (VIP) in cranial venous blood during attacks of migraine (with and without aura), cluster headache and chronic paroxysmal hemicrania (CPH). The level of elevation of CGRP and VIP in the CPH patient is comparable with that seen in cluster headache patients (Goadsby and Edvinsson, 1994b; Fanciullacci *et al.*, 1995).

**Table 5** Suggested reclassification for trigeminal autonomic cephalgias

---

<b>3. Trigeminal Autonomic Cephalgias (TACs)</b>
3.1 Cluster headache
3.1.1 Episodic cluster headache
3.1.2 Chronic cluster headache
3.2 Paroxysmal hemicranias (Table 6)
3.2.1 Episodic paroxysmal hemicrania
3.2.2 Chronic paroxysmal hemicrania
3.3 Shortlasting neuralgiform headache with conjunctival injection and tearing (Table 7)
3.4 Hemicrania continua (Table 8)

---

generation is involved in the vasodilator responses of this system (Goadsby *et al.*, 1996). Further experiments are required to determine whether indomethacin attenuates the facial nerve cranial parasympathetic outflow directly.

### TACs and their classification

A headache classification system should be reliable, valid, comprehensive and generalizable (Lipton *et al.*, 1993). Although the IHS system (Headache Classification Committee of the IHS, 1988) represents an enormous leap forward, is not comprehensive in that it excludes a number of increasingly recognized primary headache disorders. These exclusions are partially historical and we consider that some of the excluded syndromes are ready for inclusion. The overlapping clinical features and possible shared pathophysiological mechanisms at play in cluster headache, the paroxysmal hemicranias and SUNCT syndrome support the suggestion that they be grouped together for the purpose of classification. Such a re-classification is summarized in Table 5 with section 3 of the current system being renamed as the trigeminal–autonomic cephalgias. This would include section 3.1 as cluster headache, 3.2 as paroxysmal hemicrania, 3.3 as SUNCT and 3.4 as hemicrania continua. For the moment, it is unclear whether they represent a distinct family of disorders characterized by trigemino-autonomic activation, or if they are separate entities, linked by a final common pathway of expression. Since all headache, by definition, activates trigeminal afferents, and given that there are likely to be functional connections between the trigeminal nucleus and the cranial parasympathetic nuclei, the clinical similarities are hardly surprising. The syndromes will be better studied separately until their pathophysiology is understood and the common mechanisms elucidated. The rarity of the headaches discussed has severely limited their study and acknowledgement.

The criteria for episodic and chronic cluster headache are unchanged. We present criteria for paroxysmal hemicranias, analagous to the structure of the cluster headache criteria (Table 6) as has been suggested (Newman *et al.*, 1994). The most problematic aspect of the case definition is the role of indomethacin responsiveness in defining the disorder. Virtually every case responds promptly to treatment with indo-

**Table 6** Paroxysmal hemicranias

---

### 3.2 Paroxysmal Hemicrania

**Comment:** This section replaces the previous section 3.2 by dividing paroxysmal hemicrania into an episodic and a chronic form.

#### 3.2.1 Chronic Paroxysmal Hemicrania

**Diagnostic criteria:**

- A. At least 30 attacks fulfilling B–E
- B. Attacks of severe unilateral orbital, supraorbital and/or temporal pain always on the same side lasting 2–45 min
- C. Attack frequency above 5 a day for more than half the time (periods with lower frequency may occur)
- D. Pain is associated with at least one of the following signs/symptoms on the pain side:

- 1. Conjunctival injection
- 2. Lacrimation
- 3. Nasal congestion
- 4. Rhinorrhea
- 5. Ptosis
- 6. Eyelid oedema

- E. At least one of the following:

- 1. There is no suggestion of one of the disorders listed in groups 5–11.
- 2. Such a disorder is suggested but excluded by appropriate investigations.
- 3. Such a disorder is present, but the first headache attacks do not occur in close temporal relation to the disorder.

*Note:* Most cases respond rapidly and absolutely to indomethacin (usually in doses of 150 mg/day or less)

#### 3.2.2 Episodic Paroxysmal Hemicrania

**Diagnostic criteria:**

- A. At least 30 attacks fulfilling B–F
- B. Attacks of severe unilateral orbital or temporal pain, or both, that is always unilateral and lasts from 1–30 min
- C. An attack frequency of 3 or more a day
- D. Clear intervals between bouts of attacks that may last from months to years
- E. Pain is associated with at least one of the following signs or symptoms on the painful side:

- 1. Conjunctival injection
- 2. Lacrimation
- 3. Nasal congestion
- 4. Rhinorrhea
- 5. Ptosis
- 6. Eyelid oedema

- F. At least one of the following:

- 1. There is no suggestion of one of the disorders listed in groups 5–11.
- 2. Such a disorder is suggested but excluded by appropriate investigations.
- 3. Such a disorder is present, but the first headache attacks do not occur in close temporal relation to the disorder.

*Note:* In most cases responds rapidly and absolutely to indomethacin (usually 150 mg/day or less).

---

methacin but this definition precludes diagnosis prior to a therapeutic trial or results in reclassification of patients who fail to respond to treatment. It is our view that the indomethacin response should be a confirmatory criteria, not an absolute requirement.

SUNCT has been included within the classification of TACs. The criteria presented in Table 7 permit the classifica-

**Table 7** Criteria for SUNCT**3.3 Short-lasting unilateral neuralgiform headache with conjunctival injection and tearing (SUNCT)**

**Comment:** This section will replace the current unclassified section which then becomes section 3.5.

**Diagnostic criteria:**

- A. At least 30 attacks fulfilling B–E
- B. Attacks of unilateral moderately severe orbital or temporal stabbing or throbbing pain lasting from 15–120 s
- C. Attack frequency from 3 to 100/day
- D. Pain is associated with at least one of the following signs or symptoms of the affected side with feature 1 being most often present and very prominent:
  1. Conjunctival injection
  2. Lacrimation
  3. Nasal congestion
  4. Rhinorrhea
  5. Ptosis
  6. Eyelid oedema
- E. At least one of the following:
  1. There is no suggestion of one of the disorders listed in groups 5–11.
  2. Such a disorder is suggested but excluded by appropriate investigations.
  3. Such a disorder is present, but the first headache attacks do not occur in close temporal relation to the disorder.

**Clinical note:** The literature suggests that the most common secondary cause of SUNCT would be a lesion in the posterior fossa.

tion of cases seen by the authors and of the published reports. Inclusion of HC within TACs is more problematic and is based on the broad view that most primary headache disorders are phenotypically part of a spectrum. The criteria presented in Table 8 are based on validation studies that have now been published (Silberstein *et al.*, 1996). Hypnic headache is proposed to be classified in the section of Miscellaneous Headache (Table 9) until more information is forthcoming.

## Conclusions

Short-lasting headaches with autonomic features represent a rare yet important and certainly interesting spectrum of the primary headache syndromes. Publication of further cases, and observations on their pathophysiology, will assist in understanding the conditions and perhaps in clarifying aspects of the physiology of the cerebral circulation.

## Acknowledgements

The author thanks Professor James Lance for his thoughtful comments on this manuscript. This work has been supported by the Wellcome Trust and the Migraine Trust. P.J.G. is a Wellcome Senior Research Fellow.

**Table 8** Criteria for hemicrania continua**3.4 Hemicrania continua**

**Comment:** These headaches are usually non-remitting but rare cases of remission are reported. This clinical problem can be seen in the context of medication overuse which may alter the clinical features and affect response to treatment. Whether this headache type can be further sub-divided according to length and persistence of history is yet to be determined (Newman *et al.*, 1994).

**Diagnostic criteria:**

- A. Headache present for at least 1 month
- B. Unilateral headache
- C. Pain has the following qualities
  1. Continuous but fluctuating
  2. Moderate severity
  3. lack of precipitating mechanisms
- D. Headache must have either one of
  1. Complete response to indomethacin or
  2. One of the following autonomic features in association with exacerbations of pain:
    1. Conjunctival injection
    2. Lacrimation
    3. Nasal congestion
    4. Rhinorrhea
    5. Ptosis
    6. Eyelid oedema
- E. At least one of the following:
  1. There is no suggestion of one of the disorders listed in groups 5–11.
  2. Such a disorder is suggested but excluded by appropriate investigations.
  3. Such a disorder is present, but the first headache attacks do not occur in close temporal relation to the disorder.

**Table 9** Suggested criteria for hypnic headache\***4.7 Hypnic headache****Diagnostic criteria:**

- A. Headaches occur at least 15 times per month for at least one month.
- B. Headaches awaken patient from sleep.
- C. Attack duration of 5–60 min.
- D. Pain is generalized or bilateral.
- E. Pain not associated with autonomic features.
- F. At least one of the following:
  1. There is no suggestion of one of the disorders listed in groups 5–11.
  2. Such a disorder is suggested but excluded by appropriate investigations.
  3. Such a disorder is present, but the first headache attacks do not occur in close temporal relation to the disorder.

*Note:* A rapid clinical response to lithium at bedtime is usually expected.

\*To be added as section to 4.7 to the current IHS classification of Miscellaneous headaches unassociated with a structural cause

## References

- Alberca R, Ochoa JJ. Cluster tic syndrome. *Neurology* 1994; 44: 996–9.
- Alberca R, Sureda B, Marquez C, Navarro A. Episodic paroxysmal hemicrania or chronic paroxysmal hemicrania in a pre-chronic state? [Spanish]. *Neurologia* 1991; 6: 219–21.
- Antonaci F, Sand T, Sjaastad O. Hemicrania continua and chronic paroxysmal hemicrania: a comparison of pupillometric findings. *Funct Neurol* 1992; 7: 385–9.
- Antonaci F, Sandrini G, Danilov A, Sand T. Neurophysiological studies in chronic paroxysmal hemicrania and hemicrania continua. *Headache* 1994; 34: 479–83.
- Antonaci F. The sweating pattern in 'hemicrania continua'. A comparison with chronic paroxysmal hemicrania. *Funct Neurol* 1991; 6: 371–5.
- Antonaci F. Chronic paroxysmal hemicrania and hemicrania continua: orbital phlebography and MRI studies. *Headache* 1994; 34: 32–4.
- Antonaci F, Sjaastad O. Chronic paroxysmal hemicrania (CPH): a review of the clinical manifestations. [Review]. *Headache* 1989; 29: 648–56.
- Antonaci F, Sjaastad O. Hemicrania continua: a possible symptomatic case, due to mesenchymal tumor. *Funct Neurol* 1992; 7: 471–4.
- Becser N, Berky M. SUNCT syndrome: a Hungarian case. *Headache* 1995; 35: 158–60.
- Blau JN, Engel H. Episodic paroxysmal hemicrania: a further case and review of the literature [see comments]. [Review]. *J Neurol Neurosurg Psychiatry* 1990; 53: 343–4. Comment in: *J Neurol Neurosurg Psychiatry* 1991; 54: 666.
- Bogucki A, Niewodniczy A. Case report: chronic cluster headache with unusual high frequency of attacks: differential diagnosis with CPH. *Headache* 1984; 24: 150–1.
- Bogucki A, Szymanska R, Braciak W. Chronic paroxysmal hemicrania: lack of a pre-chronic stage. *Cephalalgia* 1984; 4: 187–9.
- Bouhassira D, Attal N, Esteve M, Chauvin M. 'SUNCT' syndrome. A case of transformation from trigeminal neuralgia? *Cephalalgia* 1994; 14: 168–70.
- Bovim G, Jenssen G, Ericson K. Orbital phlebography: a comparison between cluster headache and other headaches [see comments]. *Headache* 1992; 32: 408–12. Comment in: *Headache* 1993; 33: 161–2.
- Broske D, Lenn NJ, Cantos E. Chronic paroxysmal hemicrania in a young child: possible relation to ipsilateral occipital infarction. *J Child Neurol* 1993; 8: 235–6.
- Bussone G, Leone M, Dalla Volta G, Strada L, Gasparotti R, Di Monda V. Short-lasting unilateral neuralgiform headache attacks with tearing and conjunctival injection: the first 'symptomatic' case? *Cephalalgia* 1991; 11: 123–7.
- Carvalho DSS, Salvesen R, Sand T, Smith SE, Sjaastad O. Chronic paroxysmal hemicrania. XIII. The pupillometric pattern. *Cephalalgia* 1988; 8: 219–26.
- Coria F, Claveria LE, Jimenez-Jimenez FJ, de Seijas EV. Episodic paroxysmal hemicrania responsive to calcium channel blockers [letter]. *J Neurol Neurosurg Psychiatry* 1992; 55: 166.
- Cremer PD, Halmagyi GM, Goadsby PJ. Secondary cluster headache responsive to sumatriptan. *J Neurol Neurosurg Psychiatry* 1995; 59: 633–4.
- Dahl A, Russell D, Nyberg-Hansen R, Rootwelt K. Cluster headache: transcranial Doppler ultrasound and rCBF studies. *Cephalalgia* 1990; 10: 87–94.
- Dahlof C. Subcutaneous sumatriptan does not abort attacks of chronic paroxysmal hemicrania (CPH). *Headache* 1993; 33: 201–2.
- De Benedittis G. SUNCT syndrome associated with cavernous angioma of the brain stem [abstract]. *Cephalalgia* 1995; 15 Suppl 14: 28.
- Delreux V, Kevers L, Callewaert A. Hemicranie paroxystique inaugurant un syndrome de Pancoast [see comments]. *Rev Neurol (Paris)* 1989; 145: 151–2. Comment in: *Rev Neurol (Paris)* 1990; 146: 770.
- Drummond PD. Thermographic and pupillary asymmetry in chronic paroxysmal hemicrania. A case study. *Cephalalgia* 1985; 5: 133–6.
- Drummond PD. Autonomic disturbances in cluster headache. *Brain* 1988; 111: 1199–209.
- Drummond PD, Lance JW. Pathological sweating and flushing accompanying the trigeminal lacrimal reflex in patients with cluster headache and in patients with a confirmed site of cervical sympathetic deficit. Evidence for parasympathetic cross-innervation. *Brain* 1992; 115: 1429–45.
- Edmeads JG. Brain tumors and other space occupying lesions. In: Goadsby PJ, Silberstein SD, editors. *Headache*. New York: Butterworth-Heinemann, 1997.
- Fanciullacci M, Alessandri M, Figini M, Geppetti P, Michelacci S. Increase in plasma calcitonin gene-related peptide from the extracerebral circulation during nitroglycerin-induced cluster headache attack. *Pain* 1995; 60: 119–23.
- Fragoso YD, Seim S, Stovner LJ, Mack M, Bjerve KS, Sjaastad O. Arachidonic acid metabolism in polymorphonuclear cells in headaches. A methodologic study. *Cephalalgia* 1988; 8: 149–55.
- Gallai V, Sarchielli P, Floridi A, Franceschini M, Codini M, Glioti G, et al. Vasoactive peptide levels in the plasma of young migraine patients with and without aura assessed both interictally and ictally [see comments]. *Cephalalgia* 1995; 15: 384–90. Comment in: *Cephalalgia* 1995; 15: 333–4.
- Gawel MJ, Rothbart P. Chronic paroxysmal hemicrania which appears to arise from either third ventricle pathology or internal carotid artery pathology [letter; comment]. *Cephalalgia* 1992; 12: 327. Comment on: *Cephalalgia* 1992; 12: 111–3.
- Geaney DP. Indomethacin-responsive episodic cluster headache. *J Neurol Neurosurg Psychiatry* 1983; 46: 860–1.
- Ghose RR. SUNCT syndrome [letter]. *Med J Aust* 1995; 162: 667–8.
- Gladstein J, Holden EW, Peralta L. Chronic paroxysmal hemicrania in a child [see comments]. [Review]. *Headache* 1994; 34: 519–20. Comment in: *Headache* 1995; 35: 234.
- Goadsby PJ. Effect of stimulation of facial nerve on regional

- cerebral blood flow and glucose utilization in cats. *Am J Physiol* 1989; 257: R517-1.
- Goadsby PJ. The clinical profile of sumatriptan: cluster headache. *Eur Neurol* 1994; 34 Suppl 2: 35-9.
- Goadsby PJ, Duckworth JW. Effect of stimulation of trigeminal ganglion on regional cerebral blood flow in cats. *Am J Physiol* 1987; 253: R270-4.
- Goadsby PJ, Edvinsson L. The trigeminovascular system and migraine: studies characterizing cerebrovascular and neuropeptide changes seen in humans and cats. *Ann Neurol* 1993; 33: 48-56.
- Goadsby PJ, Edvinsson L. Peripheral and central trigeminovascular activation in cat is blocked by the serotonin (5HT)-1D receptor agonist 311C90. *Headache* 1994a; 34: 394-9.
- Goadsby PJ, Edvinsson L. Human in vivo evidence for trigeminovascular activation in cluster headache. *Brain* 1994b; 117: 427-34.
- Goadsby PJ, Edvinsson L. Neuropeptide changes in a case of chronic paroxysmal hemicrania—evidence for trigemino-parasympathetic activation. *Cephalalgia* 1996; 16: 448-50.
- Goadsby PJ, Lance JW. Brain stem effects on intra- and extracerebral circulations. Relation to migraine and cluster headache. In: Olesen J, Edvinsson L, editors. *Basic mechanisms of headache*. Amsterdam: Elsevier, 1988: 413-27.
- Goadsby PJ, Edvinsson L, Ekman R. Release of vasoactive peptides in the extracerebral circulation of humans and the cat during activation of the trigeminovascular system. *Ann Neurol* 1988; 23: 193-6.
- Goadsby PJ, Edvinsson L, Ekman R. Vasoactive peptide release in the extracerebral circulation of humans during migraine headache. *Ann Neurol* 1990; 28: 183-7.
- Goadsby PJ, Zagami AS, Lambert GA. Neural processing of craniovascular pain: a synthesis of the central structures involved in migraine. *Headache* 1991; 31: 365-71.
- Goadsby PJ, Hoskin KL, Knight YE, Butler P. Selective activation of the trigeminovascular system by stimulation of the superior sagittal sinus: cerebral vs extracerebral blood flow changes. *J Cereb Blood Flow Metab* 1995; 15 Suppl 1: S164.
- Goadsby PJ, Uddman R, Edvinsson L. Cerebral vasodilatation in the cat involves nitric oxide from parasympathetic nerves. *Brain Res* 1996; 707: 110-8.
- Hannerz J. Pathoanatomic studies in a case of Tolosa-Hunt syndrome. *Cephalalgia* 1988; 8: 25-30.
- Hannerz J. Trigeminal neuralgia with chronic paroxysmal hemicrania: the CPH-tic syndrome. *Cephalalgia* 1993; 13: 361-4.
- Hannerz J, Jogestrand T. Intracranial hypertension and sumatriptan efficacy in a case of chronic paroxysmal hemicrania which became bilateral. (The mechanism of indomethacin in CPH). *Headache* 1993; 33: 320-3.
- Hannerz J, Ericson K, Bergstrand G. Chronic paroxysmal hemicrania: orbital phlebography and steroid treatment. A case report. *Cephalalgia* 1987; 7: 189-92.
- Hannerz J, Greitz D, Hansson P, Ericson K. SUNCT may be another manifestation of orbital venous vasculitis. *Headache* 1992; 32: 384-9.
- Headache Classification Committee of the International Headache Society. Classification and diagnostic criteria for headache disorders, cranial neuralgias and facial pain. *Cephalalgia* 1988; 8 Suppl 7: 1-96.
- Hochman MS. Chronic paroxysmal hemicrania: a new type of treatable headache. *Am J Med* 1981; 71: 169-70.
- Hoes MJAJM, Bruyn GW, Vielvoeye GJ. The Tolosa-Hunt syndrome—literature review: seven new cases and a hypothesis. [Review]. *Cephalalgia* 1981; 1: 181-94.
- Horven I, Russell D, Sjaastad O. Ocular blood flow changes in cluster headache and chronic paroxysmal hemicrania. *Headache* 1989; 29: 373-6.
- Hunt WE, Meagher JN, LeFever HE, Zeman W. Painful ophthalmoplegia. Its relation to indolent inflammation of the cavernous sinus. *Neurology* 1961; 11: 56-62.
- Iadecola C. Does nitric oxide mediate the increases in cerebral blood flow elicited by hypercapnia? *Proc Natl Acad Sci USA* 1992; 89: 3913-6.
- Iordanidis T, Sjaastad O. Hemicrania continua: a case report. *Cephalalgia* 1989; 9: 301-3.
- Joubert J. Cluster headache in black patients. A report of 7 cases. *S Afr Med J* 1988; 73: 552-4.
- Joubert J. Hemicrania continua in a black patient—the importance of the non-continuous stage. *Headache* 1991; 31: 480-2.
- Joubert J, Powell D, Djikowski J. Chronic paroxysmal hemicrania in a South African black. A case report. *Cephalalgia* 1987; 7: 193-6.
- Kaube H, Keay KA, Hoskin KL, Bandler R, Goadsby PJ. Expression of c-Fos-like immunoreactivity in the caudal medulla and upper cervical spinal cord following stimulation of the superior sagittal sinus in the cat. *Brain Res* 1993; 629: 95-102.
- Krabbe AA, Henriksen L, Olesen J. Tomographic determination of cerebral blood flow during attacks of clusterheadache. *Cephalalgia* 1984; 4: 17-23.
- Kruszewski P. Shortlasting, unilateral, neuralgiform headache attacks with conjunctival injection and tearing (SUNCT syndrome): V. Orbital phlebography. *Cephalalgia* 1992; 12: 387-9.
- Kruszewski P, Fasano ML, Brubakk AO, Shen JM, Sand T, Sjaastad O. Shortlasting, unilateral, neuralgiform headache attacks with conjunctival injection, tearing, and subclinical forehead sweating SUNCT syndrome: II. Changes in heart rate and arterial blood pressure during pain paroxysms. *Headache* 1991; 31: 399-405.
- Kruszewski P, Sand T, Shen JM, et al. Short-lasting, unilateral, neuralgiform headache attacks with conjunctival injection and tearing (SUNCT) syndrome: IV. Respiratory sinus arrhythmia during and outside paroxysms. *Headache* 1992; 32: 377-83.
- Kruszewski P, Zhao JM, Shen JM, Sjaastad O. SUNCT syndrome: forehead sweating pattern. *Cephalalgia* 1993; 13: 108-13.
- Kruszewski P, White LR, Shen JM, Pareja JA, Zhao JM, Schaanning J, et al. Respiratory studies in SUNCT syndrome. *Headache* 1995; 35: 344-8.

- Kudrow L. Cluster headache: mechanisms and management. Oxford: Oxford University Press, 1980.
- Kudrow L. Response of cluster headache attacks to oxygen inhalation. *Headache* 1981; 21: 1–4.
- Kudrow DB, Kudrow L. Successful aspirin prophylaxis in a child with chronic paroxysmal hemicrania. *Headache* 1989; 29: 280–1.
- Kudrow L, Esperanca P, Vijayan N. Episodic paroxysmal hemicrania? *Cephalalgia* 1987; 7: 197–201.
- Kuritzky A. Indomethacin-resistant hemicrania continua. *Cephalalgia* 1992; 12: 57–9.
- Lambert GA, Bogduk N, Goadsby PJ, Duckworth JW, Lance JW. Decreased carotid arterial resistance in cats in response to trigeminal stimulation. *J Neurosurg* 1984; 61: 307–15.
- Lance JW. Mechanism and management of headache. 5th ed. Oxford: Butterworth-Heinemann, 1993.
- Leone M, Filippini G, D'Amico D, Farinotti M, Bussone G. Assessment of International Headache Society diagnostic criteria: a reliability study. *Cephalalgia* 1994; 14: 280–4.
- Lipton RB, Stewart WF, Merikangas KR. Reliability in headache diagnosis. *Cephalalgia* 1993; 13 Suppl 12: 29–33.
- MacMillan JC, Nukada H. Chronic paroxysmal hemicrania. *NZ Med J* 1989; 102: 251–2.
- Martins IP, Baeta E, Paiva T, Campos J, Gomes L. Headaches during intracranial endovascular procedures: a possible model of vascular headache. *Headache* 1993; 33: 227–33.
- Mathew NT, Reuveni U, Perez F. Transformed or evolutive migraine. *Headache* 1987; 27: 102–6.
- Medina JL. Organic headaches mimicking chronic paroxysmal hemicrania. *Headache* 1992; 32: 73–4.
- Meyer JS, Kawamura J, Terayama Y. CT-CBF and <sup>133</sup>Xe inhalation cerebral blood flow studies in cluster headache. In: Olesen J, editor. *Migraine and other headaches. The vascular mechanisms*. New York: Raven Press, 1991: 305–10.
- Micieli G, Cavallini A, Facchinetti F, Sances G, Nappi G. Chronic paroxysmal hemicrania: a chronobiological study (case report). *Cephalalgia* 1989; 9: 281–6.
- Mongini F, Caselli C, Macri V, Tetti C. Thermographic findings in cranio-facial pain. *Headache* 1990; 30: 497–504.
- Morales F, Mostacero E, Marta J, Sanchez S. Vascular malformation of the cerebellopontine angle associated with 'SUNCT' syndrome. *Cephalalgia* 1994; 14: 301–2.
- Mulleners WM, Verhagen WIM. Cluster-tic syndrome [letter]. *Neurology* 1996; 47: 302.
- Newman LC, Lipton RB, Solomon S. The hypnic headache syndrome: a benign headache disorder of the elderly. *Neurology* 1990; 40: 1904–5.
- Newman LC, Gordon ML, Lipton RB, Kanner R, Solomon S. Episodic paroxysmal hemicrania: two new cases and a literature review [see comments]. [Review]. *Neurology* 1992a; 42: 964–6. Comment in: *Neurology* 1994; 44: 2215–6.
- Newman LC, Herskovitz S, Lipton RB, Solomon S. Chronic paroxysmal headache: two cases with cerebrovascular disease. *Headache* 1992b; 32: 75–6.
- Newman LC, Lipton RB, Russell M, Solomon S. Hemicrania continua: attacks may alternate sides [see comments]. *Headache* 1992c; 32: 237–8.
- Newman LC, Lipton RB, Solomon S. Hemicrania continua: ten new cases and a review of the literature [see comments]. *Neurology* 1994; 44: 2111–4.
- Pareja JA. Chronic paroxysmal hemicrania: dissociation of the pain and autonomic features. *Headache* 1995a; 35: 111–3.
- Pareja JA. Hemicrania continua: remitting stage evolved from the chronic form. *Headache* 1995b; 35: 161–2.
- Pareja JA. Chronic paroxysmal hemicrania: dissociation of the pain and autonomic features. *Headache* 1995b; 35: 111–3.
- Pareja J, Pareja J. Chronic paroxysmal hemicrania coexisting with migraine. Differential response to pharmacological treatment. *Headache* 1992; 32: 77–8.
- Pareja JA, Sjaastad O. SUNCT syndrome in the female. *Headache* 1994; 34: 217–20.
- Pareja JA, Palomo T, Gorriti MA, Pareja J, Espejo J. 'Hemicrania episodica'—a new type of headache or a pre-chronic stage of hemicrania continua? *Headache* 1990; 30: 344–6.
- Pareja JA, Pareja J, Palomo T, Caballero V, Pamo M. SUNCT syndrome: repetitive and overlapping attacks. *Headache* 1994; 34: 114–6.
- Pareja JA, Kruszewski P, Sjaastad O. SUNCT syndrome: trials of drugs and anesthetic blockades. *Headache* 1995; 35: 138–42.
- Pareja JA, Joubert J, Sjaastad O. SUNCT syndrome. Atypical temporal patterns. *Headache* 1996a; 36: 108–10.
- Pareja JA, Shen JM, Kruszewski P, Caballero V, Pamo M, Sjaastad O. SUNCT syndrome: duration, frequency, and temporal distribution of attacks. *Headache* 1996b; 36: 161–5.
- Pasquier F, Leys D, Petit H. 'Hemicrania continua': the first bilateral case? *Cephalalgia* 1987; 7: 169–70.
- Pickard JD, MacDonell LA, MacKenzie ET, Harper AM. Response of the cerebral circulation in baboons to changing perfusion pressure after indomethacin. *Circ Res* 1977; 40: 198–203.
- Pollmann W, Pfaffenrath V. Chronic paroxysmal hemicrania: the first possible bilateral case. *Cephalalgia* 1986; 6: 55–7.
- Poughias L, Aasly J. SUNCT syndrome: cerebral SPECT images during attacks. *Headache* 1995; 35: 143–5.
- Price RW, Posner JB. Chronic paroxysmal hemicrania: a disabling headache syndrome responding to indomethacin. *Ann Neurol* 1978; 3: 183–4.
- Rapoport AM, Sheftell FD, Baskin SM. Chronic paroxysmal hemicrania: case report of the second known definite occurrence in a male. *Cephalalgia* 1981; 1: 67–9.
- Raskin NH. The hypnic headache syndrome. *Headache* 1988; 28: 534–6.
- Russell D. Chronic paroxysmal hemicrania: severity, duration and time of occurrence of attacks. *Cephalalgia* 1984; 4: 53–6.

- Russell D, Storstein L. Chronic paroxysmal hemicrania: heart rate changes and ECG rhythm disturbances. A computerized analysis of 24h ambulatory ECG recordings. *Cephalalgia* 1984; 4: 135–44.
- Russell D, Christoffersen B, Horven I. Chronic paroxysmal hemicrania: a case report. *Headache* 1978; 18: 99–100.
- Saunte C. Chronic paroxysmal hemicrania: salivation, tearing and nasal secretion. *Cephalalgia* 1984; 4: 25–32.
- Schlake HP, Bottger IG, Grottemeyer KH, Husstedt IW, Schober O. Single photon emission computed tomography (SPECT) with <sup>99m</sup>Tc-HMPAO (hexamethyl propylenamino oxime) in chronic paroxysmal hemicrania—a case report. *Cephalalgia* 1990; 10: 311–5.
- Shabbir N, McAbee G. Adolescent chronic paroxysmal hemicrania responsive to verapamil monotherapy. *Headache* 1994; 34: 209–10.
- Sheftell FD. Chronic daily headache. [Review]. *Neurology* 1992; 42 (3 Suppl 2): 32–6.
- Shen JM. Transcranial Doppler sonography in chronic paroxysmal hemicrania. *Headache* 1993; 33: 493–6.
- Shen JM, Johnsen HJ. SUNCT syndrome: estimation of cerebral blood flow velocity with transcranial Doppler ultrasonography. *Headache* 1994; 34: 25–31.
- Silberstein SD, Lipton RB, Solomon S, Mathew NT. Classification of daily and near-daily headaches: proposed revisions to the IHS criteria. [Review]. *Headache* 1994; 34: 1–7.
- Silberstein SD, Lipton RB, Sliwinski M. Classification of daily and near-daily headaches: a field study of revised IHS criteria. *Neurology* 1996. In press.
- Sjaastad O. Chronic paroxysmal hemicrania (CPH). In: Vinken PJ, Bruyn GW, Klawans HL, Rose FC, editors. *Handbook of clinical neurology*, Vol. 48. Amsterdam: Elsevier Science, 1986: 257–66.
- Sjaastad O. Cluster headache syndrome. London: W.B. Saunders, 1992.
- Sjaastad O, Dale I. Evidence for a new (?), treatable headache entity. *Headache* 1974; 14: 105–8.
- Sjaastad O, Spierings EL. ‘Hemicrania continua’: another headache absolutely responsive to indmethacin. *Cephalalgia* 1984; 4: 65–70.
- Sjaastad O, Antonaci F. Chronic paroxysmal hemicrania: a case report. Long-lasting remission in the chronic stage. *Cephalalgia* 1987; 7: 203–5.
- Sjaastad O, Tjorstad K. Hemicrania continua: a third Norwegian case. *Cephalalgia* 1987; 7: 175–7.
- Sjaastad O, Shen JM. Cluster headache. Our current concepts [Review]. *Acta Neurol (Napoli)* 1991; 13: 500–5.
- Sjaastad O, Antonaci F. Chronic paroxysmal hemicrania (CPH) and hemicrania continua: transition from one stage to another. *Headache* 1993; 33: 551–4.
- Sjaastad O, Egge K, Horven I, Kayed K, Lund-Roland L, Russell D, et al. Chronic paroxysmal hemicrania: mechanical precipitation of attacks. *Headache* 1979; 19: 31–6.
- Sjaastad O, Russell D, Saunte C, Horven I. Chronic paroxysmal hemicrania. VI. Precipitation of attacks. Further studies on the precipitation mechanism. *Cephalalgia* 1982; 2: 211–4.
- Sjaastad O, Saunte C, Graham JR. Chronic paroxysmal hemicrania. VII. Mechanical precipitation of attacks: new cases and localization of trigger points. *Cephalalgia* 1984; 4: 113–8.
- Sjaastad O, Saunte C, Salvesen R, Fredriksen TA, Seim A, Roe OD, et al. Shortlasting unilateral neuralgiform headache attacks with conjunctival injection, tearing, sweating, and rhinorrhea. *Cephalalgia* 1989; 9: 147–56.
- Sjaastad O, Zhao JM, Kruszewski P, Stovner LJ. Short-lasting unilateral neuralgiform headache attacks with conjunctival injection, tearing, etc. (SUNCT): III. Another Norwegian case. *Headache* 1991; 31: 175–7.
- Sjaastad O, Kruszewski P, Fostad K, Elsas T, Qvigstad G. SUNCT syndrome: VII. Ocular and related variables. *Headache* 1992; 32: 489–95.
- Sjaastad O, Stovner LJ, Stolt-Nielsen A, Antonaci F, Fredriksen TA. CPH and hemicrania continua: requirements of high indomethacin dosages—an ominous sign? *Headache* 1995; 35: 363–7.
- Solomon S, Newman LC. Chronic paroxysmal hemicrania in a child? [letter; comment]. *Headache* 1995; 35: 234. Comment on: *Headache* 1994; 34: 519–20.
- Solomon S, Apfelbaum RI, Guglielmo KM. The cluster-tic syndrome and its surgical therapy. *Cephalalgia* 1985; 5: 83–9.
- Spierings EL. The chronic paroxysmal hemicrania concept expanded. *Headache* 1988; 28: 597–8.
- Spierings EL. Episodic and chronic paroxysmal hemicrania. [Review]. *Clin J Pain* 1992; 8: 44–8.
- Stein HJ, Rogado AZ. Headache rounds. Chronic paroxysmal hemicrania: two new patients. *Headache* 1980; 20: 72–6.
- Sumatriptan Cluster Headache Study Group. Treatment of acute cluster headache with sumatriptan [see comments]. *N Engl J Med* 1991; 325: 322–6. Comment in: *N Engl J Med* 1991; 325: 353–4.
- Tehindrazanarivelo AD, Visy JM, Boussier MG. Ipsilateral cluster headache and chronic paroxysmal hemicrania: two case reports. *Cephalalgia* 1992; 12: 318–20.
- Tolosa E. Periarteritic lesions of the carotid siphon with the clinical features of a carotid infraclinoidal aneurysm. *J Neurol Neurosurg Psychiatry* 1954; 17: 300–2.
- TranDinh YR, Thurel C, Cunin G, Serrie A, Seylaz J. Cerebral vasodilation after the thermocoagulation of the trigeminal ganglion in humans. *Neurosurgery* 1992; 31: 658–62.
- Trucco M, Antonaci F, Sandrini G. Hemicrania continua: a case responsive to piroxicam-betacyclodextrin. *Headache* 1992; 32: 39–40.
- Vijayan N. Symptomatic chronic paroxysmal hemicrania [see comments]. *Cephalalgia* 1992; 12: 111–3. Comment in: *Cephalalgia* 1992; 12: 327.
- Vincent MB, Ekman R, Edvinsson L, Sand T, Sjaastad O. Reduction of calcitonin gene-related peptide in jugular blood following electrical stimulation of rat greater occipital nerve. *Cephalalgia* 1992; 12: 275–9.
- Warner JS, Wamil AW, McLean MJ. Acetazolamide for the treatment of chronic paroxysmal hemicrania. *Headache* 1994; 34: 597–9.



Watson P, Evans R. Cluster-ticsyndrome. *Headache* 1985; 25: 123–6.

Young WB, Silberstein SD. Hemicrania continua and symptomatic medication overuse. *Headache* 1993; 33: 485–7.

Zagami AS, Goadsby PJ, Edvinsson L. Stimulation of the superior sagittal sinus in the cat causes release of vasoactive peptides. *Neuropeptides* 1990; 16: 69–75.

Zhao JM, Sjaastad O. SUNCT syndrome: VIII. Pupillary reaction and corneal sensitivity. *Funct Neurol* 1993; 8: 409–14.

Zukerman E, Hannuch SN, Carvalho D de S, Fragoso YD, Jenger KA. 'Hemicrania continua': a case report. *Cephalalgia* 1987; 7: 171–3.

*Received May 17, 1996. Revised September 13, 1996.*

*Accepted September 24, 1996*