

Surgical outcome and prognostic factors of frontal lobe epilepsy surgery

Lara E. Jeha,¹ Imad Najm,¹ William Bingaman,² Dudley Dinner,¹ Peter Widdess-Walsh² and Hans Lüders¹

¹Department of Neurology, Section of Epilepsy and ²Department of Neurosurgery, Cleveland Clinic, Cleveland, OH, USA

Correspondence to: Lara Jeha, MD, Epilepsy Center, Department of Neurology, Cleveland Clinic, 9500 Euclid Ave, Cleveland, OH 44195, USA
E-mail: jehil@ccf.org

Frontal lobe epilepsy (FLE) surgery is the second most common surgery performed to treat pharmacoresistant epilepsy. Yet, little is known about long-term seizure outcome following frontal lobectomy. The aim of this study is to investigate the trends in longitudinal outcome and identify potential prognostic indicators in a cohort of FLE patients investigated using modern diagnostic techniques. We reviewed 70 patients who underwent a frontal lobectomy between 1995 and 2003 (mean follow-up 4.1 ± 3 years). Data were analysed using survival analysis and multivariate regression with Cox proportional hazard models. A favourable outcome was defined as complete seizure-freedom, allowing for auras and seizures restricted to the first post-operative week. The estimated probability of complete seizure-freedom was 55.7% [95% confidence interval (CI) = 50–62] at 1 post-operative year, 45.1% (95% CI = 39–51) at 3 years, and 30.1% (95% CI = 21–39) at 5 years. Eighty per cent of seizure recurrences occurred within the first 6 post-operative months. Late remissions and relapses occurred, but were rare. After multivariate analysis, the following variables retained their significance as independent predictors of seizure recurrence: MRI-negative malformation of cortical development as disease aetiology [risk ratio (RR) = 2.22, 95% CI = 1.40–3.47], any extrafrontal MRI abnormality (RR = 1.75, 95% CI = 1.12–2.69), generalized/non-localized ictal EEG patterns (RR = 1.83, 95% CI = 1.15–2.87), occurrence of acute post-operative seizures (RR = 2.17, 95% CI = 1.50–3.14) and incomplete surgical resection (RR = 2.56, 95% CI = 1.66–4.05) (log likelihood-ratio test P -value < 0.0001). More than half of patients in favourable prognostic categories were seizure-free at 3 years, and up to 40% were seizure-free at 5 years, compared to <15% in those with unfavourable outcome predictors. These data underscore the importance of appropriate selection of potential surgical candidates.

Keywords: surgery; epileptology; frontal lobe; outcome

Abbreviations: APOS = acute post-operative seizures; CI = confidence interval; FLE = frontal lobe epilepsy; MCD = malformation of cortical development; RR = risk ratio

Received October 11, 2006. Revised November 30, 2006. Accepted December 4, 2006. Advance Access publication January 5, 2006.

Introduction

Frontal lobe epilepsy (FLE) surgery accounts for 6–30% of all epilepsy surgeries. It represents the second most common procedure performed to treat pharmacoresistant epilepsy after temporal lobectomy (Janszky *et al.*, 2000; Hosking, 2003). Reported success rates range from 13 to 80% (Rasmussen, 1991; Talairach *et al.*, 1992; Fish *et al.*, 1993; Wieser and Hajek, 1995; Zentner *et al.*, 1996; Swartz *et al.*, 1998; Ferrier *et al.*, 1999, 2001; Jobst *et al.*, 2000; Mosewich *et al.*, 2000; Zaatreh *et al.*, 2002; Chung *et al.*, 2005; Lee *et al.*, 2005; Yun *et al.*, 2006), suggesting much less rewarding outcomes than following temporal lobectomy

(Talairach *et al.*, 1992; Fish *et al.*, 1993; Wieser and Hajek, 1995; Jeha *et al.*, 2006). However, surgical failures remain poorly characterized.

Most prior reports included patients with other types of neocortical epilepsy in addition to FLE limiting the applicability of their results in patients with pure FLE (Zentner *et al.*, 1996; Lee *et al.*, 2005; Yun *et al.*, 2006). Some restricted their analysis to lesional FLE (Janszky *et al.*, 2000; Schramm *et al.*, 2002; Zaatreh *et al.*, 2002) introducing a selection bias, especially since current literature suggests that lesional epilepsy patients have better outcomes (Ferrier *et al.*, 1999;

Mosewich *et al.*, 2000; Yun *et al.*, 2006). Several older studies were done in the pre-MRI era (Rasmussen, 1991; Talairach *et al.*, 1992; Fish *et al.*, 1993; Wieser and Hajek, 1995), a significant limitation as neuroimaging seems to be a very important determinant of post-operative seizure-freedom (Smith *et al.*, 1997; Ferrier *et al.*, 1999; Mosewich *et al.*, 2000; Kral *et al.*, 2001; Yun *et al.*, 2006). Few studies attempted to evaluate predictors of recurrence using multiple logistic regression methods to account for interaction among outcome indicators (Janszky *et al.*, 2000; Mosewich *et al.*, 2000; Yun *et al.*, 2006), but all were cross-sectional in design. Thus, none evaluated longitudinal aspects of recurrence such as the change in rate of post-operative seizure-freedom with time, nor investigated potential prognostic predictors using modern statistical techniques designed for time-dependent variables and outcomes. With current knowledge, it is therefore difficult to predict long-term seizure-freedom following frontal lobectomy, and to correctly identify independent predictors of outcome.

The goal of our study is to examine seizure-freedom following frontal lobectomy in a cohort of FLE patients evaluated using modern diagnostic techniques. In particular, we aim at assessing the chances and predictors of long-term post-operative seizure-freedom. We used the statistical methods of survival analysis and proportional hazard modelling to evaluate rate, stability and predictors of seizure-freedom while accounting for variation in the duration of follow-up among patients.

Material and methods

Patient selection

We reviewed medical records of all patients with medically refractory FLE who underwent frontal lobectomy at Cleveland Clinic between January 1995 and December 2003, excluding those with prior brain surgery, or with resections extending beyond the frontal lobe. Follow-up of at least 1 year was required. Data collected included dates of surgery, of seizure recurrence and of last follow-up, age at seizure onset and at surgery, gender, side of surgery, presence of auras and of generalized tonic-clonic seizures, family history of epilepsy, seizure semiology and frequency, and results of pre-operative and post-operative EEG and MRI. The occurrence of acute post-operative seizures (APOS) as defined by seizures occurring within the first post-operative week was also recorded.

Pre-operative patient evaluation protocol

All patients had prolonged video-EEG monitoring with electrodes placed according to the International 10–20 system. Interictal discharges were classified as either strictly frontal or not. The presence of additional contralateral, generalized or focal extra-frontal spikes was noted. EEG ictal patterns were categorized as regional if the EEG seizure amplitude in one chain was at least twice as high as the adjacent bipolar electrode chain. A lateralized pattern was defined if both ipsilateral electrode chains were involved and the contralateral hemisphere pattern was <50% amplitude. If a clear side of onset was not present, or if the initial

EEG change was diffuse, the seizure was defined as non-localizable or generalized. Clinical seizure semiology was recorded (Luders *et al.*, 1998), as was the occurrence of multiple seizure types. All patients had high-resolution MRI performed with a Siemens 1.5 tesla SP system (Siemens, Erlangen, Germany) using a standardized epilepsy protocol that included high resolution T₁-weighted volume acquisition, T₂-weighted and fluid attenuated inversion recovery sequences. Patients were classified as either having a normal MRI, pure frontal lobe abnormalities or lesions extending beyond the operated frontal lobe. The presence of associated hippocampal atrophy and/or hippocampal signal changes suggestive of hippocampal sclerosis was noted separately.

Additional functional neuroimaging studies (PET and SPECT) were obtained when indicated. All patients had detailed neuropsychological and psychosocial evaluations. Results of the non-invasive evaluation were discussed in a multidisciplinary patient management conference where the decision was made to either proceed with surgery, or to perform an invasive evaluation for further investigation. Subdural electrodes (SDE) were implanted for any of the following reasons: (i) to confirm the ictal onset zone if scalp EEG information was either non-localizing or inconsistent with other non-invasive investigations such as MRI or seizure semiology; (ii) to perform functional mapping pre-operatively if the ictal onset zone was thought to be close to eloquent cortex; (iii) whenever a multifocal epileptogenic process was suspected based on multifocal non-invasive EEG findings or multilobar involvement on imaging. Intraoperative electrocorticography (EcoG) was performed in some cases to either confirm removal of epileptogenic cortex, or to avoid eloquent cortex resection. The occurrence of multifocal seizures on invasive evaluation was recorded.

Surgery and pathological subgroups

All patients underwent lesionectomy, subtotal lobectomy or frontal lobectomy. We did not include cases of hemispherectomy or patients with previous epilepsy surgery. The posterior resection margin was determined by the precentral sulcus as defined anatomically and by invasive recordings to avoid loss of eloquent cortex.

Tissue sections from cortical resections were fixed in 10% buffered formalin, embedded in paraffin and then stained. Pathological diagnoses were classified into malformation of cortical development (MCD, cortical dysplasia), neoplasm, gliosis, vascular malformation or normal histology.

Based on MRI and surgical pathology, patients were divided into the following aetiological subgroups: (i) MCD with abnormal MRI (41% of cases), (ii) MCD with normal high-resolution MRI (17%), (iii) tumour (19%), (iv) vascular malformation (3%), (v) cryptogenic with normal MRI and histology (10%), (vi) encephalomalacia following stroke or trauma (10%).

Post-operative patient evaluation protocol

Post-operatively, patients were admitted to the general neurology floor, neurology intensive care unit or epilepsy monitoring unit. All patients underwent a post-operative high-resolution MRI, and a routine outpatient EEG at 6 post-operative months. A judgement was made as to whether surgical resection was complete. In non-lesional cases ($n = 18$), resection was considered complete if there was complete removal of the brain tissue covered by the electrodes of ictal onset and most frequent interictal abnormalities defined by invasive electrophysiological evaluations. In lesional cases ($n = 51$), complete removal of the MRI lesion was required. In patients with

Table 1 Clinical characteristics of the overall cohort, with comparison between the seizure-free and non-seizure-free groups (*P*-value is for Wilcoxon rank sum, χ^2 or Fisher's exact tests as appropriate)

	Overall group (<i>n</i> = 70)	Seizure-free (<i>n</i> = 31)	Recurred (<i>n</i> = 39)	<i>P</i> -value
Female	30 (43)	10 (33)	20 (51)	0.11
Left frontal surgery	34 (49)	12 (39)	22 (56)	0.14
Mean age at onset, years (range)	11.8 (0.1–52)	13.6 (0.1–52)	10.3 (0.1–52)	0.32
Mean age at surgery, years (range)	22.0 (1–57)	22.0 (1–52)	22.0 (1–57)	0.99
Mean pre-operative seizure frequency/month (range)	95 (1–900)	105 (1–900)	88 (2–450)	0.64
Pre-operative auras present	42 (61)	17 (57)	25 (64)	0.53
Pre-operative GTC present	44 (63)	20 (65)	24 (62)	0.80
Positive family history	12 (17)	7 (23)	5 (17)	0.25
Multiple clinical seizure types present	23 (33)	10 (32)	13 (34)	0.86
Predominant seizure type				
Simple motor	27 (39)	13	14	0.96
Asymmetric tonic	21 (30)	8	13	
Hypermotor	10 (15)	4	6	
Dialeptic/automotor	11 (15)	5	6	

Data are no. of patients or no. (%).

a lesional MRI, who also had SDE or EcoG (*n* = 29), complete resection of electrophysiological abnormalities was required in addition to removal of the MRI abnormality.

Outcome definition

Patients were classified as either seizure-free or not seizure-free. The 'seizure-free' definition encompassed auras and seizures restricted to the first post-operative week. Follow-up information was obtained from clinic visits and patient phone calls. The typical follow-up schedule consisted of a clinic visit at 3 post-operative months, 6 months, 1 year and then yearly or as indicated. The primary outcome was time to first seizure recurrence. In patients who had APOS within the first post-operative week, the time to the first recurrence following the APOS was considered. When medical records indicated that a recurrence occurred between two follow-up visits or phone contacts, the date of recurrence was taken as the mid-point of this period. With all patients having the follow-up schedule detailed above, the period between documented contacts (visits or phone calls) never exceeded 1 year.

Statistical methods

Prior to modelling, the data were summarized with descriptive statistics for each variable including means, medians, and standard deviations for continuous variables and frequencies for categorical variables. For exploratory purposes, an initial analysis of the data was first performed univariably using Wilcoxon rank sum, χ^2 and Fisher's exact tests to compare seizure-free patients to those with seizure recurrence, regardless of follow-up time. This allowed identification of potential prognostic indicators. Variables with a significance level of 10% on initial univariate analysis were then tested in a multivariate Cox proportional hazards regression model. Results were then considered statistically significant at the 5% level. This method allows testing the correlation of specific variables with outcome while taking into account any interactions and associations among those variables, and their variation with time.

Kaplan–Meier survival analysis was first used to calculate the probability of seizure-freedom in the overall group prior to any outcome predictor analysis, and later by considering each of the significant risk factors. Statistical significance was tested using the log-rank test and comparison of 95% confidence intervals (CIs).

Table 2 Radiological characteristics of the overall cohort, with comparison between the seizure-free and non-seizure-free groups (*N* and *n* = number of patients in each group; *P*-value is for χ^2 test)

	<i>N</i>	Recurred <i>n</i> (%)
PET characteristics (<i>P</i> -value = 0.48)	37	20 (54)
Normal	9	6 (67)
Abnormal ipsilaterally	20	11 (55)
Abnormal bilaterally	8	3 (37)
MRI characteristics (<i>P</i> -value = 0.01)	69	38 (55)
Normal	18	15 (83)
Abnormal	51	23 (45)
Frontal	29	6 (21)
Multilobar	22	17 (77)

Results

Patient characteristics

Seventy patients fulfilled all inclusion and exclusion criteria and were analysed. The mean follow-up duration was 4.1 years \pm (SD) 3.0 years (median 3.1; range 1–11 years). Seizures recurred in 39 patients (56%) by the time of last follow-up. Only 4/39 recurrences (10%) occurred in the context of AED withdrawal.

Table 1 summarizes the patients' baseline clinical characteristics, while Table 2 describes their imaging characteristics.

Forty-three per cent were females, about half had left sided surgery and a third had multiple clinical seizure types. Most had abnormal neuroimaging; only 18 (26%) had a normal MRI and 24% had a normal PET (9 out of 37 where PET was performed). Among 22 patients with multilobar MRI findings, 8 had 'dual pathology' with hippocampal atrophy and/or hippocampal signal changes: five of those had evidence of frontal cortical migrational abnormalities on MRI, two had a frontal lobe tumour and one had fronto-temporal encephalomalacia.

On non-invasive recordings, EEG abnormalities were mostly frontal, although diffuse changes were frequent (Table 3). Interictal spiking was strictly frontal in 46 (68%),

with generalized spikes in another 17 (25%). Regional frontal EEG seizures were recorded in 36 cases. Multiple EEG seizure types were captured in 17 (25%). Ipsilateral spiking was seen in 32 out of 61 patients who had a 6 month post-operative EEG.

SDEs were often used (47 patients or 67%). All patients with traumatic encephalomalacia and those eventually diagnosed with MRI-negative MCD had SDE evaluation, followed by 62% of lesional MCD cases and 23–50% of cases with other aetiologies. Intraoperative EcoG was performed in 78% of patients who did not have SDE, and in 60% of those who did. With invasive EEG recordings, multifocal seizures were recorded in 14/47 cases (30%) (Table 3).

Surgical resection was felt to be complete in 42 (60%) of the cases. Most incomplete resections were to avoid removal of eloquent cortex. Twenty patients (29%) had APOS. Post-operative auras occurred in 26; auras remained isolated in 4 and were associated with seizures in 22.

Table 3 EEG characteristics of the overall cohort, with comparison between the seizure-free and non-seizure-free groups (*N* and *n* = number of patients in each group; *P*-value is for χ^2 test)

EEG characteristics	<i>N</i>	Recurred <i>n</i> (%)	<i>P</i> -value
Pre-operative characteristics			
Non-invasive EEG	70		
Interictal spikes			
Ipsilateral frontal spikes only			
Yes	46	26 (57)	0.84
No	22	13 (59)	
Extracortical spikes			
Present	26	18 (69)	0.12
Absent	42	21 (50)	
Generalized spikes			
Present	17	13 (76)	0.06
Absent	51	26 (51)	
Contralateral spikes			
Present	12	9 (75)	0.15
Absent	55	29 (53)	
Ictal rhythm			
Frontal	36	21 (58)	0.07
Lateralized	10	4 (40)	
Generalized	15	12 (80)	
Multiple EEG seizure types			
Present	17	12 (71)	0.16
Absent	51	26 (51)	
Invasive EEG			
Ictal onset zones			
Lateral frontal	19	11 (58)	0.58
Mesial frontal	6	5 (83)	
Orbitofrontal	5	2 (40)	
Multifocal	17	12 (71)	
Post-operative characteristics			
Ipsilateral spikes			
Present	32	27 (84)	<0.0001
Absent	29	7 (24)	
Contralateral spikes			
Present	5	4 (80)	0.24
Absent	56	30 (54)	

Overall recurrence

The Kaplan–Meier survival curve illustrating seizure recurrence in the overall group is shown in Fig. 1. Although 39 patients (56%) had seizure recurrence by the time of last follow-up, it is clear from Fig. 1 that the chance of being seizure-free varied widely with post-operative time. The chance of seizure-freedom fell abruptly to 56% within the first 6 months, then at a somewhat slower rate (5–8% per year) until 4–5 years, beyond which it stabilized at around 30%. In fact, the median timing of seizure recurrence was 2 months with 80% of recurrences occurring before 6 months. The estimated chance of seizure-freedom was 55.7% (95% CI = 50–62) at 1 post-operative year, 50.5% (95% CI = 44–56) at 2 years, 45.1% (95% CI = 39–51) at 3 years, 37.6% (95% CI = 31–44) at 4 years and 30.1% (95% CI = 21–39) at 5 years and beyond.

Table 4 shows the outcomes using Engel's criteria at 1, 2 and 5 years post-operatively. In addition to 38 patients who were completely seizure-free at 1 year, 17 had a significant improvement in seizure control (Engel 2 in 9, and Engel 3 in 8 patients): mean monthly seizure frequencies dropped from 124.4 ± 21.4 seizures down to 19.8 ± 38.7 in this subgroup. However, this improvement was sustained until the last follow-up in only 6/17 (35%), with seizure frequencies returning to pre-operative levels in the remainder. Even among the seven patients who only had rare breakthrough seizures (<1 per month) within the first year, seizures worsened in six (median 18 seizures/month; range 1–150 at last follow-up) despite re-operation in three and anticonvulsant adjustment in all.

Late relapses after early seizure-freedom were observed, but were rare. Only eight patients relapsed after being seizure-free for the first 6 months. Those patients tended to have less frequent seizures at last follow-up compared to those with recurrences within the first 6 months (median 12 seizures/month; range 0–120 at last follow-up if first recurrence after 6 months compared to 30 seizures/month; range 0–300 if first recurrence was earlier; $P = 0.10$). In fact,

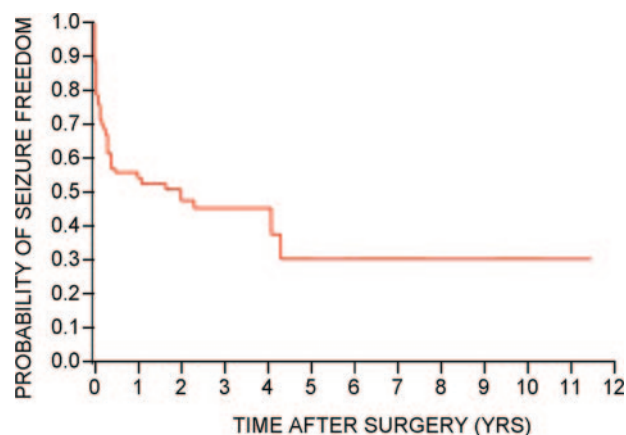


Fig. 1 Kaplan–Meier plot illustrating chances of postoperative seizure freedom following frontal lobectomy in overall cohort.

Table 4 Engel classification of our surgical cohort at 1 year, 2 years and 5 years after frontal lobectomy

	1 year	2 years	5 years
Patients available for follow-up	70	65	22
Engel 1 (%)	38 (55)	36 (55)	6 (27)
Engel 2 (%)	9 (12)	6 (9)	1 (5)
Engel 3 (%)	8 (11)	9 (14)	7 (32)
Engel 4 (%)	15 (21)	14 (22)	8 (36)

half of those eight patients achieved Engel 1 class again by last follow-up: two had an isolated breakthrough seizure when off AEDs and were controlled again with re-initiation of AEDs, and two were controlled after re-operation.

For the 39 patients with any seizure recurrence, the Engel classification at last follow-up was 1 in 7 (18%), 2 in 6 (15%), 3 in 11 (28%) and 4 in 15 (38%). Therefore, even following seizure recurrence, 62% of patients were significantly improved at last follow-up compared to baseline: half of those, however, were only controlled following re-operation.

Univariate analysis

On initial univariate screening, the following variables correlated with seizure recurrence: MRI-negative MCD as disease aetiology, hippocampal atrophy (dual pathology) or any extrafrontal abnormality on MRI, generalized/non-localized ictal patterns and interictal discharges on scalp EEG, need for SDE implantation, occurrence of APOS, post-operative auras and incomplete surgical resection (Table 5). The independence and significance of those variables was assessed in the multivariate proportional hazard model.

Ipsilateral interictal spiking on the 6 months post-operative routine EEG was more frequent in patients with a bad outcome (Table 3). Even though 80% of recurrences had already occurred by 6 post-operative months, univariate survival analysis showed that ipsilateral spikes correlated with future recurrence in the subgroup of patients who were still seizure-free up to that point (Table 6). However, the numbers were too small to include this variable in a multivariate analysis.

Multivariate analysis

Upon applying proportional hazard modelling, the following variables retained their significance as independent predictors of outcome: MRI-negative MCD as disease aetiology, any extrafrontal MRI abnormality, generalized/non-localized ictal EEG patterns, occurrence of APOS, and incomplete surgical resection (log likelihood-ratio test P -value <0.0001). Results are shown in Table 7. The use of SDE, generalized interictal discharges and presence of post-operative auras lost their significance. Upon further analysis, we found that the use of SDE correlated both with a normal MRI ($P = 0.0126$, Pearson χ^2 test), and with a pathological diagnosis of MCD ($P = 0.0004$). Generalized interictal

Table 5 Variables correlating with complete post-operative seizure-freedom on univariate analysis

	N	Recurred N (%)	P -value
Aetiology			0.03
MCD (abnormal MRI)	29	14 (48)	
MCD (normal MRI)	12	11 (92)	
Tumour	13	5 (38)	
Vascular malformation	1	0 (0)	
Cryptogenic (normal MRI and pathology)	7	5 (71)	
Encephalomalacia	7	4 (57)	
MRI			
Extrafrontal abnormality			
Present	22	17 (77)	0.01
Absent	47	22 (47)	
Hippocampal atrophy			
Present	8	7 (87)	0.04
Absent	61	32 (52)	
EEG			
Generalized interictal spikes			
Present	17	13 (76)	0.06
Absent	51	26 (51)	
Ictal pattern			
Regional/lateralized	46	25 (54)	0.07
Generalized	15	12 (80)	
Subdural electrodes			
Used	47	30 (64)	0.05
Not used	23	9 (39)	
Immediate post-operative seizures			0.006
Present	20	16 (80)	
Absent	49	22 (45)	
Post-operative auras			<0.0001
Present	26	22 (85)	
Absent	42	16 (38)	
Extent of resection			<0.0001
Complete	42	15 (36)	
Incomplete	26	23 (88)	

discharges were more frequent in patients where a complete resection could not be achieved ($P = 0.0139$). Post-operative auras correlated strongly with MRI-negative MCD as disease aetiology ($P = 0.0255$), and weakly with incomplete resection ($P = 0.0648$). No correlation was identified between post-operative auras and the presence of extrafrontal MRI abnormalities on pre-operative testing.

Seizure-free rates for the identified outcome predictors were calculated at 1, 2 and 3 post-operative years (Table 8), and survival analysis curves were constructed (Fig. 2). All patients with MRI-negative MCD as disease aetiology or with APOS had seizure recurrence before 3 post-operative years. In those with extrafrontal MRI abnormalities, generalized/non-localized ictal EEG patterns or incomplete resection, chances of seizure-freedom stabilized within the 11–14% range beyond 3 post-operative years.

When disease aetiology or completeness of surgical resection are considered, the magnitude of the difference in outcome between the favourable and unfavourable groups is appreciable as early as the first post-operative year landmark. At 1 year, only 12% of patients with MRI-negative MCD and 13% of those with incomplete resection were

Table 6 Seizure recurrence as related to post-operative EEG in patients without recurrence by 6 months ($P = 0.01$, log-rank test between groups on univariate survival analysis)

Seizure-free rates	1 year (%)	2 years (%)	3 years (%)
Patients with no seizures at 6 months ($n = 39$)			
Ipsilateral spikes at 6 months EEG			
Yes	89 ± 9	56 ± 17	6 ± 4
No	96 ± 4	70 ± 9	34 ± 4

Table 7 Variables correlating with complete post-operative seizure-freedom after applying multivariate proportional hazard modelling

Variable	Risk ratio	95% CI	P-value
MCD (normal MRI)	2.22	1.40–3.47	0.0009
Extracranial MRI abnormality	1.75	1.12–2.69	0.02
MTS on MRI	1.12	0.64–2.00	NS
Use of SDE	1.33	0.81–2.18	NS
Generalized interictal EEG	0.73	0.50–1.10	NS
Generalized ictal EEG	1.83	1.15–2.87	0.01
Immediate post-operative seizures	2.17	1.50–3.14	0.0001
Post-operative auras	1.49	0.97–2.37	NS
Incomplete resection	2.56	1.66–4.05	<0.0001

NS = non-significant.

Table 8 Estimated chances of complete seizure-freedom at 1–3 post-operative years as obtained from survival analysis by each of the identified prognostic indicators

Seizure-free rates	1 year (%)	2 years (%)	3 years (%)
MCD (normal MRI) ($P = 0.0009$)			
Yes	12 ± 8	8 ± 7	N/A
No	64 ± 6	58 ± 7	53 ± 7
Extracranial MRI abnormalities ($P = 0.02$)			
Absent	60 ± 7	57 ± 7	57 ± 7
Present	45 ± 11	28 ± 10	14 ± 9
Immediate post-operative seizures ($P < 0.0001$)			
Absent	67 ± 7	63 ± 7	57 ± 7
Present	38 ± 11	20 ± 9	N/A
Ictal EEG ($P = 0.01$)			
Regional/lateralized	57 ± 7	50 ± 7	50 ± 7
Generalized	33 ± 12	22 ± 12	11 ± 9
Extent of resection ($P < 0.0001$)			
Complete	81 ± 6	70 ± 7	66 ± 7
Incomplete	13 ± 7	12 ± 6	11 ± 6

seizure free, as opposed to 64 and 81%, respectively, in the corresponding better prognosis groups. Eventually, the chances of seizure-freedom were much higher in the favourable prognosis groups (50–66% at ≥ 3 years) compared to the bad prognosis groups (0–14% at ≥ 3 years) for all variables. Thirteen patients fulfilled all the favourable prognostic requirements (i.e. had strictly frontal MRI lesions judged to be completely resected, with focal pre-operative ictal EEGs and no APOS). Of those, only two (15%) had seizure recurrences during the whole duration of

follow-up. The extent of surgical resection was the strongest predictor of outcome [risk ratio (RR) = 2.56, 95% CI = 1.66–4.05].

Discussion

Overall seizure recurrence

We report the first longitudinal outcome study on 70 FLE patients evaluated using modern diagnostic techniques.

Previously reported rates of seizure-freedom following FLE surgery varied greatly from as low as 13% to as high as 80% (Rasmussen, 1991; Talairach *et al.*, 1992; Fish *et al.*, 1993; Wieser and Hajek, 1995; Zentner *et al.*, 1996; Swartz *et al.*, 1998; Ferrier *et al.*, 1999, 2001; Jobst *et al.*, 2000; Mosewich *et al.*, 2000; Zaatreh *et al.*, 2002; Chung *et al.*, 2005; Lee *et al.*, 2005; Yun *et al.*, 2006). Heterogeneity of patient populations, evolution of surgical techniques and inconsistency of 'favourable outcome' definition among studies may account for such a wide difference. Our data suggest that use of cross-sectional methods of analysis at different points of follow-up might also have contributed to this discrepancy among previous studies. Although 54% of our patients were seizure-free at last follow-up, similar to many recently published reports (Swartz *et al.*, 1998; Wennberg *et al.*, 1999; Janszky *et al.*, 2000; Ferrier *et al.*, 2001; Schramm *et al.*, 2002), our longitudinal analysis shows that the actual chance of seizure-freedom varies greatly with post-operative time. While 56% of patients were seizure-free at 1 year, only 45% were seizure-free at 3 years, and a mere 30% still enjoyed this seizure-freedom at 5 years. A drop in seizure-freedom with post-operative time has been repeatedly documented following temporal lobectomy (Yoon *et al.*, 2003; McIntosh *et al.*, 2004; Jeha *et al.*, 2006). Our study shows that it occurs at a higher pace and to a greater extent following FLE surgery: 80% of seizure recurrences occurred within 6 months in our study, while only about half the recurrences following temporal lobe surgery occur within the same timeframe (Luders *et al.*, 1994; Sperling *et al.*, 1996; Foldvary *et al.*, 2000). Recurrences were also more difficult to control in our FLE patients. While resumption of AEDs controls up to 60% of post-operative recurrences after temporal lobectomy (Schmidt *et al.*, 2004; Jeha *et al.*, 2006; Schwartz *et al.*, 2006), seizures persisted in at least 60% of our recurrences at last follow-up.

Although only one third of our overall cohort enjoyed long-term seizure-freedom (Fig. 1), this is probably due to the wide difference in outcome among patients with favourable prognostic indicators compared to those without them, rather than due to inadequacy of surgery as such to treat refractory FLE. For all the prognostic indicators we identified, more than half of patients in the favourable categories were seizure-free at 3 years, and up to 40% were seizure-free at ≥ 5 years (Fig. 2). Those are acceptable outcomes, albeit still less favourable than the 40–55% seizure-freedom rates proposed at 10 years following temporal lobectomy (Foldvary *et al.*, 2000; Wieser *et al.*, 2001;

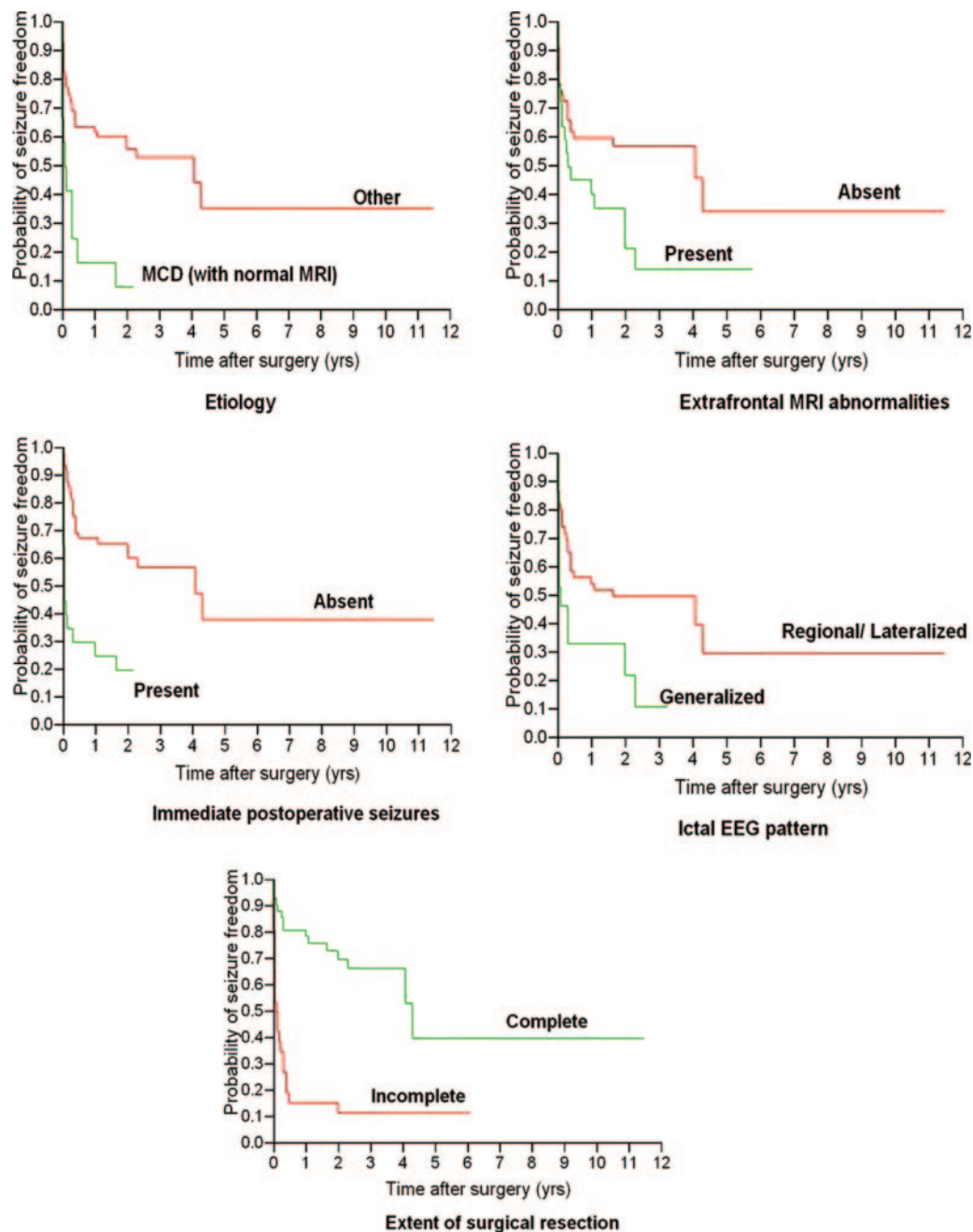


Fig. 2 Survival analysis illustrating chances of postoperative seizure freedom following frontal lobectomy depending on the identified prognostic indicators.

Jutila *et al.*, 2002; McIntosh *et al.*, 2004; Kelley and Theodore, 2005; Jeha *et al.*, 2006). When patients fulfilled all our favourable indicators, the chance of seizure-freedom was 85% at last follow-up, similar to success rates following temporal lobectomy. This suggests that even in FLE, very successful outcomes can be achieved in a highly selected group of patients.

Predictors of outcome

We identified five predictors of outcome. For all, the chance of seizure-freedom was >50% at 3 years in the favourable

categories, while <15% of patients were estimated to be seizure-free otherwise. All prognostic factors converge into one central theme: an epileptogenic zone that is well visualized and restricted in its extent (both electrically and semiologically) offers the best chances of cure when completely resected. Factors that either reflect poor visualization of the epileptogenic zone (MRI-negative MCD), or its diffuse extent (extending beyond the frontal lobe on MRI, and showing generalized/non-localized ictal pattern) make a 'complete' removal of epileptogenic brain tissue harder, and characterize the patient population at highest risk of

recurrence. The occurrence of APOS, a poor prognostic marker for our patients, may then represent an immediate post-operative correlate of residual epileptogenicity following an incomplete resection.

Pre-operative clinical predictors

Similar to previous reports, we found no correlation of post-operative seizure outcome with gender (Yun *et al.*, 2006), side of surgery (Olivier, 1995; Schramm *et al.*, 2002; Yun *et al.*, 2006), age at onset of epilepsy (Ferrier *et al.*, 1999; Janszky *et al.*, 2000; Schramm *et al.*, 2002; Lee *et al.*, 2005; Yun *et al.*, 2006), age at surgery (Schramm *et al.*, 2002; Lee *et al.*, 2005; Yun *et al.*, 2006), epilepsy duration (Ferrier *et al.*, 1999; Janszky *et al.*, 2000; Lee *et al.*, 2005; Yun *et al.*, 2006), pre-operative seizure frequency, history of generalized tonic-clonic seizures (Ferrier *et al.*, 1999; Chung *et al.*, 2005; Yun *et al.*, 2006), multiple clinical seizure types or auras (Yun *et al.*, 2006), nor family history of epilepsy.

Imaging predictors

Our finding that a MRI-visible frontal lobe lesion correlates with post-operative seizure-freedom is consistent with current literature (Cascino *et al.*, 1992; Smith *et al.*, 1997; Ferrier *et al.*, 1999; Mosewich *et al.*, 2000; Kral *et al.*, 2001; Yun *et al.*, 2006). Twenty-five per cent of the patients with negative MRI studies and 67% of those with neuroimaging abnormalities restricted to the frontal lobe were seizure-free at a minimum duration of 1 year follow-up in one study (Cascino *et al.*, 1992). A focal MRI abnormality was the only variable significantly associated with a favourable surgical outcome in another report (Ferrier *et al.*, 1999). Only 41% of non-lesional FLE patients had an excellent outcome, versus 72% when MRI abnormality was present in yet another analysis (Mosewich *et al.*, 2000).

A normal MRI in a patient with ‘apparent’ FLE could mean that either the true epileptogenic zone is extrafrontal and not visible on MRI, or that the focus is indeed frontal, but invisible on imaging. In either case, post-operative seizure-freedom would not be very likely. In our cohort, a poor prognosis was seen in patients with normal MRI and pathologically proven MCD (RR = 2.22, 95% CI = 1.40–3.47). All such patients had recurrent seizures by 3 post-operative years. This is consistent with many recent reports. Among all MCD patients, a mild degree of dysplasia and a frontal lobe location were the only variables predictive of a poor outcome in a study where 68.8% of frontal lobe MCD cases actually had normal imaging (Chung *et al.*, 2005). Concurrently, among all neocortical epilepsies, a frontal lobe location and MCD predicted the worst outcomes in another report (Yun *et al.*, 2006). Knowing that milder forms of MCD subtypes such as microdysgenesis, cortical dyslamination or focal MCD are often missed, even on high-resolution MRI (Lee *et al.*, 2001; Montenegro *et al.*, 2002; Tassi *et al.*, 2002; Widdess-Walsh *et al.*, 2005) may explain why one cannot ‘see’ the extent of the epileptogenic tissue in those MRI-negative MCD cases making adequate surgical treatment

harder. Tumours, well-circumscribed pathologies, had the best outcome in our cohort (62% seizure-free at last follow-up, Table 5).

Any extrafrontal MRI abnormality conferred poor prognosis, similar to previous reports (Cascino *et al.*, 1992; Salanova *et al.*, 1994; Lorenzo *et al.*, 1995; Swartz *et al.*, 1998; Wyllie *et al.*, 1998; Ferrier *et al.*, 1999; Schramm *et al.*, 2002) where favourable outcomes occurred in either none of the patients with multilobar MRI abnormalities (Cascino *et al.*, 1992; Lorenzo *et al.*, 1995), or at best in 10–14% (Swartz *et al.*, 1998; Schramm *et al.*, 2002). Some investigators have specifically suggested that the structural basis of all or some of the intractable seizures following failed FLE surgery may be undetected mesial temporal sclerosis (MTS) because a history of childhood febrile seizures was a poor prognostic factor for their patients (Mosewich *et al.*, 2000). In our group, eight patients (12%) had ‘dual pathology’ on MRI. This is within the 0–29% previously reported incidence of dual pathology with extratemporal refractory epilepsy (Cascino *et al.*, 1993; Adam *et al.*, 1994). It is however less than the 40% rate reported in MCD series, where its occurrence was virtually restricted to TLE patients (Li *et al.*, 1999; Fauser *et al.*, 2006). Outcomes of ‘dual pathology’ patients in our series (13% seizure-free at last follow-up, Table 5) are concordant with a recent series of 38 ‘dual pathology’ patients (including 8 with frontal lesions), where only 12.5% of those with lesionectomy alone were seizure-free compared to 73% with lesionectomy and mesial temporal resection (Li *et al.*, 1999). ‘Dual pathology’ cases in our series did not, however, fare significantly worse than those with other extrafrontal abnormalities (23% seizure-free at last follow-up, Table 5), and the presence of MTS was only significant on the univariate level of analysis suggesting that it may be just as significant as other extrafrontal MRI abnormalities in predicting outcome.

Correct localization by PET predicted surgical success in prior series of neocortical epilepsy (Lee *et al.*, 2005; Yun *et al.*, 2006). Also, FDG PET was sensitive in localizing epileptogenic zones in both lesional and non-lesional patients with FLE (Kim *et al.*, 2002). A predictive value to FDG-PET is therefore very possible in FLE surgery. Our results do not confirm such a correlation (Table 2). This is either sample-size related or because an independent predictive value of PET does not exist in the specific subgroup of neocortical epilepsy patients with FLE.

Electrophysiological predictors

EEG evidence of diffuse epileptogenicity minimized surgical success rates. Both generalized interictal and ictal EEG correlated with worse outcome on univariate analysis. However, only generalized ictal EEG remained significant after multivariate modelling (RR = 1.83, 95% CI = 1.15–2.87). This is consistent with a recent report showing that generalized EEG features (slowing and spikes) were the only predictors of seizure recurrence following surgery for

lesional FLE (Janszky *et al.*, 2000), and with another study where a localized ictal onset on EEG was an independent predictor of seizure-freedom in a cohort of neocortical epilepsy (Yun *et al.*, 2006). While previous reports suggested that SDE use either had negative (Armon *et al.*, 1996; Janszky *et al.*, 2000) or no prognostic significance in FLE (Kral *et al.*, 2001; Mariottini *et al.*, 2001; Yun *et al.*, 2006), our data suggest that it is simply a reflection of a poorly localized epileptogenic zone, rather than an independent predictor of outcome. In our cohort, SDEs were used mostly in patients with a normal MRI who had cortical dysplasia on pathology, the group with the worst surgical prognosis.

Patients with multiple EEG seizure types on either invasive or non-invasive recordings tended to have a worse outcome, but this correlation did not achieve statistical significance (Tables 1 and 3).

Surgical predictors

The most important factor in determining a favourable outcome in our group was completeness of resection (RR = 2.56, 95% CI = 1.66–4.05). Of patients who had complete removal of their epileptogenic lesions, 81% were seizure-free at 1 year and 66% at 3 years, compared to 13 and 11%, respectively, of those who underwent partial resection. Complete removal of neuroimaging abnormalities (Awad *et al.*, 1991; Wennberg *et al.*, 1999; Janszky *et al.*, 2000; Tassi *et al.*, 2002; Urbach *et al.*, 2002; Chung *et al.*, 2005), and abolition of residual EcoG spiking (Salanova *et al.*, 1994; Tran *et al.*, 1997) or seizures (Ferrier *et al.*, 2001) have already been linked with the most favourable outcomes following FLE surgery. Those findings are not surprising: it is only logical to expect that ‘complete’ removal of the epileptogenic tissue should lead to seizure-freedom. The first caveat in this regard is assessing the ‘completeness’ of the resection: we now know that histological abnormalities in MCD, the main pathological substrate of FLE, frequently extend beyond the visible MRI changes (Palmini *et al.*, 1991, 1994). Removing the radiological abnormalities is therefore no guarantee that the residual tissue is all normal. Standardization, cost-effectiveness and extent of additional information provided by intraoperative EcoG to ensure ‘complete’ removal of any epileptogenic tissue remain to be defined in FLE (Ferrier *et al.*, 2001). The second caveat is that even when an epileptogenic lesion is well-delineated, ‘complete’ resection may not be possible because of frequent overlap with eloquent cortex in the frontal lobe.

Post-operative predictors

A poorly understood prognostic indicator has traditionally been the presence of APOS. In our series, APOS occurred in 20 patients (29%), of whom 16 (80%) developed persistent seizures. While many studies evaluating seizures within 1 week following temporal lobectomy uniformly showed worse outcomes (Garcia *et al.*, 1991; Luders *et al.*, 1994; Salanova *et al.*, 1996; Malla *et al.*, 1998; Radhakrishnan *et al.*,

2003; Spencer *et al.*, 2005), only one study to date assessed the significance of APOS following FLE surgery (Tigaran *et al.*, 2003). Contrary to our finding that APOS predict seizure recurrence (RR = 2.17, 95% CI = 1.50–3.14), Tigaran *et al.* found that FLE patients who had APOS had a seizure-free outcome similar to that of individuals without APOS, but appeared less likely to have a favourable outcome (i.e. fewer than 3 seizures/year and >95% decrease in seizure activity). Their results may not have reached statistical significance because of small sample size, or alternatively because their study evaluated outcome at last follow-up only and controlled for age, sex, presence of APOS risk factors and surgical complications but not other predictors of outcome after FLE surgery such as aetiology and completeness of resection. Data on APOS following temporal lobectomy suggest that they reflect residual epileptogenic tissue (Salanova *et al.*, 1996), or a more diffuse ‘intractability factor’ independent of pre-operative pathology type (McIntosh *et al.*, 2005). The same could apply following surgery for FLE, where epileptogenic processes are even more diffuse. In this study we did not address whether the type of APOS (similar to pre-operative seizures versus atypical seizures) affected outcome.

Post-operative auras were more frequent in surgical failures, but did not achieve statistical significance as an independent predictor of outcome ($P = 0.0675$). This could be explained by the small sample size and the retrospective study design where the accurate assessment of the onset and timing of subtle aura symptoms is limited. Alternatively, based on their correlation with MRI-negative MCD and incomplete surgical resection in our cohort, one could postulate that such auras simply represent the earliest symptom of a residual diffuse epileptogenic tissue.

Conclusions

We report the first longitudinal outcome study on 70 FLE patients evaluated using modern diagnostic techniques. We show that frontal lobectomy can be a successful treatment option in selected patients with refractory epilepsy, with long-term seizure-freedom rates of up to 40%. Eighty per cent of seizure recurrences occur within the first 6 months following surgery. Ideal surgical candidates are those in whom there is MRI and electrophysiological evidence of epileptogenicity that is restricted to the frontal lobe, and in whom a complete resection of the epileptogenic zone is possible.

References

- Adam C, Baulac M, Saint-Hilaire JM, Landau J, Granat O, Laplane D. Value of magnetic resonance imaging-based measurements of hippocampal formations in patients with partial epilepsy. *Arch Neurol* 1994; 51: 130–8.
- Armon C, Radtke RA, Friedman AH, Dawson DV. Predictors of outcome of epilepsy surgery: multivariate analysis with validation. *Epilepsia* 1996; 37: 814–21.
- Awad IA, Rosenfeld J, Ahl J, Hahn JF, Luders H. Intractable epilepsy and structural lesions of the brain: mapping, resection strategies, and seizure outcome. *Epilepsia* 1991; 32: 179–86.

- Cascino GD, Jack CR Jr, Parisi JE, Marsh WR, Kelly PJ, Sharbrough FW, et al. MRI in the presurgical evaluation of patients with frontal lobe epilepsy and children with temporal lobe epilepsy: pathologic correlation and prognostic importance. *Epilepsy Res* 1992; 11: 51–9.
- Cascino GD, Jack CR Jr, Sharbrough FW, Kelly PJ, Marsh WR. MRI assessments of hippocampal pathology in extratemporal lesional epilepsy. *Neurology* 1993; 43: 2380–2.
- Chung CK, Lee SK, Kim KJ. Surgical outcome of epilepsy caused by cortical dysplasia. *Epilepsia* 2005; 46 Suppl 1: 25–9.
- Fausser S, Huppertz HJ, Bast T, Strobl K, Pantazis G, Altenmueller DM, et al. Clinical characteristics in focal cortical dysplasia: a retrospective evaluation in a series of 120 patients. *Brain* 2006; 129: 1907–16.
- Ferrier CH, Engelsman J, Alarcon G, Binnie CD, Polkey CE. Prognostic factors in presurgical assessment of frontal lobe epilepsy. *J Neurol Neurosurg Psychiatry* 1999; 66: 350–6.
- Ferrier CH, Alarcon G, Engelsman J, Binnie CD, Koutroumanidis M, Polkey CE, et al. Relevance of residual histologic and electrocorticographic abnormalities for surgical outcome in frontal lobe epilepsy. *Epilepsia* 2001; 42: 363–71.
- Fish DR, Smith SJ, Quesney LF, Andermann F, Rasmussen T. Surgical treatment of children with medically intractable frontal or temporal lobe epilepsy: results, highlights of 40 years' experience. *Epilepsia* 1993; 34: 244–7.
- Foldvary N, Nashold B, Mascha E, Thompson EA, Lee N, McNamara JO, et al. Seizure outcome after temporal lobectomy for temporal lobe epilepsy: a Kaplan-Meier survival analysis. *Neurology* 2000; 54: 630–4.
- Garcia PA, Barbaro NM, Laxer KD. The prognostic value of postoperative seizures following epilepsy surgery. *Neurology* 1991; 41: 1511–2.
- Hosking PG. Surgery for frontal lobe epilepsy. *Seizure* 2003; 12: 160–6.
- Janszky J, Jokeit H, Schulz R, Hoppe M, Ebner A. EEG predicts surgical outcome in lesional frontal lobe epilepsy. *Neurology* 2000; 54: 1470–6.
- Jeha LE, Najm IM, Bingaman WE, Khandwala F, Widdess-Walsh P, Morris HH, et al. Predictors of outcome after temporal lobectomy for the treatment of intractable epilepsy. *Neurology* 2006; 66: 1938–40.
- Jobst BC, Siegel AM, Thadani VM, Roberts DW, Rhodes HC, Williamson PD. Intractable seizures of frontal lobe origin: clinical characteristics, localizing signs, and results of surgery. *Epilepsia* 2000; 41: 1139–52.
- Jutila L, Immonen A, Mervaala E, Partanen J, Partanen K, Puranen M, et al. Long term outcome of temporal lobe epilepsy surgery: analyses of 140 consecutive patients. *J Neurol Neurosurg Psychiatry* 2002; 73: 486–94.
- Kelley K, Theodore WH. Prognosis 30 years after temporal lobectomy. *Neurology* 2005; 64: 1974–6.
- Kim YK, Lee DS, Lee SK, Chung CK, Chung JK, Lee MC. (18)F-FDG PET in localization of frontal lobe epilepsy: comparison of visual and SPM analysis. *J Nucl Med* 2002; 43: 1167–74.
- Kral T, Kuczaty S, Blumcke I, Urbach H, Clusmann H, Wiestler OD, et al. Postsurgical outcome of children and adolescents with medically refractory frontal lobe epilepsies. *Childs Nerv Syst* 2001; 17: 595–601.
- Lee SK, Choe G, Hong KS, Nam HW, Kim JY, Chung CK, et al. Neuroimaging findings of cortical dyslamination with cytomegaly. *Epilepsia* 2001; 42: 850–6.
- Lee SK, Lee SY, Kim KK, Hong KS, Lee DS, Chung CK. Surgical outcome and prognostic factors of cryptogenic neocortical epilepsy. *Ann Neurol* 2005; 58: 525–32.
- Li LM, Cendes F, Andermann F, Watson C, Fish DR, Cook MJ, et al. Surgical outcome in patients with epilepsy and dual pathology. *Brain* 1999; 122: 799–805.
- Lorenzo NY, Parisi JE, Cascino GD, Jack CR Jr, Marsh WR, Hirschorn KA. Intractable frontal lobe epilepsy: pathological and MRI features. *Epilepsy Res* 1995; 20: 171–8.
- Luders H, Murphy D, Awad I, Wyllie E, Dinner DS, Morris HH III, et al. Quantitative analysis of seizure frequency 1 week and 6, 12, and 24 months after surgery of epilepsy. *Epilepsia* 1994; 35: 1174–8.
- Luders H, Acharya J, Baumgartner C, Benbadis S, Bleasel A, Burgess R, et al. Semiological seizure classification. *Epilepsia* 1998; 39: 1006–13.
- Malla BR, O'Brien TJ, Cascino GD, So EL, Radhakrishnan K, Silbert P, et al. Acute postoperative seizures following anterior temporal lobectomy for intractable partial epilepsy. *J Neurosurg* 1998; 89: 177–82.
- Mariottini A, Lombroso CT, DeGirolami U, Fois A, Buoni S, DiTroia AM, et al. Operative results without invasive monitoring in patients with frontal lobe epileptogenic lesions. *Epilepsia* 2001; 42: 1308–15.
- McIntosh AM, Kalnins RM, Mitchell LA, Fabinyi GC, Briellmann RS, Berkovic SF. Temporal lobectomy: long-term seizure outcome, late recurrence and risks for seizure recurrence. *Brain* 2004; 127: 2018–30.
- McIntosh AM, Kalnins RM, Mitchell LA, Berkovic SF. Early seizures after temporal lobectomy predict subsequent seizure recurrence. *Ann Neurol* 2005; 57: 283–8.
- Montenegro MA, Li LM, Guerreiro MM, Guerreiro CA, Cendes F. Focal cortical dysplasia: improving diagnosis and localization with magnetic resonance imaging multiplanar and curvilinear reconstruction. *J Neuroimaging* 2002; 12: 224–30.
- Mosewich RK, So EL, O'Brien TJ, Cascino GD, Sharbrough FW, Marsh WR, et al. Factors predictive of the outcome of frontal lobe epilepsy surgery. *Epilepsia* 2000; 41: 843–9.
- Olivier A. Surgery of frontal lobe epilepsy. *Adv Neurol* 1995; 66: 321–48; discussion 348–52.
- Palmini A, Andermann F, Olivier A, Tampieri D, Robitaille Y, Andermann E, et al. Focal neuronal migration disorders and intractable partial epilepsy: a study of 30 patients. *Ann Neurol* 1991; 30: 741–9.
- Palmini A, Andermann E, Andermann F. Prenatal events and genetic factors in epileptic patients with neuronal migration disorders. *Epilepsia* 1994; 35: 965–73.
- Radhakrishnan K, So EL, Silbert PL, Cascino GD, Marsh WR, Cha RH, et al. Prognostic implications of seizure recurrence in the first year after anterior temporal lobectomy. *Epilepsia* 2003; 44: 77–80.
- Rasmussen T. Tailoring of cortical excisions for frontal lobe epilepsy. *Can J Neurol Sci* 1991; 18: 606–10.
- Salanova V, Quesney LF, Rasmussen T, Andermann F, Olivier A. Reevaluation of surgical failures and the role of reoperation in 39 patients with frontal lobe epilepsy. *Epilepsia* 1994; 35: 70–80.
- Salanova V, Andermann F, Rasmussen T, Olivier A, Quesney L. The running down phenomenon in temporal lobe epilepsy. *Brain* 1996; 119: 989–96.
- Schmidt D, Baumgartner C, Loscher W. Seizure recurrence after planned discontinuation of antiepileptic drugs in seizure-free patients after epilepsy surgery: a review of current clinical experience. *Epilepsia* 2004; 45: 179–86.
- Schramm J, Kral T, Kurthen M, Blumcke I. Surgery to treat focal frontal lobe epilepsy in adults. *Neurosurgery* 2002; 51: 644–54; discussion 654–5.
- Schwartz TH, Jeha L, Tanner A, Bingaman W, Sperling MR. Late seizures in patients initially seizure free after epilepsy surgery. *Epilepsia* 2006; 47: 567–73.
- Smith JR, Lee MR, King DW, Murro AM, Park YD, Lee GP, et al. Results of lesional vs. nonlesional frontal lobe epilepsy surgery. *Stereotact Funct Neurosurg* 1997; 69: 202–9.
- Spencer SS, Berg AT, Vickrey BG, Sperling MR, Bazil CW, Shinnar S, et al. Multicenter Study of Epilepsy Surgery. Predicting long-term seizure outcome after resective epilepsy surgery: the Multicenter Study. *Neurology* 2005; 65: 912–8.
- Sperling MR, O'Connor MJ, Saykin AJ, Plummer C. Temporal lobectomy for refractory epilepsy. *JAMA* 1996; 276: 470–5.
- Swartz BE, Delgado-Escueta AV, Walsh GO, Rich JR, Dwan PS, DeSalles AA, et al. Surgical outcomes in pure frontal lobe epilepsy and foci that mimic them. *Epilepsy Res* 1998; 29: 97–108.
- Talairach J, Bancaud J, Bonis A, Szikla G, Trottier S, Vignal JP, et al. Surgical therapy for frontal epilepsies. *Adv Neurol* 1992; 57: 707–32.
- Tassi L, Colombo N, Garbelli R, Francione S, Lo Russo G, Mai R, et al. Focal cortical dysplasia: neuropathological subtypes, EEG, neuroimaging and surgical outcome. *Brain* 2002; 125: 1719–32.
- Tigaran S, Cascino GD, McClelland RL, So EL, Richard Marsh W. Acute postoperative seizures after frontal lobe cortical resection for intractable partial epilepsy. *Epilepsia* 2003; 44: 831–5.

- Tran TA, Spencer SS, Javidan M, Pacia S, Marks D, Spencer DD. Significance of spikes recorded on intraoperative electrocorticography in patients with brain tumor and epilepsy. *Epilepsia* 1997; 38: 1132–9.
- Urbach H, Scheffler B, Heinrichsmeier T, von Oertzen J, Kral T, Wellmer J, et al. Focal cortical dysplasia of Taylor's balloon cell type: a clinicopathological entity with characteristic neuroimaging and histopathological features, and favorable postsurgical outcome. *Epilepsia* 2002; 43: 33–40.
- Wennberg R, Quesney LF, Lozano A, Olivier A, Rasmussen T. Role of electrocorticography at surgery for lesion-related frontal lobe epilepsy. *Can J Neurol Sci* 1999; 26: 33–9.
- Widdess-Walsh P, Kellinghaus C, Jeha L, Kotagal P, Prayson R, Bingaman W, et al. Electro-clinical and imaging characteristics of focal cortical dysplasia: correlation with pathological subtypes. *Epilepsy Res* 2005; 67: 25–33.
- Wieser HG, Hajek M. Frontal lobe epilepsy. Compartmentalization, presurgical evaluation, and operative results. *Adv Neurol* 1995; 66: 297–318; discussion 318–9.
- Wieser HG, Blume WT, Fish D, Goldensohn E, Hufnagel A, King D, et al. Commission on Neurosurgery of the International League Against Epilepsy (ILAE). ILAE commission report. Proposal for a new classification of outcome with respect to epileptic seizures following epilepsy surgery. *Epilepsia* 2001; 42: 282–6.
- Wyllie E, Comair YG, Kotagal P, Bulacio J, Bingaman W, Ruggieri P. Seizure outcome after epilepsy surgery in children and adolescents. *Ann Neurol* 1998; 44: 740–8.
- Yoon HH, Kwon HL, Mattson RH, Spencer DD, Spencer SS. Long-term seizure outcome in patients initially seizure-free after resective epilepsy surgery. *Neurology* 2003; 61: 445–50.
- Yun CH, Lee SK, Lee SY, Kim KK, Jeong SW, Chung CK. Prognostic factors in neocortical epilepsy surgery: multivariate analysis. *Epilepsia* 2006; 47: 574–9.
- Zaatreh MM, Spencer DD, Thompson JL, Blumenfeld H, Novotny EJ, Mattson RH, et al. Frontal lobe tumoral epilepsy: clinical, neurophysiologic features and predictors of surgical outcome. *Epilepsia* 2002; 43: 727–33.
- Zentner J, Hufnagel A, Ostertun B, Wolf HK, Behrens E, Campos MG, et al. Surgical treatment of extratemporal epilepsy: clinical, radiologic, and histopathologic findings in 60 patients. *Epilepsia* 1996; 37: 1072–80.