

# Auditory verbal hallucinations predominantly activate the *right* inferior frontal area

Iris E. C. Sommer,<sup>1</sup> Kelly M. J. Diederer,<sup>1</sup> Jan-Dirk Blom,<sup>2,3</sup> Anne Willems,<sup>1</sup> Leila Kushan,<sup>1</sup> Karin Slotema,<sup>2</sup> Marco P. M. Boks,<sup>1</sup> Kirstin Daalman,<sup>1</sup> Hans W. Hoek,<sup>2,3</sup> Sebastiaan F. W. Neggers<sup>1</sup> and René S. Kahn<sup>1</sup>

<sup>1</sup>Neuroscience Division, University Medical Center Utrecht and Rudolf Magnus Institute for Neuroscience, Utrecht, <sup>2</sup>Parnassia PsychoMedical Center, The Hague and <sup>3</sup>Department of Psychiatry, University Medical Center Groningen, Groningen, The Netherlands

Correspondence to: Iris Sommer, MD, PhD, Neuroscience Division, University Medical Center Utrecht & Rudolf Magnus Institute for Neuroscience, B01.206, Heidelberglaan 100, 3485CX, Netherlands  
E-mail: i.sommer@umcutrecht.nl

**The pathophysiology of auditory verbal hallucinations (AVH) is largely unknown. Several functional imaging studies have measured cerebral activation during these hallucinations, but sample sizes were relatively small (one to eight subjects) and findings inconsistent. In this study cerebral activation was measured using fMRI in 24 psychotic patients while they experienced AVH in the scanner and, in another session, while they silently generated words. All patients were right handed and diagnosed with schizophrenia, schizo-affective disorder or psychotic disorder not otherwise specified. Group analysis for AVH revealed activation in the right homologue of Broca's area, bilateral insula, bilateral supramarginal gyri and right superior temporal gyrus. Broca's area and left superior temporal gyrus were not activated. Group analysis for word generation in these patients yielded activation in Broca's and Wernicke's areas and to a lesser degree their right-sided homologues, bilateral insula and anterior cingulate gyri. Lateralization of activity during AVH was not correlated with language lateralization, but rather with the degree to which the content of the hallucinations had a negative emotional valence. The main difference between cerebral activity during AVH and activity during normal inner speech appears to be the lateralization. The predominant engagement of the right inferior frontal area during AVH may be related to the typical low semantic complexity and negative emotional content.**

**Keywords:** auditory verbal hallucinations; fMRI; Broca's area; lateralization

**Abbreviations:** AAL = anatomical automatic labelling; AHRS = Auditory Hallucinations Rating Scale; AVH = auditory verbal hallucinations; CASH = comprehensive assessment of symptoms and history; DLPFC = dorsolateral prefrontal cortex; FDR = false discovery rate; FWHM = full width at half maximum; PANSS = Positive and Negative Syndromes Scale; PSYRATS = Psychotic Symptom Rating Scales

Received April 24, 2008. Revised September 5, 2008. Accepted September 9, 2008. Advance Access publication October 13, 2008

## Introduction

Auditory verbal hallucinations (AVH) are a cardinal feature of psychosis (David, 1999). Indeed, in schizophrenia the one month prevalence of these hallucinations exceeds 70% (Sartorius *et al.*, 1986) and in 25–30% of patients these perceptions are resistant to medication, leading to functional disability and a low quality of life (Shergill *et al.*, 1998; Copolov *et al.*, 2004). Therapeutic options for these patients are currently sparse and the development of new therapeutic strategies would benefit from better knowledge of the pathophysiology of AVH.

Despite several functional imaging studies, the neuro-pathological mechanism of the disorder has remained

unclear, possibly as a result of the complexity of scanning cerebral activation during hallucinations. Specifically, patients are required to experience AVH for a substantial part of the scan time in order to generate enough power for a meaningful comparison between activity during hallucinations and the baseline. On the other hand, patients should not hallucinate continuously, since sufficiently long epochs without hallucinations are needed for a useful comparison with hallucinating periods. This may explain why sample sizes of previous functional imaging studies that have assessed cerebral activation *during* AVH have been small, ranging from one to eight patients (Silbersweig *et al.*, 1995; Woodruff *et al.*, 1995; Dierks *et al.*, 1999;

Lennox *et al.*, 1999, 2000; Shergill *et al.*, 2000, 2001; Copolov *et al.*, 2003; Hoffman *et al.*, 2007). Apart from the small sample sizes, previous studies applied rather liberal thresholds for significance. This combination can easily result in both type I and type II errors, which may have created inconsistent results regarding which areas are activated during hallucinations (reviewed by Stephane *et al.*, 2001 and Allen *et al.*, 2008). For example, Silbersweig *et al.* (1995) observed activation predominantly in subcortical structures, while Shergill *et al.* (2000) found activation of Broca's area and bilateral temporal cortices. Dierks *et al.* (1999) reported hallucinatory activity in the primary auditory cortex, which could not be replicated by Copolov *et al.* (2003) who instead observed prominent activity in the parahippocampal gyrus. The largest sample of patients hallucinating during fMRI recordings to date was reported recently by Hoffman *et al.* (2007) who found activity during AVH in temporal and frontal areas of both hemispheres in eight patients. Since it has been shown that over 20 subjects are needed in a typical fMRI experiment to obtain appropriate reproducibility (Desmond *et al.*, 2002; Thirion *et al.*, 2007), we acquired fMRI scans of 24 psychotic patients while they were experiencing AVH. Since these perceptions obviously consist of words or sentences, we hypothesized that this analysis would reveal activity in language-related structures, such as Broca's and Wernicke's areas. Apart from these classical language areas, AVH may activate other brain regions that could be specific to the presence of hallucinations. In a previous study (Sommer *et al.*, 2007), we found that the majority of schizophrenia patients showed prominent activity in the right-sided homologues of the classical language areas during AVH (i.e. in the right inferior frontal gyrus, right superior temporal and supramarginal gyrus), while normal language is generally produced in the left hemisphere in right-handed subjects. To explore a difference in lateralization between hallucinatory activation and normal language production, the same patients also performed a silent word generation task while fMRI scans were acquired.

## Method

### Subjects

Subjects were included who experienced frequent AVH as well as frequent moments without these hallucinations. Twenty-four right-handed patients with a diagnosis of schizophrenia-spectrum disorder participated in this study. All subjects used antipsychotic medication during the study, but continued frequently to experience AVH. The clinical characteristics of the patients are summarized in Table 1.

Patients were diagnosed using the Comprehensive Assessment of Symptoms and History (CASH) (Andreasen *et al.*, 1992) according to DSM-IV criteria by an independent psychiatrist. All subjects were strongly right-handed as assessed by the Edinburgh Handedness Inventory (Oldfield, 1971). The Positive and Negative Syndromes Scale (PANSS) (Kay *et al.*, 1987) was used for assessment of symptoms over the last week. Detailed characteristics of

**Table 1** Clinical description of the 24 participants

Age	37 years (SD 10)
Age at onset AVH	22 years (SD 12)
Diagnosis	18 schizophrenia 3 schizo-affective disorder 3 psychosis not otherwise specified
Medication	13 clozapine, mean dose 316 mg 4 flupentixol depot, mean dose 16 mg/week 1 haloperidol depot 50 mg/week 1 chlorprotixen 200 mg 1 olanzapine 30 mg 2 risperidone, mean dose 4 mg 2 quetiapine, mean dose 600 mg
Sex	17 male 7 female

the hallucinations were assessed using the Psychotic Symptom Rating Scales-Auditory Hallucinations Rating Scale (PSYRATS-AHRS) (Haddock *et al.*, 1999). Clinical ratings were performed on the day of the fMRI scan by trained interviewers.

The study was approved by the Human Ethics Committee of the University Medical Center, Utrecht. After a complete description of the study was provided to the subjects, written informed consent was obtained according to the Declaration of Helsinki.

### Experimental design and data acquisition

Activation during hallucinations was measured over 8 min, during which fMRI scans were made continuously. Patients were instructed to squeeze a balloon when they experienced AVH, and to release it when the hallucinations subsided (adapted from Hoffman *et al.*, 2007). Language activation was also measured, again over 8 min during which a paced letter fluency task was presented. Patients were asked to silently generate a word starting with the letter displayed on a screen placed in front of them. Letters were presented in eight activation blocks, each block lasting 30 s. In each activation block 10 different letters were displayed at a rate of one letter every 3 s. As a reference, a cross-hair was projected on the screen. After finishing the language activation task, two additional letter fluency trials were presented, in which subjects had to generate words aloud, without the scanner noise. These two blocks were used to measure behavioural performance of the subjects while they were in the scanner.

Activation maps were obtained using a Philips Achieva 3 Tesla Clinical MRI scanner.

In order to improve the power to detect significant activation, we applied a very fast scan sequence; the 3D PRESTO SENSE sequence, developed in-house (Neggers *et al.*, 2008), which achieves full brain coverage within 0.609 s. This was important because we intended to be as sensitive as possible for BOLD signal changes during the periods of hallucination. The patients investigated here are difficult to study in an MR environment because the sometimes brief hallucination periods are unpredictable, and not all patients tolerate long scanning sessions well. This scan sequence combines a 3D-PRESTO pulse sequence with parallel imaging (SENSE) in two directions using a commercial 8-channel SENSE. First, the shifted echo of PRESTO (readout of excited signal after the next excitation pulse) ensured very efficient readout, using the normally unused time between excitation and the optimal echo train for BOLD contrast. Next, multiple receiver

coils in modern parallel imaging techniques allow that every second line (or more) in K-space to be skipped, compensated for by opposing receiver coil sensitivity profiles (SENSE, see Pruesmann *et al.*, 1999) which greatly accelerates acquisition. SENSE is a new parallel imaging technique optimally using multiple receiver head coils that can be used to either increase imaging speed or resolution (de Zwart *et al.*, 2006). Recently SENSE has become commercially available on Philips Achieva MR scanners. We successfully implemented this technique for fMRI (Neggens *et al.*, 2008). Finally, when using 3D acquisition as in PRESTO, K-space is 3D and this accelerated readout technique can be applied in two dimensions (here LR and AP). Mainly because the almost 4-fold number of volumes acquired in the same amount of scanning time, BOLD signal changes are detected with a higher sensitivity as compared to conventional 2D-EPI of about 2 s/volume. Eight hundred 3D PRESTO sensitivity encoding (SENSE) images depicting BOLD contrast were acquired with the following parameter settings: 40 (coronal) slices, TR/TE 21.75/32.4 ms, flip angle 10°, FOV 224 × 256 × 160, matrix 64 × 64 × 40, voxel size 4 mm isotropic. Since these PRESTO SENSE images have little anatomical contrast, an identical scan, but with a flip angle of 27° (fa27) was made to improve realignment and co-registration during the preprocessing. After completion of the functional scans, a high resolution anatomical scan, with the following parameters: TR/TE: 9.86/4.6 ms, 1 × 1 × 1 voxels, flip angle 8°, was acquired to improve localization of the functional data.

## Data analysis

### Preprocessing

fMRI data were analysed using statistical parametric mapping (SPM2; Wellcome Department of Cognitive Neurology, London, UK). Preprocessing included reorientation and within-subject image realignment with rigid-body transformations using the fa27 as the reference to correct for the effects of head motion. After co-registration of the fa27 and the anatomical image and spatial normalization to a standard MNI template, images were smoothed using an 8-mm full width at half maximum (FWHM) Gaussian kernel.

### Statistical analysis of fMRI responses

In order to compare hallucination periods to non-hallucinating (resting) periods during the hallucination paradigm, an activation model was created using balloon squeezes as signalling the hallucination onset and the time between squeezes and releases as the duration of the AVH. This model was co-evolved with the standardized haemodynamic response function from SPM2 to introduce typical delays of fMRI responses, and fitted to the data using a GLM estimation (Friston *et al.*, 1995). These hallucination periods were then compared to non-hallucinating (resting) scans.

Similarly, for the letter fluency paradigm an activation model was created to contrast activity during presentation of the letters versus rest blocks. Functional images were analysed on a voxel basis using multiple regression analysis (Worsley and Friston, 1995) with one factor coding for activation (task versus rest). Following the first level analyses, second level random-effects analyses were conducted for both the hallucination and the letter fluency paradigm to determine activation on a group-level (one sample *t*-tests). All thresholds corresponded to a  $P < 0.05$  corrected for all voxels in the brain by the false discovery rate (FDR) (Benjamini and Hochberg, 1995).

In addition to the group analyses for the hallucinations and the letter fluency task, a multiple regression analysis without a constant, and hallucinations and letter fluency as the two covariates, was used to conduct a random effects group-wise conjunction analysis (Price and Friston, 1997). A conjunction analysis identifies a ‘common processing component’ for two or more tasks by finding areas activated in independent subtractions (hallucinations versus rest and letter fluency versus rest).

Finally, lateralization indices were calculated on individual *t*-tests for both the letter fluency and the hallucination paradigm. For this purpose, a mask was created using the Anatomical Automatic Labeling (AAL) atlas (Tzourio-Mazoyer *et al.*, 2002) comprising the main areas where language processing is thought to be mediated and their contralateral homologues (Springer *et al.*, 1999). Language areas consisted of the inferior frontal triangle, the insula, the middle temporal gyrus, the superior temporal gyrus, the supramarginal gyrus and the angular gyrus. Lateralization indices were defined as the difference in ‘thresholded’ signal intensity changes in the left versus the right hemisphere (within the selected language regions) divided by the total sum of ‘thresholded’ signal intensity changes. Using this method, activity measures are based on signal intensity changes in those voxels that exceed a predefined activation level, as recommended by Jansen *et al.* (2006). Differences in lateralization indices between the hallucination and the letter fluency activation were compared by means of a paired sample *t*-test.

Pearson’s correlations were used to assess associations between subjective loudness of the AVH and activation of Heschl’s gyrus, number of voices associated with activation of the superior temporal gyrus, and correlation between the lateralization index of AVH activity and the degree to which the emotional content of the AVH was scored as negative. A difference in activation during AVH between individuals with voices inside or outside the head was tested by direct comparison of patient groups.

## Results

### Clinical evaluation

Subjects were chronically psychotic with a mean total PANSS score of 73 (SD 13). The mean score on the positive subscale was 19 (SD 4), as was the mean score on the negative subscale (19, SD 4).

The phenomenology of voices interview showed that patients on average experienced AVH several times per hour with a mean duration of a few minutes. Most patients heard the voices both within their head as well as coming from outside their head, but located close to the ears. On average, the loudness of the experienced voices was described as comparable to normal speaking. Most patients described the voices as coming from the outside world, rather than attributing them to an internal source. Though all 24 patients had a strict personal content of their voices, they did have several aspects in common. There appeared to be two main themes in the content of AVH: the vast majority (18 patients) heard voices with a derogatory content, for example voices calling them names or telling them to hurt/kill themselves. A smaller group, consisting of six patients, experienced more neutral voices commenting on their thoughts and actions. Details about the AVH, as

rated with the PSYRATS-AHRS interview are listed in Table 2.

### Performance during the functional scans

The mean number of hallucinations during the 8 min hallucination scans was 18 (SD 13). The mean duration of a hallucination was 20 s (SD 36), adding up to a mean total duration of the hallucinations of 362 s (SD 144).

For the letter fluency task, the 24 patients showed a mean accuracy of 19.2 words (SD 1.4), which is a 96% (SD 7) correct performance. Eight of the participants reported AVH during the language task. All eight patients indicated that the hallucinations were present during the language blocks as well as in the rest condition, which indicates that it will be lost in the subtraction. A between-group test comparing these eight patients to the others showed no significant differences, although this may partly be attributed to limited power.

### fMRI results

#### Group analysis AVH

The group analysis for AVH revealed activation in multiple brain regions. Most extended activation was found in the right inferior frontal area, including the right insula and

**Table 2** Specific aspects of the AVH, as quantified with the PSYRATS-AHRS interview

Item PSYRATS	Range	Mean (SD)
Frequency	0–4	3.5 (0.9)
Duration	0–4	2 (1)
Location	0–4	1.9 (1)
Loudness	0–4	1.8 (0.9)
Beliefs about source	0–3	2.8 (1.1)
Negative content	0–4	3 (1)
Severity of negativity	0–4	2.6 (0.8)
Distress	0–4	3 (1.2)
Intensity of distress	0–4	2.7 (0.9)
Control over AVH	0–4	3.3 (1.1)
Number of voices	0–...	13.1 (11.5)

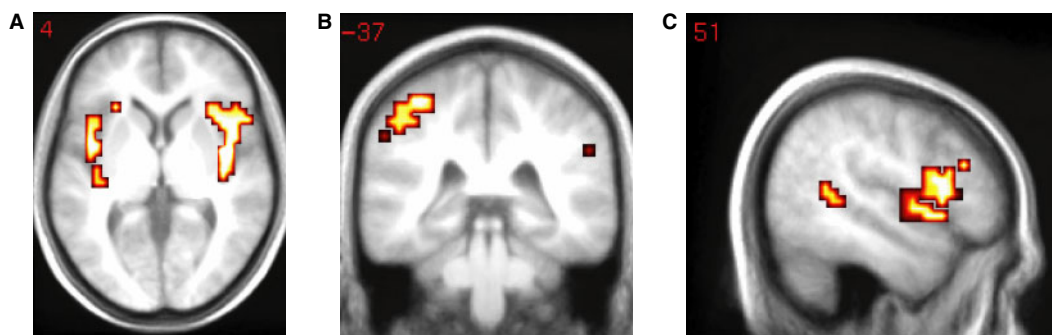
Broca's homologue (Fig. 1A and C). Other regions with significant activation during AVH included the left insula, the bilateral supramarginal gyri (Fig. 1B) and the right superior temporal gyrus (Fig. 1C). Broca's area and the left superior temporal gyrus were not significantly activated. There was also highly significant activation in the left motor cortex and the right cerebellum, most likely as a result of the balloon squeezes. Table 3 shows the coordinates of all local maxima significantly activated in the group analysis.

#### Group analysis language task

The group analysis for the language task revealed extensive activation of multiple confluent brain regions. These regions included Broca's area and to a lesser degree its contralateral homologue, both extending into the insula (Fig. 2A), the bilateral temporal area (superior and middle gyri), left more than right (Fig. 2B), and the anterior cingulate gyri (Fig. 2C). For more clarity with respect to the different functional regions implicated in the group letter fluency analysis, several masks, created with the AAL atlas (Tzourio-Mazoyer *et al.*, 2002) are overlaid on the group results. Anatomic regions were chosen based on the locations of significantly activated local maxima in the group letter fluency analysis. Masks consisted of the bilateral inferior frontal gyrus, middle frontal gyrus, superior frontal gyrus, precentral gyrus, insula, thalamus, anterior cingulum, fusiform gyrus, middle temporal gyrus, superior temporal gyrus, superior parietal lobule, inferior parietal lobule, middle occipital gyrus and cerebellum. For every masked region, the amount of voxels significantly activated, the coordinates of the local maximum and its z-score are reported in Table 4. The table also shows the coordinates of all local maxima significantly activated in the group analysis; note that activation is confluent between many of these local maxima.

#### Conjunction analysis

The group conjunction analysis showed several areas that were significantly activated in both paradigms which consisted of the right inferior frontal gyrus including Broca's homologue, the right dorsolateral prefrontal cortex (DLPFC), the left



**Fig. 1** SPM(T)'s for the group hallucination analysis,  $n = 24$ .

insula and the right anterior insula. The SPM(T)s from this analysis are shown in Fig. 3. Table 5 provides the location of the maximum voxels in these regions.

### Lateralization

The mean lateralization index was  $-0.11$  (SD 0.41) for the hallucination paradigm and  $0.14$  (SD 0.34) for the word generation task. The paired sample *t*-test revealed significantly lower lateralization during AVH as compared to covert word generation [ $t(23) = -2.4$ ,  $P < 0.02$ ].

The individual lateralization indices of hallucinatory activation were not correlated to the lateralization indices of word generation (Pearson's  $\rho = 0.11$ ,  $P = 0.63$ , shown in Fig. 4).

There was no association between subjective loudness of the AVH and activation of Heschl's gyrus (Pearson's  $\rho = -0.06$ ,  $P = 0.77$ ), nor was the number of voices associated

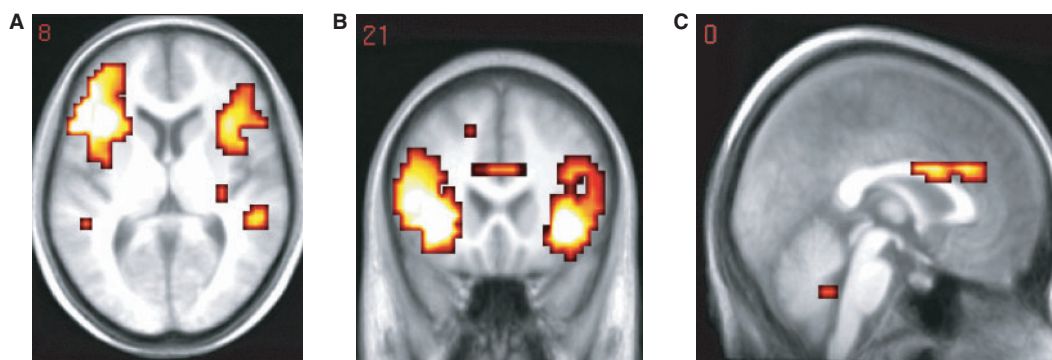
with activation of the superior temporal gyrus ( $\rho = -0.05$ ,  $P = 0.82$ ). We could not find a difference in activation during AVH between individuals with voices inside or outside the head. The negative emotional content of the AVH, as rated on item 6 of the PSYRATS, correlated with the lateralization index of the AVH (Pearson's  $\rho = -0.5$ ,  $P = 0.01$ ), with a more negative emotional content of voices associated with stronger lateralization of hallucinatory activation to the right hemisphere (Fig. 5). Since four correlations are tested, Bonferroni correction identifies a *P*-value of maximal 0.0125 for significance, which is achieved for the association with negative emotional content ( $P = 0.01$ ).

### Discussion

This study investigated cerebral activity using fMRI in a sample of 24 psychotic patients while they were

**Table 3** z-Scores, cluster size and locations of local maxima active in the group hallucination analysis  $n = 24$

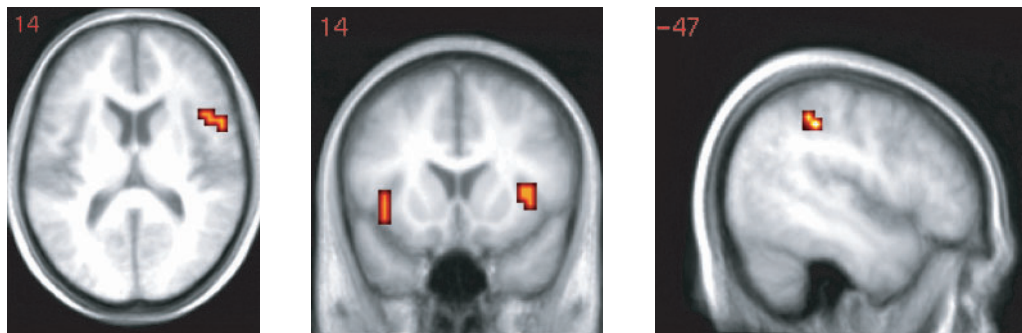
Lobe	Area	Coordinates			z-score	Cluster size
		x	y	z		
R sub-lobar	Insula	40	-4	4	5.13	466
R frontal lobe	Middle frontal gyrus, DLPFC	48	21	28	3.55	
R frontal lobe	Inferior frontal gyrus	28	27	-5	2.78	
R frontal lobe	Inferior frontal gyrus, Broca's homologue	44	16	10	3.24	
R temporal lobe	Superior temporal gyrus, Wernicke's homologue	51	11	-4	3.02	
L frontal lobe	Postcentral gyrus	-44	-17	45	4.64	227
L frontal lobe	Superior frontal gyrus	-20	-8	67	3.10	
L parietal lobe	Inferior parietal lobule, Supramarginal gyrus	-55	-37	39	3.07	
L sub-lobar	Insula	-44	0	4	3.47	79
L sub-lobar	Lentiform nucleus	-32	-4	0	3.70	
L frontal lobe	Precentral gyrus	-55	4	11	3.04	
L limbic lobe	Cingulate gyrus	-12	2	44	3.89	165
R frontal lobe	Medial frontal gyrus	8	3	62	3.69	
L frontal lobe	Medial frontal gyrus	-4	-9	48	3.49	
R cerebellum	Anterior lobe, Culmen	24	-52	-21	3.87	126
R cerebellum	Posterior lobe, Pyramis	20	-64	-30	3.14	
L parietal lobe	Postcentral gyrus	-55	-19	16	3.19	10
L cerebellum	Anterior lobe, Dentate gyrus	-20	-59	-24	3.31	60
R temporal lobe	Superior temporal gyrus	48	-46	13	3.06	11
R parietal lobe	Supramarginal gyrus	51	-37	30	3.02	12
L frontal lobe	Inferior frontal gyrus, DLPFC	-51	6	33	3.33	9



**Fig. 2** SPM(T)'s for the group language analysis,  $n = 24$ .

**Table 4** z-Scores, locations of local maxima active in the group letter fluency analysis  $n = 24$ 

Lobe	Area	Coordinates			z-score	N voxels
		x	y	z		
L frontal lobe	Inferior frontal gyrus	-56	12	16	6.31	366
R frontal lobe	Inferior frontal gyrus	36	24	-8	6.04	289
L frontal lobe	Middle frontal gyrus	-28	-4	52	5.17	125
R frontal lobe	Superior frontal gyrus	36	-4	60	5.08	116
L frontal lobe	Superior frontal gyrus	-24	-4	56	5.21	38
R frontal lobe	Superior frontal gyrus	32	-4	60	5.06	40
L frontal lobe	Precentral gyrus	-48	4	32	5.69	132
R frontal lobe	Precentral gyrus	48	4	32	6.03	65
L sub-lobar	Insula	-36	20	0	6.33	140
R sub-lobar	Insula	36	24	-4	6.63	115
L sub-lobar	Thalamus	-12	-8	12	3.85	50
R sub-lobar	Thalamus	12	-8	8	3.77	44
Limbic lobe	Anterior cingulum	4	8	28	4.72	58
L temporal lobe	Fusiform gyrus	-44	-56	-16	4.82	26
R temporal lobe	Fusiform gyrus	44	-56	-20	4.77	55
L temporal lobe	Middle temporal gyrus	-44	-64	-4	4.56	41
R temporal lobe	Middle temporal gyrus	52	-36	4	4.33	42
L temporal lobe	Superior temporal gyrus	-44	4	-12	3.41	5
R temporal lobe	Superior temporal gyrus	52	-36	8	4.13	20
L parietal lobe	Superior parietal lobule	-28	-60	48	5.32	73
R parietal lobe	Superior parietal lobule	32	-64	52	4.56	48
L parietal lobe	Inferior parietal lobule	-28	-56	44	5.36	181
R parietal lobe	Inferior parietal lobule	48	-44	52	4.71	65
L occipital lobe	Middle occipital gyrus	-28	-68	36	4.26	44
R occipital lobe	Middle occipital gyrus	28	-92	0	6.23	44
L cerebellum	Posterior lobe	-32	-60	-28	3.80	15
R cerebellum	Posterior lobe	23	-76	-24	5.36	235

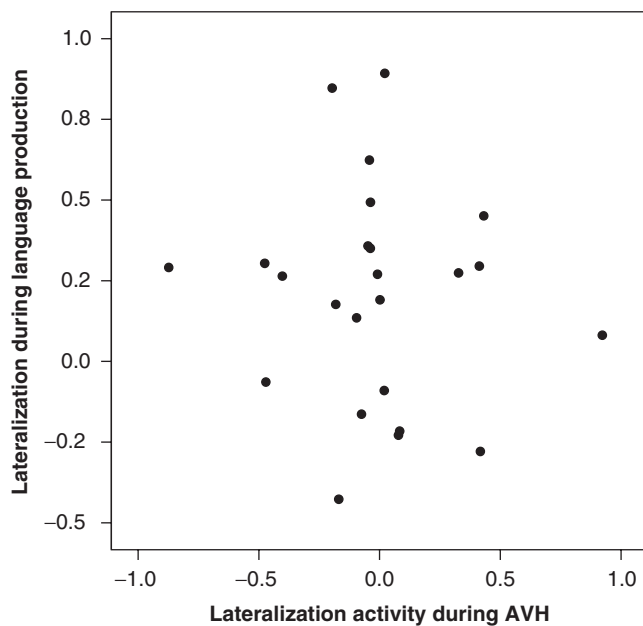
**Fig. 3** SPM(T)'s for the conjunction analysis language-hallucinations,  $n = 24$ .

experiencing AVH in the scanner. Results were contrasted to cerebral activity during normal language production (silent word generation) in the same patients. Group-wise analysis of activity during AVH yielded most extensive activation in the right inferior frontal area (including the right insula and the right homologue of Broca's area). Other areas that showed significantly increased activation during AVH were the superior temporal and supramarginal gyri (predominantly in the right hemisphere), and the left insula. Interestingly, Broca's area did not show significant activation during AVH, nor did

the left superior temporal gyrus. In contrast to activation during AVH, the group-wise analysis of the word production task yielded most pronounced activity in the left inferior frontal area (including Broca's area and the left dorsolateral prefrontal cortex) extending into the left insula, the left superior and middle temporal gyri and the anterior cingulate gyrus. The right-sided homologues of these areas were also activated, but to a smaller degree. Activation during inner speech was more extended as compared to hallucinatory activity, which primarily results from the difference in the applied paradigm. Inner speech was

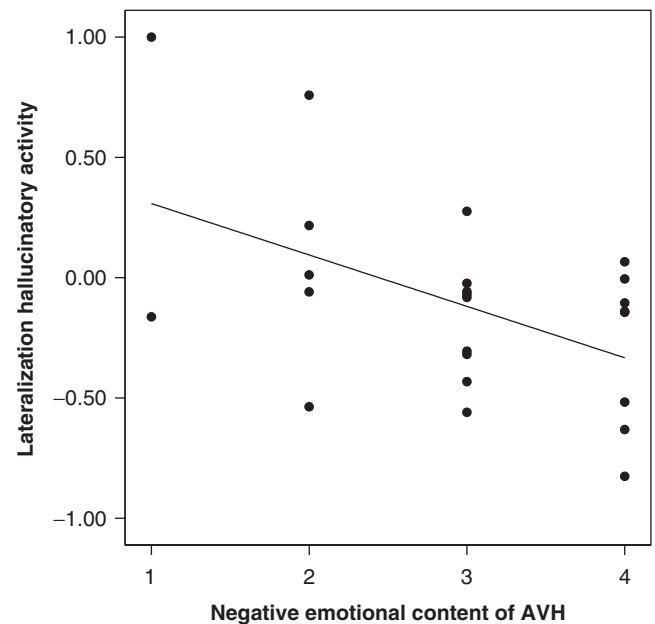
**Table 5** z-scores, cluster size and locations of local maxima active in the conjunction analysis,  $n = 24$ 

Lobe	Area	Coordinates			z-score	Cluster size	
		X	Y	Z			
R frontal lobe	Inferior frontal gyrus, ba 9 DLPFC	51	9	29	4.40	114	
R frontal lobe	Inferior frontal gyrus, ba 47	40	23	-8	4.21		
R frontal lobe	Inferior frontal gyrus, ba 44 broca's homologue	55	12	14	3.64		
R frontal lobe	Precentral gyrus, ba 6	44	1	29	4.12		
R frontal lobe	Middle frontal gyrus, ba 6	44	2	44	3.87		
R sub-lobar	Insula, ba 13 (anterior)	44	12	12	3.58		
R sub-lobar	Insula, ba 13 (anterior)	36	16	7	3.40		
L frontal lobe	Medial frontal gyrus, ba 6	0	3	59	4.78		96
L frontal lobe	Superior frontal gyrus, ba 8	0	26	50	4.05		
L sub-lobar	Clastrum, ba 14	-28	23	-1	4.01		
L sub-lobar	Insula, ba 13	-36	4	0	3.83		10
L frontal lobe	Middle frontal gyrus, ba 6	-36	-1	55	3.76		13
R frontal lobe	Middle frontal gyrus, ba 46 DLPFC	44	32	21	3.76		11
L parietal lobe	Inferior parietal lobule, ba 40, SMG	-48	-33	42	3.66		9
R cerebellum	Posterior lobe, declive	28	-63	-20	3.56	9	

**Fig. 4** No correlation between language lateralization (y axis) and lateralization of activity during auditory verbal hallucinations.

activated in a block design, which yields robust activation. The number and duration of AVH during the functional scans differed between patients, which lead to more variable and less extended activation. In order to correct for this difference in power, a conjunction analysis was applied rather than a direct subtraction to compare the activation patterns of both paradigms (Price and Friston, 1997; Price *et al.*, 1999). This analysis showed that several cortical language areas were activated during both conditions, including right and left frontal areas, the anterior part of the right insula and the left inferior parietal lobule.

The difference between activity during AVH and that during normal language production indicates that

**Fig. 5** Correlation between the lateralization index of hallucinatory activation and the degree to which the emotional content of AVH is negative, as scored on item 6 of the PSYRATS.

hallucinations mainly activate the *right* homologues of the language areas, especially the insula and the homologue of Broca's area, while normal language production predominantly activates frontal and temporal language areas in the *left* hemisphere. Lateralization of hallucinatory activity showed large inter-individual differences, ranging from strongly left lateralized, through bilateral to strongly right lateralized. Since there was a large inter-individual variability in the lateralization of activity during AVH, we explored possible correlations between lateralization of hallucinatory activity and individual characteristics, such as language lateralization and emotional content of the AVH.

It appeared not to be correlated with language lateralization, but rather with the degree to which the content of the AVH had a negative emotional valence.

This is not the first study to describe reversed lateralization of cerebral activity during AVH as compared to normal language activity. In an early case report, Woodruff *et al.* (1995) noted that AVH mainly activates the right language areas, while speech activates the left. Copolov *et al.* (2003) also reported hallucinatory activation in the right hemisphere homologue of Broca's region, but not in Broca's region. Most other studies, however, emphasized the role of Broca's area during hallucinations (McGuire *et al.*, 1995, 1997; Shergill *et al.*, 2000, 2001, 2003). Our study does not confirm activity in Broca's area during AVH, although it may have been present in some individuals. In addition to hallucination-related activity in language areas, both Shergill *et al.* (2000) and Copolov *et al.* (2003) reported activation in the left (para) hippocampal area. Even when we lowered the statistical threshold for detection to a more liberal value (i.e.  $P < 0.001$  uncorrected for multiple comparisons), no (para) hippocampal activity in either hemisphere could be observed. The absence of hallucinatory activity in the (para) hippocampal gyri is consistent with the results of Hoffman *et al.* (2007) who found hallucinatory activation in several frontal, temporal and temporo-parietal areas of both hemispheres, but detected no (para) hippocampal activation. Previous reports on activation in Broca's area during hallucinations have led to the conclusion that AVH arise from language produced in the usual speech production area, which is not recognized as such, but 'mis-attributed' to an external source as a result of inadequate self-monitoring (McGuire *et al.*, 1993; David 2004; Seal *et al.*, 2004; Shergill *et al.*, 2004; Allen *et al.*, 2008). It remains unclear, however, why some language fragments become misattributed, giving rise to AVH, while other internally generated speech (i.e. verbal thoughts) is processed normally. Our analyses offer an alternative explanation, as they show that cerebral activity arising from the right inferior frontal area is associated with AVH, while covert speech as produced in a word generation task originates from the usual speech production area (i.e. Broca's area). Activation of predominantly the right inferior frontal area during hallucinations may be related to the typical content of AVH.

In most right-handed subjects, the right hemisphere is inferior to the left in language production (Straus and Wada, 1983; Knecht *et al.*, 2000). When the left hemisphere is dysfunctional, as in aphasia patients, the right hemisphere is usually capable of producing a few short phrases of low linguistic complexity (Straus and Wada, 1983; Winhuizen *et al.*, 2005) such as swearwords or terms of abuse, typically with a negative emotional content (van Lancker and Cummings, 1999). In general, AVH in psychotic patients also consists of single words or truncated sentences (Stephane *et al.*, 2003) and have a predominantly negative

emotional content (Copolov *et al.*, 2004), suggesting that they may indeed be the product of right hemisphere language areas. Neuroimaging investigations revealed that emotional valence effects are strongly right lateralized in studies using compact blocked presentation of emotional stimuli (Kotz *et al.*, 2006).

### Limitations

Although this study clearly points to activity of the right inferior frontal area during AVH, there are some difficulties in interpreting the provided data. A first problem is that non-specific acoustic activation due to scanner sounds may have dampened activity in the primary auditory cortex during AVH. Another limitation is that the cerebral activation pattern observed during the hallucination paradigm consists of activity related to AVH *and* motor activity, because participants indicated the presence of voices by squeezing a balloon. However, motor activity from squeezing with the right hand is mainly to be expected in the motor cortex and SMA of the contralateral hemisphere and in the right cerebellum (Cramer *et al.*, 2002), while our main finding was that AVH activate the right inferior frontal area, which would be a very unusual area to result from ipsilateral motor activity.

In summary, the group-wise analyses showed that AVH predominantly engage the right inferior frontal area, including the right insula and the right homologue of Broca's area, while normal language production does activate Broca's area. The association between AVH and activity in right hemisphere language areas could explain the low linguistic complexity and derogatory content, characteristic for AVH in psychotic patients.

### References

- Andreasen NC, Flaum M, Arndt S. The comprehensive assessment of symptoms and history (CASH): an instrument for assessing psychopathology and diagnosis. *Arch Gen Psychiatry* 1992; 49: 615–23.
- Benjamini & Hochberg Controlling the False Discovery Rate. A Practical and Powerful Approach to Multiple Testing. *J R Statist Soc B (Methodol)*, 1995; 57: 289–300.
- Cramer SC, Weisskoff RM, Schaechter JD, Nelles G, Foley M, Finklestein SP, et al. Motor cortex activation is related to force of squeezing. *Hum Brain Mapp* 2002; 16: 197–205.
- Copolov DL, Seal ML, Maruff P, Ulusoy R, Wong MT, Tochon-Danguy HJ, et al. Cortical activation associated with the experience of auditory hallucinations and perception of human speech in schizophrenia: a PET correlation study. *Psychiatry Res* 2003; 122: 139–52.
- Copolov D, Trauer T, Mackinnon A. On the non-significance of internal versus external auditory hallucinations. *Schizophr Res* 2004; 69: 1–6.
- Desmond JE, Glover GH. Estimating sample size in functional MRI (fMRI) neuroimaging studies: statistical power analyses. *J Neurosci Methods* 2002; 118: 115–28.
- Dierks T, Linden DE, Jandl M, Formisano E, Goebel R, Lanfermann H, et al. Activation of Heschl's gyrus during auditory hallucinations. *Neuron* 1999; 22: 615–21.
- Haddock G, McCarron J, Tarrier N, Faragher EB. Scales to measure dimensions of hallucinations and delusions: the psychotic symptom rating scales (PSYRATS). *Psychol Med* 1999; 29: 879–89.



- Hoffman RE, Hampson M, Wu K, Anderson AW, Gore JC, Buchanan RJ, et al. Probing the pathophysiology of auditory/verbal hallucinations by combining functional magnetic resonance imaging and transcranial magnetic stimulation. *Cereb Cortex* 2007; 7: 2733–43.
- Jansen A, Menke R, Sommer J, Förster AF, Bruchmann S, Hempleman J, et al. The assessment of hemispheric lateralization in functional MRI-Robustness and reproducibility. *Neuroimage* 2006; 22: 204–17.
- Kay S, Fiszbein A, Opler L. The positive and negative syndrome scale (PANSS) for schizophrenia. *Schizophrenia Bull* 1987; 13: 261–76.
- Knecht S, Dräger B, Deppe M, Bobe L, Lohmann H, Flöel A, Ringelstein EB, Henningsen H. Handedness and hemispheric language dominance in healthy humans. *Brain* 2000; 123: 2512–18.
- van Lancker D, Cummings JL. Expletives: neurolinguistic and neurobehavioral perspectives on swearing. *Brain Res Brain Res Rev* 1999; 31: 83–104.
- Lennox BR, Park SB, Jones PB, Morris PG. Spatial and temporal mapping of neural activity associated with auditory hallucinations. *Lancet* 1999; 353: 644.
- Lennox BR, Park S, Medley I, et al. The functional anatomy of auditory hallucinations in schizophrenia. *Psychiat Res Neuroimag* 2000; 100: 13–20.
- McGuire PK, Shah GM, Murray RM. Increased blood flow in Broca's area during auditory hallucinations in schizophrenia. *Lancet* 1993; 342: 703–6.
- Mollet GA, Harrison DW, Walters RP, Foster PS. Asymmetry in the emotional content of lateralised multimodal hallucinations following right thalamic stroke. *Cognit Neuropsychiatry* 2007; 12: 422–36.
- Neggens SF, Hermans EJ, Ramsey NF. Enhanced sensitivity with fast three-dimensional blood-oxygen-level-dependent functional MRI: comparison of SENSE-PRESTO and 2D-EPI at 3 T. *NMR Biomed* 2008; 21: 663–76.
- Oldfield RC. The assessment and analysis of handedness: the Edinburgh inventory. *Neuropsychologia* 1971; 9: 97–113.
- Paus T, Perry DW, Zatorre RJ, Worsley KJ, Evans AC. Modulation of cerebral blood flow in the human auditory cortex during speech: role of motor-to-sensory discharges. *Eur J Neurosci* 1996; 8: 2236–46.
- Pruessmann KP, Weiger M, Scheidegger MB, Boesiger P. SENSE: sensitivity encoding for fast MRI. *Magn Reson Med* 1999; 42: 952–62.
- Sartorius N, Jablensky A, Korten A, Ernberg G, Anker M, Cooper JE, et al. Early manifestations and first-contact incidence of schizophrenia in different cultures. A preliminary report on the initial evaluation phase of the WHO Collaborative Study on determinants of outcome of severe mental disorders. *Psychol Med* 1986; 16: 909–28.
- Shergill SS, Brammer MJ, Fukuda R, Bullmore E, Amaro E Jr, Murray RM, et al. Mapping auditory hallucinations in schizophrenia using functional magnetic resonance imaging. *Arch Gen Psychiatry* 2000; 57: 1033–8.
- Shergill SS, Brammer MJ, Amaro E Jr, Williams SC, Murray RM, McGuire PK. Temporal course of auditory hallucinations. *Br J Psychiatry* 2004; 185: 516–17.
- Shergill SS, Brammer MJ, Fukuda R, Williams SC, Murray RM, McGuire PK. Engagement of brain areas implicated in processing inner speech in people with auditory hallucinations. *Br J Psychiatry* 2003; 182: 525–31.
- Shergill SS, Cameron LA, Brammer MJ, Williams SC, Murray RM, McGuire PK. Modality specific neural correlates of auditory and somatic hallucinations. *J Neurol Neurosurg Psychiatry* 2001; 71: 688–90.
- Shergill SS, Murray RM, McGuire PK. Auditory hallucinations: a review of psychological treatments. *Schizophr Res* 1998; 32: 137–50.
- Silbersweig DA, Stern E, Frith C, Cahill C, Holmes A, Grootoonk S, et al. A functional neuroanatomy of hallucinations in schizophrenia. *Nature* 1995; 378: 176–9.
- Smith B, Fowler DG, Freeman D, Bebbington P, Bashforth H, Garety P, et al. Emotion and psychosis: links between depression, self-esteem, negative schematic beliefs and delusions and hallucinations. *Schizophr Res* 2006; 86: 181–8.
- Sommer IE, Slotema CW, de Weijer AD, Blom JD, Daalman K, Neggens SF, et al. Can fMRI-guidance improve the efficacy of rTMS treatment for auditory verbal hallucinations? *Schizophr Res* 2007; 93: 406–8.
- Springer J, Binder J, Hammeke T, Swanson S, Frost J, Bellgowan P, et al. Language dominance in neurologically normal and epilepsy subjects: a functional MRI study. *Brain* 1999; 122: 2033–46.
- Strauss E, Wada J. Lateral preferences and cerebral speech dominance. *Cortex* 1983; 19: 165–77.
- Thirion B, Pinel P, Mériaux S, Roche A, Dehaene S, Poline JB. Analysis of a large fMRI cohort: Statistical and methodological issues for group analyses. *Neuroimage* 2007; 35: 105–20.
- Tzourio-Mazoyer N, Landeau B, Papathanassiou D, Crivello F, Etard O, Delcroix N, et al. Automated anatomical labeling of activations in SPM using a macroscopic anatomical parcellation of the MNI MRI single-subject brain. *Neuroimage* 2002; 15: 273–89.
- Winhuisen L, Thiel A, Schumacher B, Kessler J, Rudolf J, Haupt WF, et al. Role of the contralateral inferior frontal gyrus in recovery of language function in poststroke aphasia: a combined repetitive transcranial magnetic stimulation and positron emission tomography study. *Stroke* 2005; 36: 1759–63.
- Woodruff P, Brammer M, Mellers J, Wright I, Bullmore E, Williams S. Auditory hallucinations and perception of external speech. *Lancet* 1995; 346: 1035.
- Woodruff PW, Wright IC, Bullmore ET, Brammer M, Howard RJ, Williams SC, et al. Auditory hallucinations and the temporal cortical response to speech in schizophrenia: a functional magnetic resonance imaging study. *Am J Psychiatry* 1997; 154: 1676–82.
- Worsley KJ, Friston KJ. Analysis of fMRI time-series revisited – again. *Neuroimage* 1995; 2: 173–81.
- de Zwart JA, van Gelderen P, Golay X, Ikonomidou VN, Duyn JH. Accelerated parallel imaging for functional imaging of the human brain. *NMR Biomed* 2006; 19: 342–51.