

# Distinct structural changes underpin clinical phenotypes in patients with Gilles de la Tourette syndrome

Yulia Worbe,<sup>1,2</sup> Emilie Gerardin,<sup>2</sup> Andreas Hartmann,<sup>1,2,3</sup> Romain Valabrégue,<sup>2,4</sup> Marie Chupin,<sup>2</sup> Léon Tremblay,<sup>5</sup> Marie Vidailhet,<sup>2</sup> Olivier Colliot<sup>2</sup> and Stéphane Lehéricy<sup>2,4</sup>

- 1 Centre d'Investigation Clinique INSERM CIC 9503, Fédération des Maladies du Système Nerveux, Groupe Hospitalier Pitié-Salpêtrière, Assistance Publique – Hôpitaux de Paris, Paris, France
- 2 UPMC Université Paris 6, Centre de Recherche de l'Institut du Cerveau et de la Moelle épinière (CRICM), CNRS UMR 7225, Inserm UMR\_S 975, Paris, F-75013, France
- 3 Centre de Référence 'Syndrome Gilles de la Tourette', Fédération des Maladies du Système Nerveux, Groupe Hospitalier Pitié-Salpêtrière, Assistance Publique-Hôpitaux de Paris, Paris, France
- 4 Centre for Neuroimaging Research – CENIR, Groupe Hospitalier Pitié-Salpêtrière, Paris, France
- 5 Centre de Neurosciences Cognitives – UMR 5229, CNRS-Université de Lyon 1, Bron, F-69675, France

Correspondence to: Yulia Worbe,  
Centre de Recherche de l'Institut du Cerveau et de la Moelle épinière (CRICM),  
Hôpital Pitié-Salpêtrière,  
47 – 91 boulevard de l'Hôpital,  
Paris, F-75013, France  
E-mail: yulia.worbe@upmc.fr

Gilles de la Tourette syndrome is a childhood-onset neurodevelopmental disorder characterized by tics that are often associated with psychiatric co-morbidities. The clinical heterogeneity of Gilles de la Tourette syndrome has been attributed to the disturbance of functionally distinct cortico-striato-thalamo-cortical circuits, but this remains to be demonstrated. The aim of this study was to determine the structural correlates of the diversity of symptoms observed in Gilles de la Tourette syndrome. We examined 60 adult patients and 30 age- and gender-matched control subjects using cortical thickness measurement and 3T high-resolution T<sub>1</sub>-weighted images. Patients were divided into three clinical subgroups: (i) simple tics; (ii) simple and complex tics and (iii) tics with associated obsessive-compulsive disorders. Patients with Gilles de la Tourette syndrome had reduced cortical thickness in motor, premotor, prefrontal and lateral orbito-frontal cortical areas. The severity of tics was assessed using the Yale Global Tic Severity Scale and correlated negatively with cortical thinning in these regions, as well as in parietal and temporal cortices. The pattern of cortical thinning differed among the clinical subgroups of patients. In patients with simple tics, cortical thinning was mostly found in primary motor regions. In patients with simple and complex tics, thinning extended into larger premotor, prefrontal and parietal regions. In patients with associated obsessive-compulsive disorders, there was a trend for reduced cortical thickness in the anterior cingulate cortex and hippocampal morphology was altered. In this clinical subgroup, scores on the Yale-Brown Obsessive-Compulsive Scale correlated negatively with cortical thickness in the anterior cingulate cortex and positively in medial premotor regions. These data support the hypothesis that different symptom dimensions in Gilles de la Tourette syndrome are associated with dysfunction of distinct cortical areas and have clear implications for the current neuroanatomical model of this syndrome.

**Keywords:** cortical thickness; Gilles de la Tourette syndrome; obsessive–compulsive disorder; simple and complex tics; 3 Tesla MRI

**Abbreviations:** BA = Brodmann area; Y-BOCS = Yale–Brown Obsessive–Compulsive Scale; YGTSS = Yale Global Tic Severity Scale

## Introduction

Gilles de la Tourette syndrome is a childhood-onset disorder characterized by the presence of multiple motor tics and at least one vocal tic for > 1 year (American Psychiatric Association, 2000). The expression of tics range from brief, recurrent and non-rhythmic motor or vocal actions (simple tics) to complex motor or vocal sequences (complex tics), such as touching behaviour or repetitive word pronunciation (Jankovic and Fahn, 1986). The tics are often associated with psychiatric disorders such as obsessive–compulsive disorders, attention-deficit hyperactivity disorders and depression (Robertson *et al.*, 2000). Therefore, the phenotypic expression of Gilles de la Tourette syndrome is varied ranging from simple tics to a more complex association of tics and psychiatric co-morbidities. The pathophysiological origin of the clinical heterogeneity of Gilles de la Tourette syndrome is not yet fully understood. Inferences from various approaches support the hypothesis that Gilles de la Tourette syndrome is a neurodevelopmental disorder associated with dysfunction of cortico-striato-thalamo-cortical loops (Mink, 2003; Singer *et al.*, 2005). Cortical projections to the basal ganglia are functionally and topographically organized, leading to the concept of functional divisions of cortico-striato-thalamo-cortical loops into sensorimotor, associative and limbic circuits that are implicated in motor, cognitive and motivational aspects of behaviour, respectively (Alexander *et al.*, 1986).

According to this model of basal ganglia organization, it was suggested that motor tics may result from the dysfunction of premotor and motor circuits, whereas behavioural disorders may result from the dysfunction of associative and limbic circuits (Singer *et al.*, 2005). This hypothesis is supported by several lines of evidence. In primate models, experiments showed that dysfunction of the premotor and sensorimotor circuits produced abnormal movements resembling simple motor tics (McCairn *et al.*, 2009; Worbe *et al.*, 2009), whereas dysfunction of the associative and limbic circuits resulted in behavioural disorders resembling complex tics and compulsions, respectively (Grabli *et al.*, 2004; Worbe *et al.*, 2009).

In patients with Gilles de la Tourette syndrome, studies have reported dysfunction of cortico-striato-thalamo-cortical circuits at different levels (Supplementary Table 1 summarizes the main results to date on structural and diffusion changes in Gilles de la Tourette syndrome). Dysfunction of paralimbic and sensory association areas were implicated in tic generation using functional MRI (Bohlhalter *et al.*, 2006). In the cortex, structural changes were observed in frontal, anterior cingulate, insular, parietal and temporal regions, using voxel-based techniques (Müller-Vahl *et al.*, 2009), region of interest (Peterson *et al.*, 2001) and cortical thickness measurements (Sowell *et al.*, 2008; Fahim *et al.*, 2010). Structural changes were also reported in the striatum and globus pallidus (Peterson *et al.*, 2003), the cerebellum (Tobe *et al.*, 2010) using region of interest measurements, in

the striatum (Ludolph *et al.*, 2006) and the mid-brain (Garraux *et al.*, 2006) using voxel-based techniques, as well as in the thalamus using diffusion imaging (Makki *et al.*, 2008).

The severity of tics has been correlated with cortical thinning in the sensorimotor cortex and surrounding frontal and parietal areas (Sowell *et al.*, 2008; Fahim *et al.*, 2010), grey matter increase in the ventral putamen using voxel-based techniques (Ludolph *et al.*, 2006) and diffusion orientation in the thalamus (Makki *et al.*, 2008).

In contrast, the presence of psychiatric co-morbidities, such as obsessive–compulsive disorders and attention deficit hyperactivity disorder, correlated with volume reduction in the anterior caudate nucleus (Peterson *et al.*, 2003; Bloch *et al.*, 2005) and volume increase in the amygdala (Peterson *et al.*, 2007). Interestingly, volume of the hippocampus correlated both with severity of tics (Ludolph *et al.*, 2006) and the presence of obsessive–compulsive disorders and attention deficit hyperactivity disorder (Peterson *et al.*, 2007).

Overall, if results of previous studies provide support to the hypothesis that functionally distinct neuronal circuits are involved in tics and associated psychiatric co-morbidities, none of these studies directly addressed this question in clinical subgroups of patients. The purpose of this study was to determine the structural correlates of the diversity of symptoms observed in Gilles de la Tourette syndrome. We measured cortical thickness in clinical subgroups of adult patients with Gilles de la Tourette syndrome with simple tics, simple and complex tics and associated obsessive–compulsive disorders. We also examined structural changes in the hippocampus and their relationships with tics and obsessive–compulsive disorders.

## Materials and methods

### Subjects

Sixty adult patients with Gilles de la Tourette syndrome (mean age  $\pm$  SD: 30.3  $\pm$  10.8 years, 19 females) were enrolled in this study (Table 1). The inclusion criteria for the study were age > 18 years and confirmed diagnosis of Gilles de la Tourette syndrome. The exclusion criteria were age < 18 years, the presence of psychiatric disorders of Axe I established by the Mini International Neuropsychiatric Interview (French version) (Sheehan *et al.*, 1998) including associated major depression, previous and actual history of psychosis, autistic spectrum disorders, substance abuse excluding tobacco, presence of other neurological or movement disorders except tics, contraindication to MRI examination and absence of informed consent.

Patients were selected from the 150 consecutive adult patients with Gilles de la Tourette syndrome from the database of the reference centre for Gilles de la Tourette syndrome in Paris on the basis of their medical history. Only 90 out of the 150 patients fulfilled the inclusion criteria. These subjects were contacted by the referent neurologists (Y.W. and A.H.) for diagnosis confirmation, medication status assessment and multidisciplinary consultation including neurological,

**Table 1 Clinical characteristics and medication of Gilles de la Tourette syndrome patients**

	Simple tics group	Complex tics group	With associated obsessive–compulsive disorders group
Number of patients	21	22	17
Males	14	16	12
Females	7	8	4
Age (years)	29 ± 10	30 ± 13	32 ± 9
Age at onset (years)	6.3 ± 1.0	7.3 ± 2.1	6.5 ± 1.3
Mean syndrome duration (years)	23.0 ± 9.5	23.0 ± 12.7	25.5 ± 8.7
Premonitory urges (percentage of patients)	28.6	31.2	12.0
YGTSS/50	14.1 ± 6.4	21.4 ± 6.8	15.9 ± 5.9
YGTSS sub-scores			
Number of tics	2.9 ± 1.0	4.0 ± 1.3	2.9 ± 0.8
Frequency of tics	3.9 ± 1.5	4.8 ± 1.6	4.0 ± 1.6
Complexity of tics	0.6 ± 1.1	4.0 ± 2.0	1.9 ± 1.6
Interference of tics	2.9 ± 1.0	3.8 ± 1.7	2.8 ± 1.4
Intensity of tics	3.8 ± 1.9	4.7 ± 1.7	4.2 ± 1.7
Y-BOCS/40	1.8 ± 0.5	1.7 ± 0.8	12.8 ± 6.0
Treatment (percentage of patients)			
Non-treated	66.7	30.4	43.8
Neuroleptics	23.8	56.5	43.8
Benzodiazepines	9.5	4.3	12.5
Anti-depressants	4.8	13.0	25.0

Results are presented as mean ± SD.

neuropsychological and psychiatric evaluation. From these 90 patients, 16 were not included in the protocol for the following reasons: (i) refusal to participate in the study; (ii) contraindication to MRI and (iii) the clinical course of Gilles de la Tourette syndrome was changed (i.e. symptoms too severe to perform MRI, presence of exclusion criteria). Nine additional patients with actual history of attention deficit hyperactivity disorder were not included because their number was not sufficient to constitute a homogeneous group. Lastly, from the 65 patients who were included, five did not complete the MRI protocol for various reasons (claustrophobia, motion) and their data were excluded from the final analysis.

Severity of tics was assessed using the Yale Global Tic Severity Scale (YGTSS) (Leckman *et al.*, 1989). The presence and severity of associated obsessive–compulsive disorders was evaluated during the psychiatric consultation using the Yale–Brown Obsessive–Compulsive Scale (Y-BOCS) assessment (Goodman *et al.*, 1989). The diagnosis of attention deficit hyperactivity disorder was established on the basis of Diagnostic and Statistical Manual-IV criteria of attention deficit hyperactivity disorder (American Psychiatric Association, 2000). In line with the purpose of the study, patients with Gilles de la Tourette syndrome were divided into three distinct clinical subgroups based on the clinical expression of their symptoms: (i) patients with only simple motor and vocal tics (YGTSS complexity score of motor and vocal tics ≤ 2); (ii) patients with simple and complex motor and vocal tics (YGTSS complexity score of motor and vocal tics ≥ 2) and (iii) patients with associated obsessive–compulsive disorders; these patients also presented simple and complex motor tics. Six patients with Gilles de la Tourette syndrome presented obsessive–compulsive symptoms that did not fulfil the Diagnostic and Statistical Manual-IV-Text Revision criteria for obsessive–compulsive disorders, had no previous history of obsessive–compulsive disorders and were not previously treated for obsessive–compulsive disorders. These patients were included in the simple tics ( $n=2$ ) and complex tics ( $n=4$ ) groups.

Patients were compared with 30 age- and sex-matched healthy volunteers (29.1 ± 11 years, 11 females). The inclusion criteria for the study were age > 18 years and no history of neurological or psychiatric disorders. The exclusion criteria were the same as for the patients and previous history of tics (childhood tics). Patients and healthy volunteers gave written informed consent and the study was approved by the local ethics committee.

## Magnetic resonance imaging acquisition

Images were acquired using a 3 T system (Siemens, TRIO 32 channel TIM system) with body coil excitation and 12-channel receive phased-array head coil. Anatomical scans were acquired using sagittal 3D T<sub>1</sub>-weighted magnetization prepared rapid acquisition gradient echo (inversion time: 900 ms, repetition time: 2300 ms, echo time: 4.18 ms, flip angle: 9°, partial Fourier 7/8, 1 average, voxel size: 1 × 1 × 1 mm<sup>3</sup>). All patients included in the study were asked to suppress their tics during image acquisition to avoid movement artefacts.

## Cortical thickness measurements

Cortical thickness measurements were performed with the FreeSurfer image analysis suite (Massachusetts General Hospital, Boston, MA, USA), which is documented and freely available for download online (<http://surfer.nmr.mgh.harvard.edu/>). The technical details of this procedure are described in previous publications (Dale *et al.*, 1999; Fischl *et al.*, 1999a, b). Briefly, the processing included motion correction and averaging of multiple volumetric T<sub>1</sub>-weighted images, removal of non-brain tissue using a hybrid watershed/surface deformation procedure, automated Talairach transformation, intensity normalization, tessellation of the grey matter–white matter boundary, automated topology correction and surface deformation following

intensity gradients to optimally place the grey matter–white matter and grey matter–cerebrospinal fluid borders at the location where the greatest shift in intensity defined the transition to the other tissue class. Cortical thickness was then calculated as the closest distance from the grey matter–white matter boundary to the grey matter–cerebrospinal fluid boundary at each vertex on the tessellated surface (Fischl and Dale, 2000). All cortical thickness maps were then registered onto the common template provided with FreeSurfer. As cortical thickness varies with gender and age (Sowell *et al.*, 2007), these variables were included as covariates in all statistical comparisons to exclude the effect of gender and age from the observed structural differences.

## Hippocampal morphometry

Hippocampal morphometry was performed on 57 patients with Gilles de la Tourette syndrome and 28 controls; 3 patients and 2 controls were excluded from the study due to abnormal hippocampal shape that may have altered the morphometry analyses (large hippocampal malrotation, Bernasconi *et al.*, 2005).

The hippocampi were segmented from the  $T_1$ -weighted images using the fully automatic method Segmentation Automatique Compétitive de l'Hippocampe et de l'Amygdale (Chupin *et al.*, 2009). This approach allowed the simultaneous segmentation of both the hippocampus and the amygdala based on competitive region growing. It included prior knowledge of the location of the hippocampus and the amygdala derived from a probabilistic atlas, and of the relative positions of these structures with respect to anatomical landmarks, which were automatically identified. This method has been validated by comparison with manual tracing in young healthy participants and patients with Alzheimer's disease and has proved to be reliable, fast and accurate (Chupin *et al.*, 2009).

To investigate the specific contribution of local changes within the hippocampus, we performed a statistical 3D surface-based shape analysis relying on the spherical harmonics approach (Styner *et al.*, 2004).

The analysis was performed using the SPHARM-PDM software developed by the University of North Carolina and the National Alliance for Medical Imaging Computing ([http://www.namc.org/Wiki/index.php/Algorithm:UNC:Shape\\_Analysis](http://www.namc.org/Wiki/index.php/Algorithm:UNC:Shape_Analysis)). SPHARM is a mathematical approach, representing surfaces with spherical topology, which can be seen as a 3D analogue of Fourier series expansion. It has been successfully used to analyse hippocampal shape differences in a variety of neurological and psychiatric conditions including Alzheimer's disease (Gerardin *et al.*, 2009), schizophrenia (Styner *et al.*, 2004) and bipolar disorder (Hwang *et al.*, 2006). In brief, the SPHARM approach took the following steps. First, hippocampal segmentations were converted to surface meshes and a spherical parameterization was computed, creating a one-to-one map between each point on the surface and each point on a sphere. The surface was expanded into a series of spherical harmonics. The coefficients of the series expansion were normalized in order to eliminate effects of rotation, translation and scale. The SPHARM representation was transformed into a triangulated surface (called the SPHARM-PDM), based on a uniform subdivision of the spherical parameterization. The SPHARM-PDM was finally spatially aligned using rigid Procrustes alignment, giving a one-to-one mapping between points of each hippocampus.

## Statistical analyses

Surface-based analyses of both cortical thickness and hippocampal shape were performed using Surfstat software (<http://www.math.mcgill.ca/keith/surfstat/>).

Cortical thickness maps were smoothed using a 20 mm surface-based kernel. The comparison of cortical thickness between groups was carried out using a univariate linear model at each vertex. For the comparison of hippocampal shape between groups, we used the Hotelling  $T^2$  metric to test for group differences in the spatial location ( $x, y, z$ ) at each vertex of the hippocampal surface (Styner *et al.*, 2006).

In all analyses, statistics were corrected for multiple comparisons using the random field theory for non-isotropic images (Worsley *et al.*, 1999). A statistical threshold of  $P < 0.005$  was first applied (height threshold). An extent threshold of  $P < 0.05$  corrected for multiple comparisons was then applied at the cluster level unless stated otherwise. Differences obtained using lower thresholds are reported as trends.

All clinical variables were compared using SigmaStat software and one way ANOVA statistics.

## Results

### Clinical subgroups of patients with Gilles de la Tourette syndrome

The clinical characteristics and medication of the patients are presented in Table 1.

The simple tics group was characterized by the presence of simple motor tics of the face (mostly eye blinks), neck and hands and simple vocal tics (throat noises). The mean  $\pm$  SD YGTSS complex tics score was  $0.6 \pm 1.1$ .

The complex tics group included patients with simple and complex motor and vocal tics—mostly complex motor tics of the hand, touching behaviour, echo-, copro- and pali-phenomena. The mean YGTSS complex tics score was  $4.0 \pm 2.0$ .

The GTS patients with associated obsessive–compulsive disorders group included patients with simple and complex tics and associated obsessive–compulsive disorders (checking and washing compulsions). The mean YGTSS complex tics score was  $1.9 \pm 1.6$ .

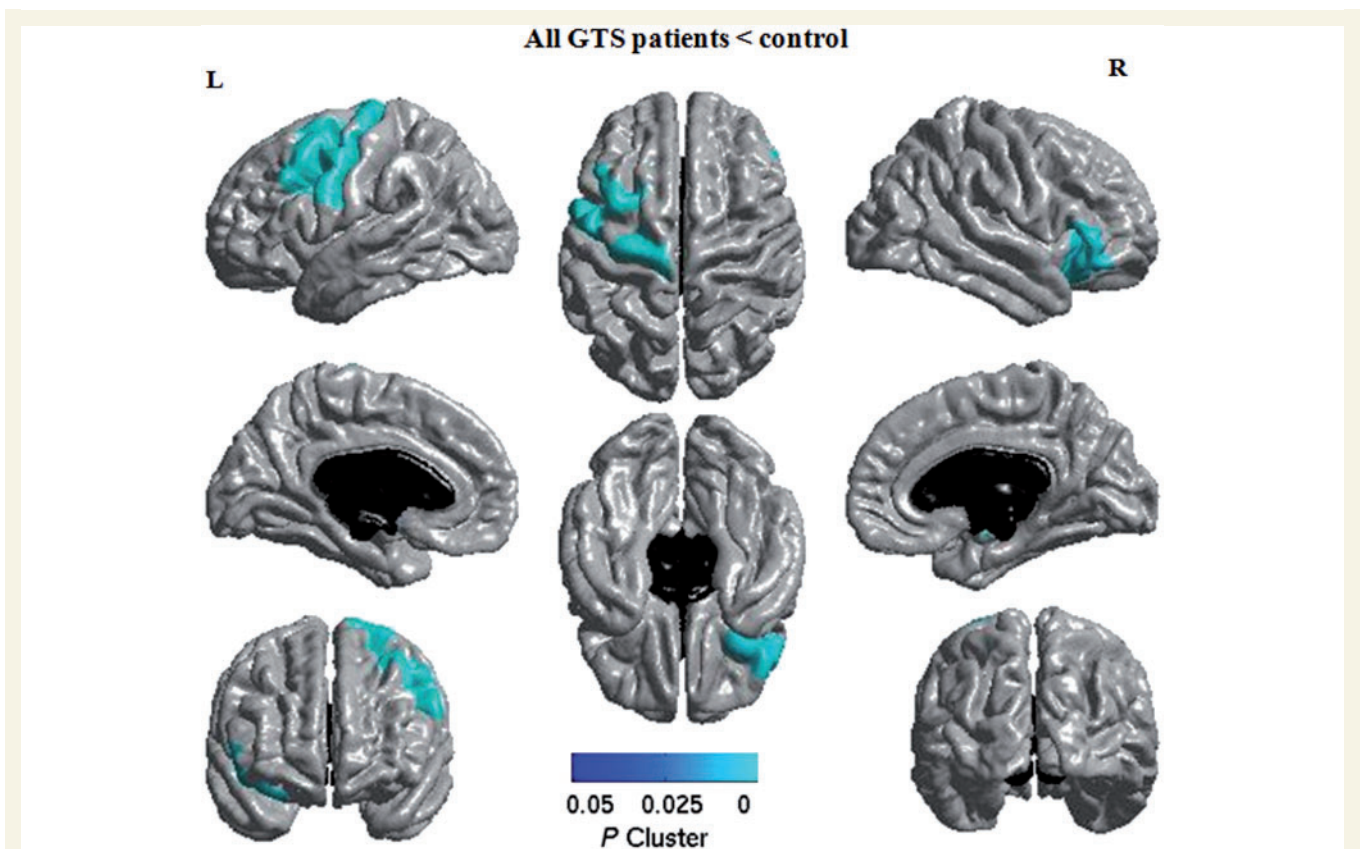
The complex tics group differed from the simple tics and obsessive–compulsive disorders groups by the presence of higher numbers of tics ( $P = 0.009$ ) and greater complexity YGTSS scores ( $P \leq 0.001$ ). There were no statistically significant differences between all three groups in frequency ( $P = 0.1$ ), intensity ( $P = 0.2$ ) and interference ( $P = 0.09$ ) YGTSS sub-scores.

The mean Y-BOCS score was significantly higher in the obsessive–compulsive disorders group (Y-BOCS score:  $12.8 \pm 6.0$ ,  $P \leq 0.001$ ) than in the other two groups (simple tics:  $1.8 \pm 0.5$ , complex tics:  $1.7 \pm 0.8$ ).

### Cortical thickness in all patients with Gilles de la Tourette syndrome

In all patients with Gilles de la Tourette syndrome compared with controls (Fig. 1), the cortical areas of diminished thickness included the motor cortex, the postero-lateral part of the superior frontal gyrus [corresponding to Brodmann area (BA) 6], the posterior part of the middle frontal gyrus (BA 6, 8 and 9) in the left hemisphere, and the inferior frontal gyrus (BA 45) and the lateral part of the orbito-frontal gyrus (BA 47) in the right hemisphere. Cortical





**Figure 1** Regions of cortical thinning in all patients with Gilles de la Tourette syndrome (GTS) compared with controls. Clusters are significant at  $P < 0.005$  corrected for multiple comparisons. L = left hemisphere; R = right hemisphere.

thickness changes in patients with Gilles de la Tourette syndrome were not modified by age (see online Supplementary data). There was no difference in cortical thickness between males and females with Gilles de la Tourette syndrome matched for age, YGTSS severity and disease duration (Supplementary data).

### Cortical thickness in clinical subgroups of patients with Gilles de la Tourette syndrome

Group comparison of cortical thickness showed distinct patterns of cortical alteration in the clinical subgroups of patients.

In the simple tics group compared with controls, there was diminished cortical thickness in the posterior part of the left middle frontal gyrus—premotor cortex (BA6) and the left motor cortex in the region of the representation of the upper and lower limbs and the upper part of the face area (Fig. 2A).

In the complex tics group compared with controls, the cortical areas of diminished thickness included the posterior parts of the middle and inferior frontal gyrus (corresponding to BA 6, 8, 9, 44 and 46), the ventral and lateral parts of the left motor cortex in the region of the face area and the corresponding part of the primary sensory cortex, the anterior and inferior parietal cortex (BA 39 and 40) in the left hemisphere, as well as the right inferior

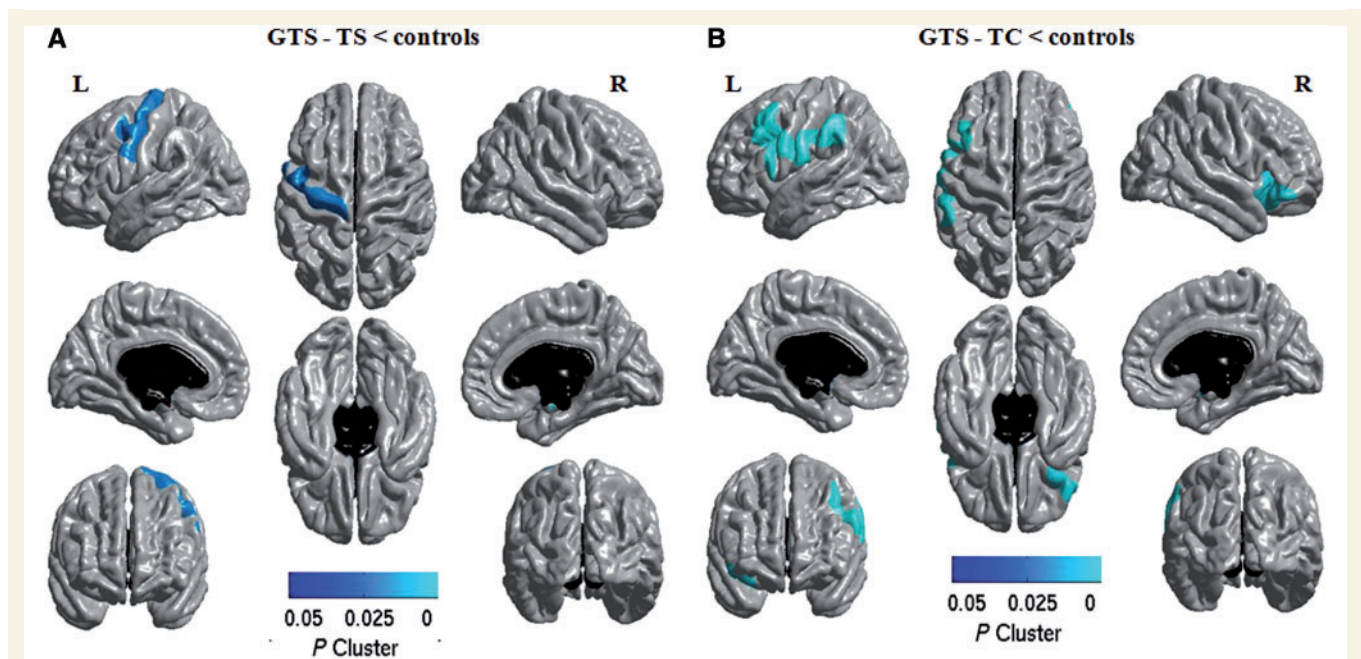
frontal gyrus (BA 45) and the lateral part of the right orbito-frontal gyrus (BA 47) (Fig. 2B).

Lastly, in Gilles de la Tourette patients with associated obsessive–compulsive disorders group (Fig. 3A), there were no significant differences at  $P < 0.005$  corrected for multiple comparisons. However, there was a trend for cortical thinning in the left ventral anterior cingulate cortex (BA 32) as well as in small areas of the left middle frontal gyrus (BA 8/9), the left motor cortex (BA 4) and the superior parietal lobule (BA 7), bilateral occipital lobes (BA 19/37) and posterior parts of right orbito-frontal gyrus (BA 47) ( $P < 0.005$  uncorrected for multiple comparisons).

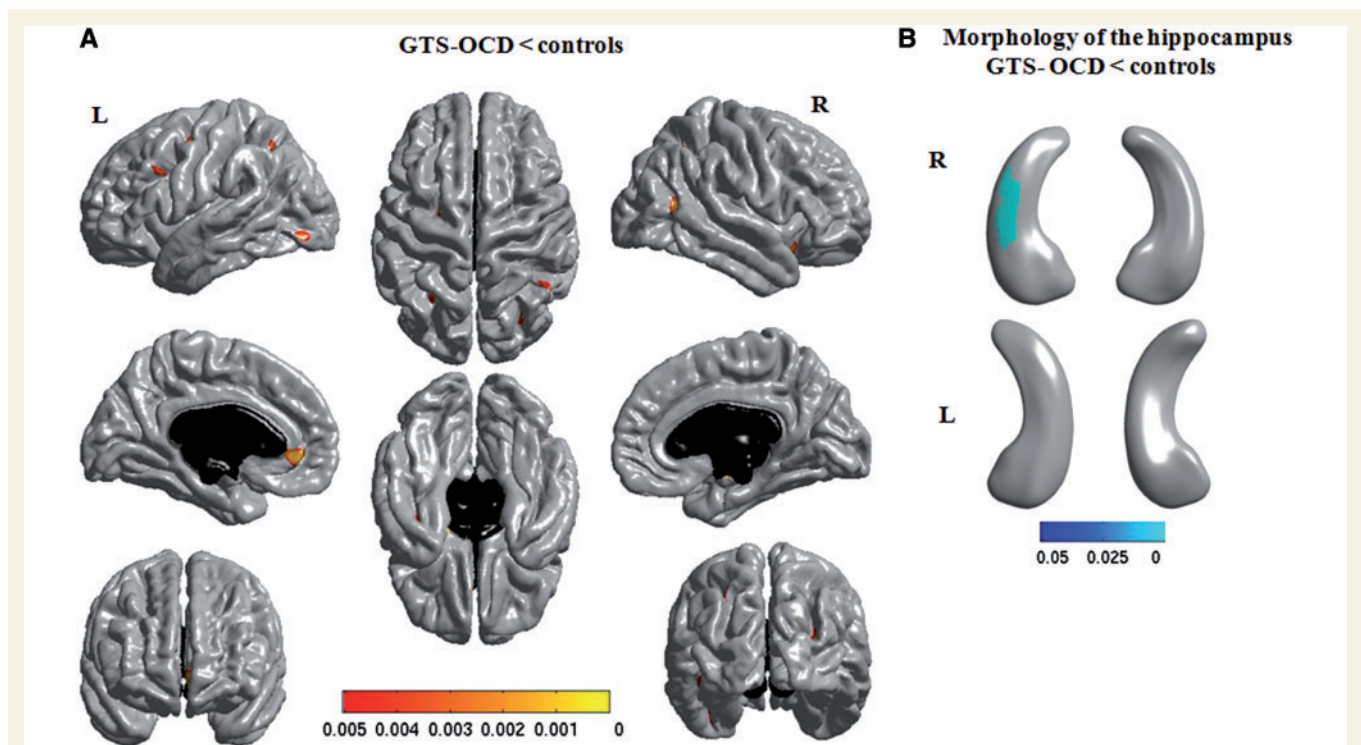
There were no regions of cortical thickening in any of the Gilles de la Tourette syndrome groups compared with controls.

### Hippocampal volumes and morphology in clinical subgroups of patients with Gilles de la Tourette syndrome

In all patients with Gilles de la Tourette syndrome compared with controls, there was a 3.0% reduction in hippocampal volume. The clinical subgroups analysis showed that this reduction was only significant in Gilles de la Tourette patients with associated obsessive–compulsive disorders group (3.5%,  $P = 0.03$ ), mostly in the right hippocampus (4.4%). The hippocampal volume was only slightly diminished in the other groups and the difference was



**Figure 2** Regions of cortical thinning in clinical subgroups of patients with Gilles de la Tourette syndrome compared with controls. (A) Patient with simple tics (GTS-TS). (B) Patients with Gilles de la Tourette syndrome with simple and complex tics (GTS-TC). Clusters are significant at  $P < 0.005$  corrected for multiple comparisons. L = left hemisphere; R = right hemisphere.



**Figure 3** Structural changes in patients with Gilles de la Tourette syndrome with associated obsessive-compulsive disorders (GTS-OCD) compared with controls. (A) Regions of cortical thinning in patients compared with controls,  $P < 0.005$  uncorrected for multiple comparisons. (B) Structural changes in the hippocampus in patients. *Left*: medial view; *Right*: lateral view of hippocampus. Clusters are significant at  $P < 0.005$  corrected for multiple comparisons. L = left hemisphere; R = right hemisphere.



not significant (simple tics: 2.9%, complex tics: 2.7%, both  $P$ -values=0.12).

The morphological analysis of the hippocampus showed significant changes in the obsessive–compulsive disorders group only. In this group, the morphology of the postero-lateral part of the right hippocampus differed significantly from the morphology of the healthy volunteers (Fig. 3B).

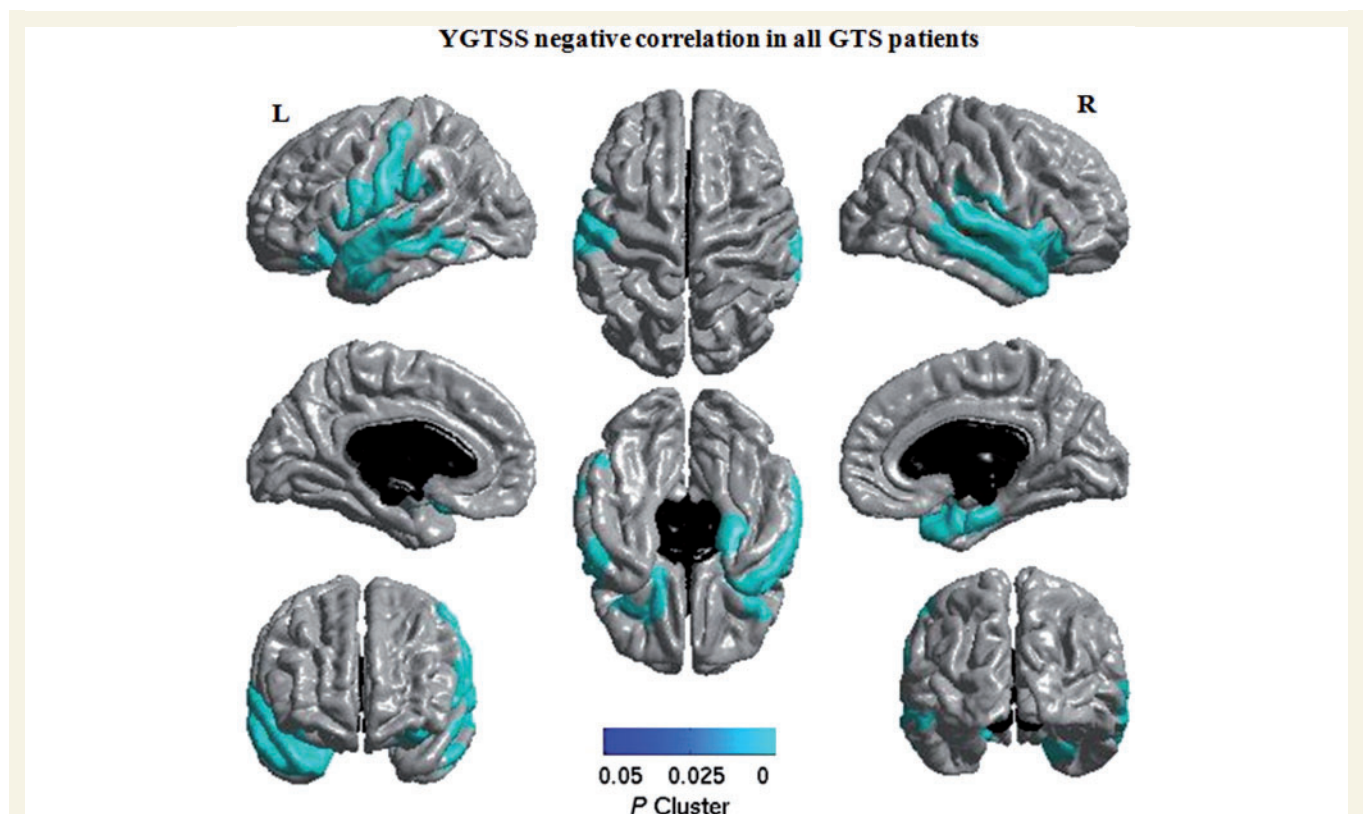
## Correlations between YGTSS and Y-BOCS scores and cortical thickness in patients with Gilles de la Tourette syndrome

The correlation between the YGTSS scores (YGTSS/50) and cortical thickness in patients with Gilles de la Tourette syndrome is presented in Fig. 4.

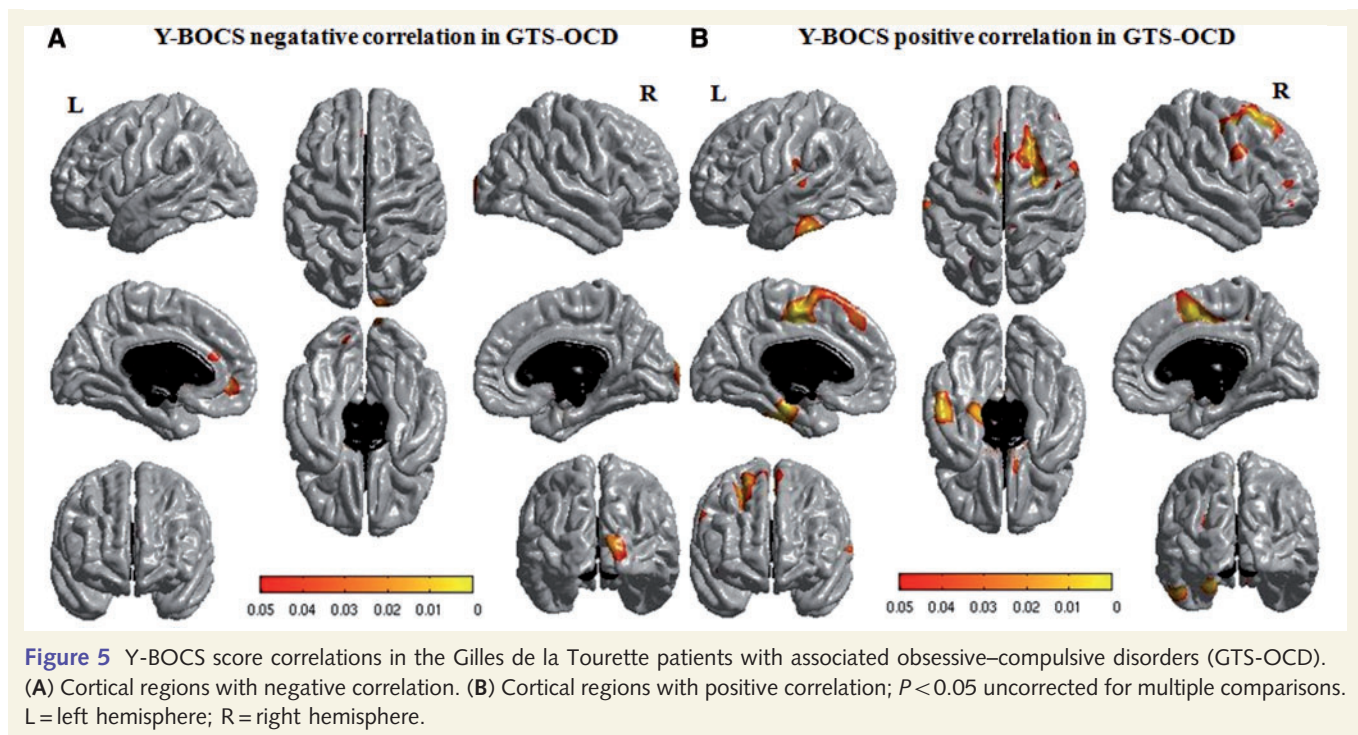
In all patients with Gilles de la Tourette syndrome, the YGTSS scores correlated negatively with cortical thickness in the posterior part of the medial orbital gyrus (BA 13), the posterior part of the inferior frontal gyrus (BA 44) and the ventral part of the primary sensorimotor cortex in the region of the face area and adjacent premotor cortex in the left hemisphere, the antero-medial temporal lobe (BA 34, 35 and 28) and the temporal pole (BA 38) in the right hemisphere, and bilaterally in lateral parts of the orbito-frontal and inferior frontal gyri (BA 47), the operculum,

the superior (BA 22, 41 and 42) and middle (BA 21) temporal gyri and inferior regions of the parietal lobe (BA 40). No regions showed a positive correlation with YGTSS.

There was no significant correlation between cortical thickness and Y-BOCS scores at the corrected threshold of  $P < 0.005$ . Given our hypothesis of a relation between obsessive–compulsive disorders and structural changes in limbic regions, we looked for correlations in the Gilles de la Tourette patients with associated obsessive–compulsive disorders group at a lower statistical threshold of  $P < 0.05$ . Using this threshold in this group, there was a negative correlation between increased Y-BOCS scores and reduced cortical thickness in the left dorsal and ventral anterior cingulate cortex (BA 32 and 24) and small areas of the occipital cortex (right BA 18 and left BA 19) ( $T$  score=2, Fig. 5A). There was also a positive correlation between increased Y-BOCS score and increased cortical thickness bilaterally in the medial part of the superior frontal gyrus including the supplementary motor area (BA 6), the antero-medial part of the superior frontal gyrus (BA 8 and 9), the inferior temporal gyrus (BA 21) and the medial temporo-occipital gyrus (BA 35 and 36) in the left hemisphere, and in posterior parts of the superior and middle frontal gyri (ventral parts of BA 6 and 8), the anterior parts of the middle frontal gyrus (BA 46), the posterior part of the gyrus rectus (BA 14) and the inferior part of the primary motor cortex, corresponding to the face area in the right hemisphere ( $T$  score = 2, Fig. 5B).



**Figure 4** Cortical regions negatively correlated with the YGTSS score in all patients with Gilles de la Tourette syndrome. Clusters are significant at  $P < 0.005$  corrected for multiple comparisons. L = left hemisphere; R = right hemisphere.



## Discussion

We provide evidence that the different phenotypic expressions in Gilles de la Tourette syndrome are due to dysfunction of different cortical areas. Simple tics were associated with cortical thinning in premotor and sensorimotor areas and complex tics with cortical thinning in larger premotor, prefrontal and parietal associative areas. The presence of obsessive–compulsive disorders was associated with altered hippocampal morphology and with cortical thinning of the anterior cingulate cortex. Severity of tics correlated negatively with cortical thinning in frontal, parietal and temporal regions, whereas the severity of obsessive–compulsive disorders correlated negatively with cortical thickness in the anterior cingulate area and positively in prefrontal regions.

### Cortical thickness in patients with Gilles de la Tourette syndrome compared with controls

Adult patients with Gilles de la Tourette syndrome presented important thinning in the left motor, premotor and dorso-lateral prefrontal regions and the right ventro-lateral and lateral orbito-frontal areas. Cortical thinning in all these regions has been reported in children (Sowell *et al.*, 2008) and young adults (Fahim *et al.*, 2010) with Gilles de la Tourette syndrome in previous studies. Using diffusion MRI, changes were also observed in the white matter of the sensorimotor regions and in fronto-striatal circuits in children (Makki *et al.*, 2009) and adults (Thomalla *et al.*, 2009) with Gilles de la Tourette syndrome. Taken together, these data pointed to a global dysfunction of grey and white matter

components of cortical projections to the striatum in Gilles de la Tourette syndrome.

Cortical changes clearly predominated in the left hemisphere. A similar predominance of cortical thinning in left motor regions has already been reported in young adults with Gilles de la Tourette syndrome (Fahim *et al.*, 2010) but not in children with Gilles de la Tourette syndrome (Sowell *et al.*, 2008). The left-sided predominance of structural changes in adults may be related to the asymmetry of cortical areas consequent to brain maturation as shown using structural imaging (Kloppel *et al.*, 2010), diffusion connectivity (Iturria-Medina *et al.*, 2010) or functional MRI (Woolley *et al.*, 2010). In contrast, regional volumetric (Peterson *et al.*, 2001) and voxel-based morphometry studies (Müller-Vahl *et al.*, 2009) did not report any asymmetry in adult patients with Gilles de la Tourette syndrome. Further studies are therefore needed to investigate the asymmetry of structural changes in Gilles de la Tourette syndrome.

### Different patterns of cortical thinning in clinical subgroups of patients with Gilles de la Tourette syndrome

Simple and complex tics differed in their phenomenological expression and are thought to represent biologically relevant symptom subclasses (Mathews *et al.*, 2007; Robertson *et al.*, 2008). In contrast to the basic motor patterns of simple tics, complex tics are characterized by complex sequential motor or vocal patterns such as touching behaviour, repetitive word pronunciation or motor action or vocal imitations (Jankovic and Fahn, 1986). Our data suggest that these clinical differences are underlain by different structural changes. The simple tics were



associated with structural changes in primary motor and adjacent premotor regions. In the simple tics group, cortical thinning was found in the primary motor area of the face and hand, which fits well with the orofacial and hand predominance of the tics. Cortical thinning in these regions was also observed in the two other groups who also presented simple tics, although thinning was less marked in the obsessive–compulsive disorders group.

The complex tics group was characterized by cortical thinning in larger frontal and parietal regions. Previous studies have shown that these regions were recruited during movements of increasing complexity (Catalan *et al.*, 1998; Lehericy *et al.*, 2006) as well as in the learning of new motor sequences (Lehericy *et al.*, 2005; Doyon *et al.*, 2009). The dysfunction of these regions may therefore be necessary for the production of complex tics. Thinning of the ventrolateral premotor and prefrontal regions (BA 44) was also specific to the complex tics group. These regions and the inferior parietal cortex are part of the mirror neuron system, which is implicated in movement imitation (Molenberghs *et al.*, 2009). Dysfunction of this network may therefore be associated with the imitation behaviour frequently observed in patients with complex tics.

Alternatively, the larger structural changes observed in the complex tics group may be related to the greater severity of the syndrome in this group. Indeed, the complex tics group had a greater tics score on the YGTSS than the two other groups. However, this was mostly due to the larger number of complex tics. This suggests that even if severity differed between the groups of patients, it was mainly driven by complexity of the tics in the complex tics group.

The association of tics with obsessive–compulsive disorders was characterized by reduced volume and altered morphology of the hippocampus, in agreement with previous volumetric (Peterson *et al.*, 2007) and voxel-based morphometry (Ludolph *et al.*, 2006) studies in children and adults with Gilles de la Tourette syndrome with associated obsessive–compulsive disorders, as well as in patients with obsessive–compulsive disorders without tics (Hong *et al.*, 2007; Atmaca *et al.*, 2008).

In the Gilles de la Tourette patients with associated obsessive–compulsive disorders, there was a trend for diminished cortical thickness in the ventral anterior cingulate cortex as well as in regions associated with tics in the other Gilles de la Tourette syndrome groups. The smaller number of patients included in this group may explain why differences were not detected using the corrected threshold. Reduced cortical thickness in the anterior cingulate cortex was specific to the Gilles de la Tourette patients with associated obsessive–compulsive disorders group and was not observed in the two other groups even using the uncorrected threshold. This finding was in line with the reduced volume of the anterior cingulate cortex showed in adolescent and adult patients with obsessive–compulsive disorders without tics (Radua and Mataix-Cols, 2009; Rotge *et al.*, 2010). In children with Gilles de la Tourette syndrome, positive correlation was also reported between obsessive–compulsive disorders and connectivity scores between the subcallosal gyrus and the lentiform nucleus using diffusion imaging (Makki *et al.*, 2009).

The anterior cingulate cortex and the hippocampus are functionally heterogeneous structures, which are part of the limbic system (Paus, 2001; Fanelow and Dong, 2010). The ventral

part of the anterior cingulate cortex is implicated in the assessment and regulation of emotional information and anxiety (Paus, 2001). The hippocampus is involved in the regulation of aversive emotional states (mostly fear and anxiety) as well as in emotionally driven memorization and conditioning (Fanelow and Dong, 2010). Consequently, both structures may mediate the expression of anxiety observed in obsessive–compulsive disorders.

## Cortical structural changes correlated with the YGTSS and the Y-BOCS

Severity of tics measured with the YGTSS correlated negatively with cortical thickness in all regions that were affected in the group comparison, in agreement with previous studies (Sowell *et al.*, 2008; Fahim *et al.*, 2010).

Severity of tics also correlated with cortical thickness in the temporal, ventro-lateral prefrontal and adjacent orbito-frontal cortices.

Positron emission tomography (Stern *et al.*, 2000) and functional MRI studies (Peterson *et al.*, 1998; Mazzone *et al.*, 2010) reported abnormal activity in temporal regions in patients with Gilles de la Tourette syndrome, suggesting that they are implicated in the control of tics. Similarly, surgical ablation of the temporal cortex in patients with Gilles de la Tourette syndrome with co-occurring epilepsy resulted in the exacerbation of tics (Chemali and Bromfield, 2003; Sinno *et al.*, 2006). In addition, functional MRI studies showed that the ventro-lateral prefrontal and the lateral orbital cortex are implicated in motor response inhibition and behavioural persistence (Gusnard *et al.*, 2003; Aron *et al.*, 2007). The dysfunction of these regions thus may contribute to the deficient motor control and tic persistence.

The severity of obsessive–compulsive disorders, measured using the Y-BOCS scale had a tendency to correlate negatively with thinning in the left ventral and dorsal anterior cingulate cortex. The left anterior cortex is functionally lateralized (Lütcke and Frahm, 2008) and plays an important role in error detection (Paus, 2001; Swick and Turken, 2002). The cognitive model (Salkovskis, 1985) and functional MRI studies (Fitzgerald *et al.*, 2005) indicate that altered error detection is one of the pathological mechanisms of obsessive–compulsive disorders. Accordingly, thinning of the dorsal anterior cingulate cortex fits well with more severe obsessive–compulsive disorder symptoms in patients with Gilles de la Tourette syndrome.

Less severe obsessive–compulsive disorder symptoms correlated with decreased thickness of medial premotor areas. Medial premotor areas (mostly the supplementary motor area) were involved in self performance evaluation, in the initiation and inhibitory control of actions and in cognition (Aron *et al.*, 2007; Passingham *et al.*, 2010). The fact that these regions correlate with less severe obsessive–compulsive disorder symptoms suggests that they contribute to the cognitive control of obsessive–compulsive disorders.

## Brain correlates of cortical thinning

The structural changes may be primary and caused by the underlying cause of the disease. Recent neuropathological studies in Gilles de la Tourette syndrome showed both decreased number and deviant distribution of basal ganglia inhibitory interneurons

(Kalanithi *et al.*, 2005; Kataoka *et al.*, 2010). As cortical and basal ganglia interneurons originate from the same structures during brain development (Wonders and Anderson, 2006), reduced number of inhibitory interneurons may also be present in the cortex, leading to both structural changes and functional abnormalities. This suggestion is in line with neurophysiological (Orth and Rothwell, 2009; Heise *et al.*, 2010) and functional MRI data (Bohlhalter *et al.*, 2006), which showed diminished intracortical inhibition and hyperactivity of premotor and sensorimotor cortex in Gilles de la Tourette syndrome. Therefore, thinning of cortical regions fits well with the developmental hypothesis of Gilles de la Tourette syndrome.

## Limitations

A limitation of this study was the inclusion of patients with different medications. The impact of neuroleptic medication on brain structural changes is controversial, as studies have reported either no impact (Peterson *et al.*, 2001) or changes in brain volume (Scherk and Falkai, 2006). The variation of cortical thickness was not influenced by neuroleptic medication in cross-sectional studies of patients with schizophrenia that typically used a higher dosage of neuroleptics (Kuperberg *et al.*, 2003; Narr *et al.*, 2005). Consequently, the different patterns of cortical changes in our study were most probably related to symptom expression and not to differences in medication. In addition, neuroleptics may influence tic measurement using the YGTSS and antidepressants may influence obsessive–compulsive disorder measurement using the Y-BOCS. Correlation data may thus be influenced by the medication status. Lastly, correlation data should be considered with caution as structural changes could reflect either the causes or the consequences of the symptoms.

## Conclusion

The present study shows that cortical areas are variably involved in Gilles de la Tourette syndrome, a finding that provides an explanation for the clinical heterogeneity of the disorder. Combined with experimental results obtained in the basal ganglia in primates (Grabli *et al.*, 2004; Worbe *et al.*, 2009), this suggests that dysfunction of specific cortical–basal ganglia circuits lead to the clinical heterogeneity of Gilles de la Tourette syndrome symptoms.

## Acknowledgements

We sincerely thank the nurses of the Centre of Clinical Investigation of Pitié-Salpêtrière Hospital and the staff of the Centre for Neuroimaging Research (CENIR) for their help in patient management and scanning.

## Funding

French National Research Agency (ANR-07-NEURO-023-01). L'Association Française du syndrome de Gilles de la Tourette and by Lilly Institute (to Y.W.).

## Supplementary material

Supplementary material is available at *Brain* online.

## References

- Alexander GE, DeLong MR, Strick PL. Parallel organization of functionally segregated circuits linking basal ganglia and cortex. *Annu Rev Neurosci* 1986; 9: 357–81.
- Aron AR, Durston S, Eagle DM, Logan GD, Stinear CM, Stuphorn V. Converging evidence for a fronto-basal-ganglia network for inhibitory control of action and cognition. *J Neurosci* 2007; 27: 11860–4.
- Atmaca M, Yildirim H, Ozdemir H, Ozler S, Kara B, Ozler Z, *et al.* Hippocampus and amygdalar volumes in patients with refractory obsessive-compulsive disorder. *Prog Neuropsychopharmacol Biol Psychiatry* 2008; 32: 1283–6.
- Bernasconi N, Kinay D, Andermann F, Antel S, Bernasconi A. Analysis of shape and positioning of the hippocampal formation: an MRI study in patients with partial epilepsy and healthy controls. *Brain* 2005; 128: 2442–52.
- Bloch MH, Leckman JF, Zhu H, Peterson BS. Caudate volumes in childhood predict symptom severity in adults with Tourette syndrome. *Neurology* 2005; 65: 1253–8.
- Bohlhalter S, Goldfine A, Matteson S, Garraux G, Hanakawa T, Kansaku K, *et al.* Neural correlates of tic generation in Tourette syndrome: an event-related functional MRI study. *Brain* 2006; 129: 2029–37.
- Catalan MJ, Honda M, Weeks RA, Cohen LG, Hallett M. The functional neuroanatomy of simple and complex sequential finger movements: a PET study. *Brain* 1998; 121: 253–64.
- Chemali Z, Bromfield E. Tourette's syndrome following temporal lobectomy for seizure control. *Epilepsy Behav* 2003; 4: 564–6.
- Chupin M, Géraud E, Cuingnet R, Boutet C, Lemieux L, Lehericy S, *et al.* Alzheimer's Disease Neuroimaging Initiative. Fully automatic hippocampus segmentation and classification in Alzheimer's disease and mild cognitive impairment applied on data from ADNI. *Hippocampus* 2009; 19: 579–87.
- Dale AM, Fischl B, Sereno MI. Cortical surface-based analysis. I. Segmentation and surface reconstruction. *Neuroimage* 1999; 9: 179–94.
- American Psychiatric Association. Diagnostic and statistical manual of mental disorders. 4th edn. DSMIV-TR. Washington, DC: American Psychiatric Association; 2000.
- Doyon J, Bellec P, Amsel R, Penhune V, Monchi O, Carrier J, *et al.* Contributions of the basal ganglia and functionally related brain structures to motor learning. *Behav Brain Res* 2009; 199: 61–75.
- Fahim C, Yoon U, Das S, Lyttelton O, Chen J, Arnaoutelis R, *et al.* Somatosensory–motor bodily representation cortical thinning in Tourette: effects of tic severity, age and gender. *Cortex* 2010; 46: 750–60.
- Fanselow MS, Dong HW. Are the dorsal and ventral hippocampus functionally distinct structures? *Neuron* 2010; 65: 7–19.
- Fischl B, Dale AM. Measuring the thickness of the human cerebral cortex from magnetic resonance images. *Proc Natl Acad Sci USA* 2000; 97: 11050–5.
- Fischl B, Sereno MI, Dale AM. Cortical surface-based analysis. II: Inflation, flattening, and a surface based coordinate system. *Neuroimage* 1999a; 9: 195–207.
- Fischl B, Sereno MI, Tootell RB, Dale AM. High-resolution intersubject averaging and a coordinate system for the cortical surface. *Hum Brain Mapp* 1999b; 8: 272–84.
- Fitzgerald KD, Welsh RC, Gehring WJ, Abelson JL, Himle JA, Liberzon I, *et al.* Error-related hyperactivity of the anterior cingulate cortex in obsessive-compulsive disorder. *Biol Psychiatry* 2005; 57: 287–94.

- Garraux G, Goldfine A, Bohlhalter S, Lerner A, Hanakawa T, Hallett M. Increased midbrain gray matter in Tourette's syndrome. *Ann Neurol* 2006; 59: 381–5.
- Gerardin E, Chételat G, Chupin M, Cuingnet R, Desgranges B, Kim HS, et al. Multidimensional classification of hippocampal shape features discriminates Alzheimer's disease and mild cognitive impairment from normal aging. *NeuroImage* 2009; 47: 1476–86.
- Goodman WK, Price LH, Rasmussen SA, Mazure C, Fleischmann RL, Hill CL, et al. The Yale-Brown Obsessive Compulsive Scale. I. Development, use, and reliability. *Arch Gen Psychiatry* 1989; 46: 1006–11.
- Grabli D, McCairn K, Hirsch EC, Agid Y, Feger J, Francois C, et al. Behavioural disorders induced by external globus pallidus dysfunction in primates: I. Behavioural study. *Brain* 2004; 127: 2039–54.
- Gusnard DA, Ollinger JM, Shulman GL, Cloninger CR, Price JL, Van Essen DC, et al. Persistence and brain circuitry. *Proc Natl Acad Sci USA* 2003; 100: 3479–84.
- Heise KF, Steven B, Liuzzi G, Thomalla G, Jonas M, Müller-Vahl K, et al. Altered modulation of intracortical excitability during movement preparation in Gilles de la Tourette syndrome. *Brain* 2010; 133: 580–90.
- Hong SB, Shin YW, Kim SH, Yoo SY, Lee JM, Kim IY, et al. Hippocampal shape deformity analysis in obsessive-compulsive disorder. *Eur Arch Psychiatry Clin Neurosci* 2007; 257: 185–90.
- Hwang J, Lyoo IK, Dager SR, Friedman SD, Oh JS, Lee JY, et al. Basal ganglia shape alterations in bipolar disorder. *Am J Psychiatry* 2006; 163: 276–85.
- Iturria-Molina Y, Perez Fernandez A, Morris DM, Canales-Rodríguez EJ, Haroon HA, Penton LG, et al. Brain hemispheric structural efficiency and interconnectivity rightward asymmetry in human and nonhuman primates. *Cereb Cortex* 2010; 10.1093/cercor/bhq058.
- Jankovic J, Fahn S. The phenomenology of tics. *Mov Disord* 1986; 1: 17–26.
- Kalanithi PS, Zheng W, Kataoka Y, DiFiglia M, Grantz H, Saper CB, et al. Altered parvalbumin-positive neuron distribution in basal ganglia of individuals with Tourette syndrome. *Proc Natl Acad Sci USA* 2005; 102: 13307–12.
- Kataoka Y, Kalanithi PS, Grantz H, Schwartz ML, Saper C, Leckman JF, et al. Decreased number of parvalbumin and cholinergic interneurons in the striatum of individuals with Tourette syndrome. *J Comp Neurol* 2010; 518: 277–91.
- Kloppel S, Mangin JF, Vongerichten A, Frackowiak R, Siebner HS. Nurture versus Nature: Long-Term Impact of Forced Right-Handedness on Structure of Pericentral Cortex and Basal Ganglia. *J Neurosci* 2010; 30: 3271–75.
- Kuperberg GR, Broome MR, McGuire PK, David AS, Eddy M, Ozawa F, et al. Regionally localized thinning of the cerebral cortex in schizophrenia. *Arch Gen Psychiatry* 2003; 60: 878–88.
- Leckman JF, Riddle MA, Hardin MT, Ort SI, Swartz KL, Stevenson J, et al. The Yale Global Tic Severity Scale: initial testing of a clinician-rated scale of tic severity. *J Am Acad Child Adolesc Psychiatry* 1989; 28: 566–73.
- Lehéricy S, Bardin E, Tremblay L, Van de Moortele PF, Pochon JB, Dormont D, et al. Motor control in basal ganglia circuits using fMRI and brain atlas approaches. *Cereb Cortex* 2006; 16: 149–61.
- Lehéricy S, Benali H, Van de Moortele PF, Pelegrini-Issac M, Waechter T, Ugurbil K, et al. Distinct basal ganglia territories are engaged in early and advanced motor sequence learning. *Proc Natl Acad Sci USA* 2005; 102: 12566–71.
- Ludolph AG, Juengling FD, Libal G, Ludolph AC, Fegert JM, Kassubek J. Grey-matter abnormalities in boys with Tourette syndrome: magnetic resonance imaging study using optimised voxel-based morphometry. *Br J Psychiatry* 2006; 188: 484–5.
- Lütcke H, Frahm J. Lateralized anterior cingulate function during error processing and conflict monitoring as revealed by high-resolution fMRI. *Cereb Cortex* 2008; 18: 508–15.
- Makki MI, Behen M, Bhatt A, Wilson B, Chugani HT. Microstructural abnormalities of striatum and thalamus in children with Tourette syndrome. *Mov Disord* 2008; 23: 2349–56.
- Makki MI, Govindan RM, Wilson BJ, Behen ME, Chugani HT. Altered fronto-striato-thalamic connectivity in children with Tourette syndrome assessed with diffusion tensor MRI and probabilistic fiber tracking. *J Child Neurol* 2009; 24: 669–78.
- Mathews CA, Jang KL, Herrera LD, Lowe TL, Budman CL, Erenberg G, et al. Tic symptom profiles in the subjects with Tourette syndrome from two genetically isolated populations. *Biol Psychiatry* 2007; 61: 292–300.
- Mazzone L, Yu S, Blair C, Gunter BC, Wang Z, Marsh R, et al. An FMRI study of frontostriatal circuits during the inhibition of eye blinking in persons with Tourette syndrome. *Am J Psychiatry* 2010; 167: 341–9.
- McCairn KW, Bronfeld M, Belevsky K, Bar-Gad I. The neurophysiological correlates of motor tics following focal striatal disinhibition. *Brain* 2009; 132: 2125–38.
- Mink JW. The Basal Ganglia and involuntary movements: impaired inhibition of competing motor patterns. *Arch Neurol* 2003; 60: 1365–8.
- Molenberghs P, Cunnington R, Mattingley JB. Is the mirror neuron system involved in imitation? A short review and meta-analysis. *Neurosci Biobehav Rev* 2009; 33: 975–80.
- Müller-Vahl KR, Kaufmann J, Grosskreutz J, Dengler R, Emrich HM, Peschel T. Prefrontal and anterior cingulate cortex abnormalities in Tourette Syndrome: evidence from voxel-based morphometry and magnetization transfer imaging. *BMC Neurosci* 2009; 10: 47.
- Narr KL, Bilder RM, Toga AW, Woods RP, Rex DE, Szeszko PR, et al. Mapping cortical thickness and gray matter concentration in first episode schizophrenia. *Cereb Cortex* 2005; 15: 708–19.
- Orth M, Rothwell JC. Motor cortex excitability and comorbidity in Gilles de la Tourette syndrome. *J Neurol Neurosurg Psychiatry* 2009; 80: 29–34.
- Passingham RE, Bengtsson SL, Lau HC. Medial frontal cortex: from self-generated action to reflection on one's own performance. *Trends Cogn Sci* 2010; 14: 16–21.
- Paus T. Primate anterior cingulate cortex: where motor control, drive and cognition interface. *Nat Rev Neurosci* 2001; 2: 417–24.
- Peterson BS, Choi HA, Hao X, Amat JA, Zhu H, Whiteman R, et al. Morphologic features of the amygdala and hippocampus in children and adults with Tourette syndrome. *Arch Gen Psychiatry* 2007; 64: 1281–91.
- Peterson BS, Skudlarski P, Anderson AW, Zhang H, Gatenby JC, Lacadie CM, et al. A functional magnetic resonance imaging study of tic suppression in Tourette syndrome. *Arch Gen Psychiatry* 1998; 55: 326–33.
- Peterson BS, Staib L, Scahill L, Zhang H, Anderson C, Leckman JF, et al. Regional brain and ventricular volumes in Tourette syndrome. *Arch Gen Psychiatry* 2001; 58: 427–40.
- Peterson BS, Thomas P, Kane MJ, Scahill L, Zhang H, Bronen R, et al. Basal ganglia volumes in patients with Gilles de la Tourette syndrome. *Arch Gen Psychiatry* 2003; 60: 415–24.
- Radua J, Mataix-Cols D. Voxel-wise meta-analysis of grey matter changes in obsessive-compulsive disorder. *Br J Psychiatry* 2009; 195: 393–402.
- Robertson MM. Tourette syndrome, associated conditions and the complexities of treatment. *Brain* 2000; 123: 425–62.
- Robertson MM, Althoff RR, Hafez A, Pauls DL. Principal components analysis of a large cohort with Tourette syndrome. *Br J Psychiatry* 2008; 193: 31–6.
- Rotge JY, Langbour N, Guehl D, Bioulac B, Jaafari N, Allard M, et al. Gray matter alterations in obsessive-compulsive disorder: an anatomic likelihood estimation meta-analysis. *Neuropsychopharmacology* 2010; 35: 686–91.
- Salkovskis PM. Obsessional-compulsive problems: a cognitive-behavioural analysis. *Behav Res Ther* 1985; 23: 571–83.
- Scherk H, Falkai P. Effects of antipsychotics on brain structure. *Curr Opin Psychiatry* 2006; 19: 145–50.
- Sheehan DV, Lecrubier Y, Sheehan KH, Amorim P, Janavs J, Weiller E, et al. The Mini-International Neuropsychiatric Interview (M.I.N.I.): the



- development and validation of a structured diagnostic psychiatric interview for DSM-IV and ICD-10. *J Clin Psychiatry* 1998; 20: 22–33.
- Singer HS. Tourette's syndrome: from behaviour to biology. *Lancet Neurol* 2005; 4: 149–59.
- Sinno D, Al-Amin H, Comair Y, Mikati MA. Exacerbation of vocal tics after temporal lobectomy. *Epilepsy Behav* 2006; 9: 211–3.
- Sowell ER, Kan E, Yoshii J, Thompson PM, Bansal R, Xu D, et al. Thinning of sensorimotor cortices in children with Tourette syndrome. *Nat Neurosci* 2008; 11: 637–39.
- Sowell ER, Peterson BS, Kan E, Woods RP, Yoshii J, Bansal R, et al. Sex differences in cortical thickness mapped in 176 healthy individuals between 7 and 87 years of age. *Cereb Cortex* 2007; 17: 1550–60.
- Stern E, Silbersweig DA, Chee KY, Holmes A, Robertson MM, Trimble M, et al. A functional neuroanatomy of tics in Tourette syndrome. *Arch Gen Psychiatry* 2000; 57: 741–8.
- Styner M, Lieberman JA, Pantazis D, Gerig G. Boundary and medial shape analysis of the hippocampus in schizophrenia. *Med Image Anal* 2004; 8: 197–203.
- Styner M, Oguz I, Xu S, Brechbuehler C, Pantazis D, Lewitt J, et al. Framework for the Statistical Shape Analysis of Brain Structures using SPHARM-PDM. *The insight Journal, MICCAI Open Science Workshop*. Copenhagen, Denmark, 2006.
- Swick D, Turken AU. Dissociation between conflict detection and error monitoring in the human anterior cingulate cortex. *Proc Natl Acad Sci USA* 2002; 99: 16354–9.
- Thomalla G, Siebner HR, Jonas M, Baumer T, Biermann-Ruben K, Hummel F, et al. Structural changes in the somatosensory system correlate with tic severity in Gilles de la Tourette syndrome. *Brain* 2009; 132: 765–77.
- Tobe RH, Bansal R, Xu D, Hao X, Liu J, Sanchez J, et al. Cerebellar morphology in Tourette syndrome and obsessive-compulsive disorder. *Ann Neurol* 2010; 67: 479–87.
- Wonders CP, Anderson SA. The origin and specification of cortical interneurons. *Nat Rev Neurosci* 2006; 7: 687–96.
- Woolley DG, Wenderoth N, Heuninckx S, Zhang X, Callaert D, Swinnen SP. Visual guidance modulates hemispheric asymmetries during an interlimb coordination task. *Neuroimage* 2010; 50: 1566–77.
- Worbe Y, Baup N, Grabli D, Chaigneau M, Mounayar S, McCairn K, et al. Behavioral and Movement Disorders Induced by Local Inhibitory Dysfunction in Primate Striatum. *Cereb Cortex* 2009; 19: 1844–56.
- Worsley KJ, Andermann M, Koulis T, MacDonald D, Evans A.C. Detecting changes in nonisotropic images. *Hum Brain Mapp* 1999; 8: 98–101.