

## REVIEW ARTICLE

# The role of dopaminergic imaging in patients with symptoms of dopaminergic system neurodegeneration

Jeffrey L. Cummings,<sup>1</sup> Claire Henchcliffe,<sup>2</sup> Sharon Schaier,<sup>3</sup> Tanya Simuni,<sup>4</sup> Alan Waxman<sup>5</sup> and Paul Kemp<sup>6</sup>

1 University of California, Los Angeles, Los Angeles, CA, USA

2 New York Hospital – Weill Cornell Medical Center, New York, NY, USA

3 PAREXEL Inc, Hackensack, NJ, USA

4 Northwestern University Feinberg School of Medicine, Chicago, IL, USA

5 Los Angeles County/University of Southern California Medical Centre, Los Angeles, CA, USA

6 Southampton University Hospitals Trust, Southampton, Hampshire, UK

Correspondence to: Jeffrey L. Cummings,  
Cleveland Clinic,  
Lou Ruvo Center for Brain Health,  
888 W. Bonneville Ave.,  
Las Vegas,  
NV 89106, USA  
E-mail: cumminj@ccf.org

Diagnosis of neurological and psychiatric conditions associated with disturbances of dopaminergic functioning can be challenging, especially in the early stages, and may be assisted with biomarkers such as dopamine system imaging. Distinguishing between Alzheimer's disease and dementia with Lewy bodies is a major diagnostic challenge. Clinical diagnosis of Parkinson's disease is straightforward with classic presentation, but accurate distinction among Parkinsonian variants may be difficult; non-Parkinson's disease conditions are commonly misdiagnosed as Parkinson's disease, and ~20% of patients with Parkinson's disease are not clinically diagnosed despite coming to medical attention. Early and accurate diagnosis is desirable to improve management. Imaging of the dopamine transporter using single-photon emission computed tomography may be of particular utility in this regard. Abnormal imaging indicates underlying nigrostriatal neurodegeneration, supportive of a diagnosis of Parkinson's disease, atypical parkinsonism or dementia with Lewy bodies, and identifies patient groups in whom dopaminergic therapy may be beneficial. Normal imaging supports diagnosis of a condition not involving nigrostriatal neurodegeneration such as Alzheimer's disease, essential tremor or drug-induced parkinsonism and hence a different therapeutic approach. In patients in whom there was diagnostic uncertainty between degenerative parkinsonism and non-degenerative tremor disorders, baseline imaging with the dopamine transporter ligand [<sup>123</sup>I]ioflupane (DaTscan™) has shown 78% sensitivity and 97% specificity with reference to clinical diagnosis at 3 years, versus 93% and 46%, respectively, for baseline clinical diagnosis. In a Phase III trial of [<sup>123</sup>I]ioflupane in patients with initial clinical diagnosis of probable or possible dementia with Lewy bodies or non-Lewy body dementia, mean specificity for excluding non-Lewy body dementia (predominantly Alzheimer's disease) was 90.4%. Using clinical diagnosis as a reference against which to assess sensitivity and specificity of dopamine transporter imaging is a limitation, but definitive diagnosis via pathological confirmation is generally not feasible. In a series of patients with post-mortem brain examination, imaging using [<sup>123</sup>I]ioflupane has demonstrated higher sensitivity (88%) and specificity (100%) for differentiating dementia with Lewy bodies from non-Lewy body dementia than clinical diagnosis (75% and 42%, respectively).

Dopaminergic system imaging may be particularly valuable in patients with clinically inconclusive parkinsonism or a clinical diagnosis of possible dementia with Lewy bodies; it is not helpful in differentiating between Parkinson's disease and atypical parkinsonism, although postsynaptic dopaminergic imaging may be of utility. Other potential uses of dopamine transporter imaging include identification of patients with premotor Parkinson's disease, monitoring disease progression in testing novel therapeutics, and as an inclusion criterion for entry into clinical trials.

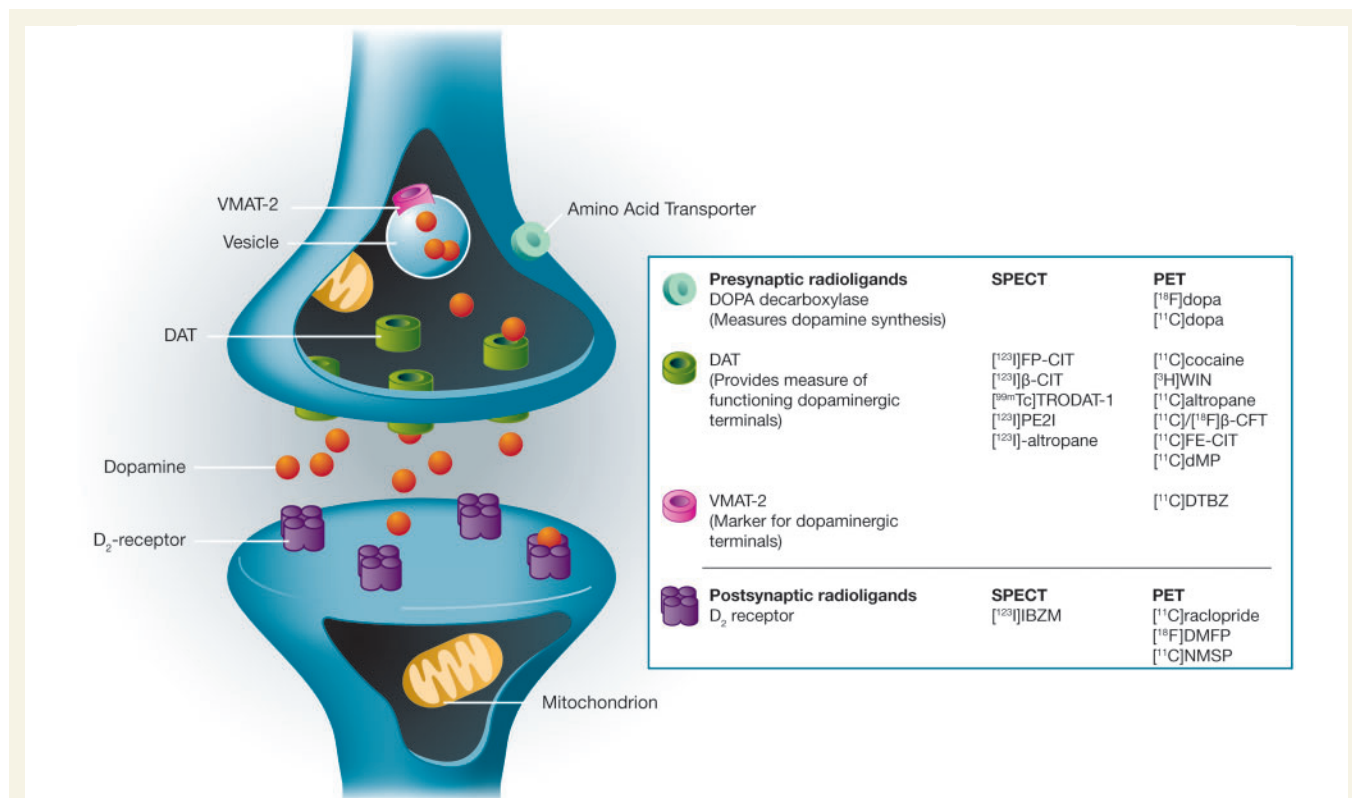
**Keywords:** Alzheimer's disease; dementia with Lewy bodies; dopaminergic imaging; neurodegeneration; Parkinson's disease

**Abbreviations:**  $\beta$ -CIT = [2 $\beta$ -carbomethoxy-3 $\beta$ -(4-[<sup>123</sup>I]iodophenyl)tropane iometopane]; DLB = dementia with Lewy bodies; DOPA = dihydroxyphenylalanine; FP-CIT = [*N*- $\omega$ -fluoropropyl-2 $\beta$ -carbomethoxy-3 $\beta$ -(4-[<sup>123</sup>I]iodophenyl)nortropane]; SPECT = single-photon emission computed tomography

## Introduction

Disturbances of dopaminergic functioning are associated with numerous neurological and psychiatric conditions. Diagnosis of these conditions may be difficult, particularly in the early stages, and may be assisted with biomarkers such as dopamine system imaging. Functional imaging with specific dopamine-related tracers may be used to assess functioning at presynaptic terminals or postsynaptic binding sites, measuring density of binding sites or

alterations in neurotransmitter synthesis, storage, release or reuptake. We review the utility of dopamine system imaging in the diagnosis of neurodegenerative disorders. Imaging can be performed using single-photon emission computed tomography (SPECT) or PET. We focus on the use of SPECT tracers binding to the dopamine transporter as currently SPECT is more widely available for routine clinical use. Most multi-site neuroimaging studies utilizing dopamine system imaging have used this methodology.



**Figure 1** Dopaminergic radioligands for SPECT and PET.  $\beta$ -CFT = 2 $\beta$ -carbomethoxy-3 $\beta$ -(4-fluorophenyl)tropane; DAT = dopamine transporter; dopa = dihydroxyphenylalanine; DMFP = desmethoxyfallypride; dMP = d-threo methylphenidate; DTBZ = dihydrotetrabenazine; FE-CIT = (*N*-(2-fluoroethyl)-2 $\beta$ -carbomethoxy-3 $\beta$ -(4-iodophenyl)nortropane; IBZM = iodobenzamide; NMSP = 3-*N*-methylspiperone; PE2I = *N*-(3-iodoprop-(2*E*)-enyl)-2 $\beta$ -carboxymethoxy-3 $\beta$ -(4'-methylphenyl)nortropane; TRODAT-1 = [2-[[[2-[[[3-(4-chlorophenyl)-8-methyl-8-azabicyclo[3.2.1]oct-2-yl]methyl](2-mercaptoethyl)amino]ethyl]amino]ethanethiolato(3-)-*N*2,*N*20,*S*2,*S*20]oxo-[1*R*-(exo-exo)]; VMAT = vesicular monoamine transporter; WIN = WIN 55,212-2 cannabinoid receptor agonist.

## Dopamine system imaging agents

Several dopamine-related imaging agents have been developed to assess the integrity of dopaminergic neurons using SPECT or PET (Fig. 1). These radioligands image either presynaptic targets—dopamine transporter, vesicular monoamine transporter or dihydroxyphenylalanine (DOPA) decarboxylase activity (reflecting dopamine synthesis)—or postsynaptic  $D_2$  dopamine receptors. The most commonly used SPECT ligands bind to dopamine transporter, reduction of which correlates with the loss of presynaptic dopamine. Ligands for dopamine transporter include: [ $^{123}$ I]FP-CIT (*N*- $\omega$ -fluoropropyl-2 $\beta$ -carbomethoxy-3 $\beta$ -(4-[ $^{123}$ I]iodophenyl)nortropine, ioflupane, DaTscan<sup>TM</sup>); [ $^{99m}$ Tc]TRODAT-1 [2-[[[3-(4-chlorophenyl)-8-methyl-8-azabicyclo[3.2.1]oct-2-yl]methyl](2-mercaptoethyl)amino]ethyl]amino]ethanethiolato(3-)-*N*2,*N*20,*S*2,*S*20]oxo-[1*R*-(exo-exo)]; and [ $^{123}$ I] $\beta$ -CIT (2 $\beta$ -carbomethoxy-3 $\beta$ -(4-[ $^{123}$ I]iodophenyl)tropane, iometopane). The first two of these ligands have more rapid binding kinetics, enabling imaging 3–6 h after administration rather than 20–30 h (Booij *et al.*, 1997; Hwang *et al.*, 2004). [ $^{123}$ I]Altopane SPECT images have been less extensively investigated and are more difficult to quantify owing to rapid washout from the brain (Seibyl *et al.*, 2005a). Ligands for PET imaging are shown in Fig. 1. Few direct comparisons between ligands have been carried out, though a crossover study using [ $^{99m}$ Tc]TRODAT-1 SPECT and [ $^{18}$ F] DOPA PET found a generally similar imaging pattern between the two approaches (Huang *et al.*, 2003).

## Parkinsonism and dopaminergic neurodegeneration

Parkinson's disease is the second most common neurodegenerative disorder (after Alzheimer's disease) (Nussbaum and Ellis, 2003), yet early accurate diagnosis remains challenging. The estimated prevalence of Parkinson's disease is 0.5–1% in those aged 65–69 years, rising to 1–3% in those aged  $\geq 80$  years (Nussbaum and Ellis, 2003). There are thought to be in excess of 500 000 sufferers in the USA, with 50 000 new cases each year (National Institute of Neurological Disorders and Stroke, 2004). Parkinson's disease is characterized clinically by asymmetric parkinsonism (resting tremor, bradykinesia, rigidity and later postural instability) and pathologically by the loss of neurons, particularly dopaminergic neurons, in the substantia nigra that project primarily to the striatum. There are ubiquitous protein deposits in the cytoplasm of neurons, termed Lewy bodies, and thread-like proteinaceous inclusions in neurites, termed Lewy neurites. These occur characteristically not only in the substantia nigra (Nussbaum and Ellis, 2003), but also in other subcortical and cortical regions (Braak *et al.*, 2003), as well as in peripheral autonomic neurons. There are a number of other neurodegenerative diseases associated with parkinsonism and frequently labelled as atypical [parkinsonism or parkinsonian plus syndromes, including multiple system atrophy, progressive

supranuclear palsy, corticobasal degeneration and dementia with Lewy bodies (DLB). All of these conditions are associated with nigrostriatal degeneration. Clinical manifestations of parkinsonism can also be seen in conditions not involving nigrostriatal degeneration like vascular parkinsonism and drug-induced parkinsonism, among others. Parkinsonism must also be distinguished from conditions such as essential tremor and Parkinson's disease with dementia must be distinguished from Alzheimer's disease.

Although the clinical diagnosis of Parkinson's disease may be straightforward in cases with classic presentation, accurate distinction among variants of parkinsonism may be difficult, particularly in the early or mild stages of disease. Moreover, subtle signs of parkinsonism can be clinically confused with orthopaedic diagnoses, systemic medical illness or depression. Autopsy studies in patients with an initial clinical diagnosis of Parkinson's disease reveal a substantial number of cases with alternative diagnoses. In one study, 24% lacked Lewy bodies and had diagnoses including progressive supranuclear palsy, multiple system atrophy, Alzheimer's disease, Alzheimer-type pathology and basal ganglia vascular disease (Hughes *et al.*, 1992). In another autopsy study of 65 patients, 59 with complete data, 43 had an initial diagnosis of Parkinson's disease; after a mean of 12 years follow-up, the final diagnosis was Parkinson's disease in 41 cases, which was confirmed in 31 (76%) (Rajput *et al.*, 1991). Although the correct clinical diagnosis was made in most non-Parkinson's disease variants of parkinsonism within 5 years of onset, the time to reach the correct clinical diagnosis ranged from 2 months to 18 years (Rajput *et al.*, 1991). Misdiagnosis of non-Parkinson's disease conditions (essential tremor, vascular parkinsonism, multiple system atrophy and progressive supranuclear palsy) as Parkinson's disease means that 5–25% of patients diagnosed clinically with Parkinson's disease are inappropriately receiving anti-parkinsonian medication from which they derive little or no benefit (Meara *et al.*, 1999; Schrag *et al.*, 2002; Newman *et al.*, 2009). Conversely,  $\sim 20\%$  of patients with Parkinson's disease are not clinically diagnosed as such despite coming to medical attention (Schrag *et al.*, 2002). Even among specialists, although the positive predictive value of a clinical diagnosis of Parkinson's disease is high,  $\sim 99\%$ , sensitivity is lower,  $\sim 91\%$ , owing to false-negative diagnoses (Hughes *et al.*, 2002). Early, accurate diagnosis in patients with parkinsonism is important for several reasons, including correct prognostication and management, and the avoidance of unnecessary medical examinations and therapies and their associated financial costs, side-effects and safety risks. Correct diagnosis is also critically important when patients are being recruited into clinical trials.

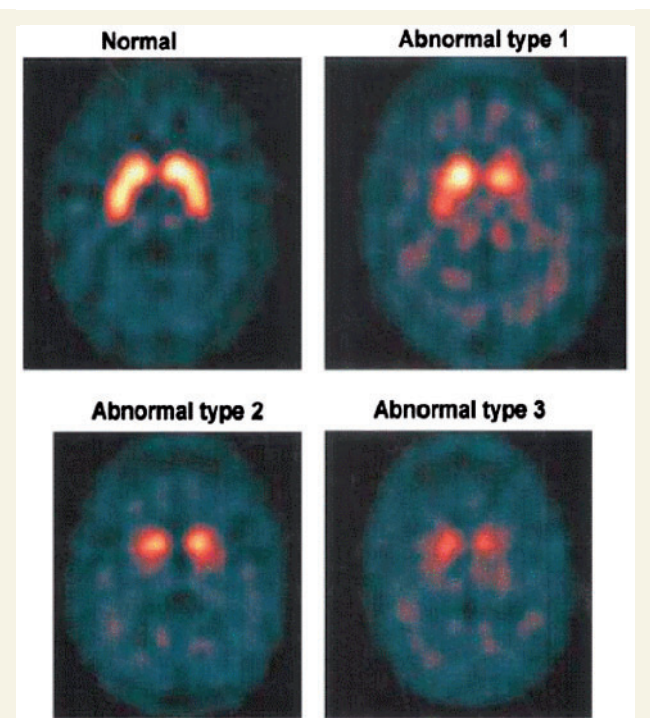
Biomarkers that distinguish between the different causes of parkinsonism would reduce misdiagnosis and facilitate timely and appropriate therapy. Blood and CSF markers of neurodegenerative parkinsonism (e.g.  $\alpha$ -synuclein) show promise and may aid clinical diagnosis in the future, but are still in the early stages of development (Eller and Williams, 2009). Neuroimaging of the dopaminergic system offers substantial promise as a biomarker for early diagnosis that has differential diagnostic utility.

## Discriminating between neurodegenerative parkinsonism and its mimics

Post-mortem studies demonstrate severe reductions in dopamine concentration in the striatum of patients with Parkinson's disease, with greater reductions in the putamen than the caudate, particularly in the caudal putamen (Kish *et al.*, 1988; Piggott *et al.*, 1999). This may result from both cell body and axonal loss (Cheng *et al.*, 2010). Dopaminergic imaging discriminates patients with Parkinson's disease from healthy individuals, identifying presynaptic dopaminergic deficits in the caudate and putamen with high specificity and sensitivity, even in early disease (Weng *et al.*, 2004; Shih *et al.*, 2006; Eshuis *et al.*, 2009), and has the potential to discriminate between neurodegenerative parkinsonism and its mimics. In clinically uncertain cases, dopaminergic imaging may assist in confirming or excluding nigrostriatal neurodegeneration. Several studies in clinically uncertain parkinsonian syndromes (idiopathic Parkinson's disease and Parkinson's disease plus/atypical parkinsonism syndromes) support this contention. Note, however, that to date, in the absence of histopathological material, nearly all imaging studies have used clinical diagnoses as the gold standards, which, as discussed above, may not always be accurate.

The largest prospective study of patients ( $n = 118$ ) with clinically uncertain parkinsonian syndromes evaluated in a routine clinical setting was published by Catafau *et al.* (2004). [ $^{123}$ I]FP-CIT SPECT images were classified visually as normal or abnormal by nuclear medicine physicians expert in neuroimaging (Fig. 2). [ $^{123}$ I]FP-CIT SPECT results were inconsistent with the initial diagnosis in a telling proportion of patients. Thirty-six per cent of patients with suspected diagnosis of presynaptic parkinsonian syndrome (Parkinson's disease or atypical parkinsonism) had a normal scan, and 54% of those with a suspected diagnosis of non-presynaptic parkinsonian syndrome had an abnormal scan. The diagnosis was changed after imaging in 52% of patients and planned management was changed in 72% (Catafau *et al.*, 2004). All patients with a final diagnosis of presynaptic parkinsonian syndrome had abnormal imaging and 94% of patients with a final diagnosis of non-presynaptic parkinsonian syndrome had normal imaging; only two patients with abnormal scans had a diagnosis of non-presynaptic parkinsonian syndrome (essential tremor and vascular parkinsonism). After 2 years' follow-up, clinical diagnosis agreed with the initial dopamine transporter SPECT results in 90% of patients in whom a specific diagnosis was established (Tolosa *et al.*, 2007a). Follow-up SPECT helped to establish a diagnosis in seven of eight patients with a previously inconclusive diagnosis.

In a small prospective study of 15 patients with clinically uncertain parkinsonian syndromes, 13 with probable Parkinson's disease, and 13 healthy controls evaluated using [ $^{99m}$ Tc]TRODAT-1 SPECT, there was 80% agreement between the baseline SPECT diagnosis and gold standard clinical diagnosis of Parkinson's disease at 2 years' follow-up, and 100% sensitivity (Felicio *et al.*, 2010a). In a group of 33 patients with inconclusive aetiology of parkinsonism followed clinically for 2–4 years after initial



**Figure 2** [ $^{123}$ I]FP-CIT SPECT images in patients with clinically uncertain parkinsonian syndromes. Abnormal patterns are defined as: Type 1, asymmetrical uptake with reduced putamen activity in one hemisphere; Type 2, clear symmetrical reduction of putamen uptake in both hemispheres; Type 3, virtual absence of uptake in both putamen and caudate nuclei on each side of the brain, resulting in significant reduction in contrast and the visualization of background activity throughout the rest of the image (Catafau *et al.*, 2004). Reproduced with permission.

[ $^{123}$ I]FP-CIT SPECT, nine had evidence of nigrostriatal degeneration, in all of whom pre synaptic parkinsonism was confirmed on clinical follow-up (Parkinson's disease in seven cases, multiple system atrophy in two) (Booij *et al.*, 2001). In the 24 patients lacking evidence of presynaptic degeneration, forms of parkinsonism other than presynaptic parkinsonism were confirmed at follow-up in 19 (five essential tremor, four vascular parkinsonism, four psychogenic parkinsonism, three drug-induced parkinsonism, one non-dopa-responsive dystonia, one post-traumatic encephalopathy, one Fahr's disease); in three patients, no conclusive diagnosis was established but presynaptic parkinsonism was excluded clinically, and the remaining two cases were thought to have false negative scans.

In another study in 35 patients with suspected parkinsonian syndrome referred by community neurologists, [ $^{123}$ I] $\beta$ -CIT SPECT imaging and the diagnosis at referral were compared to a gold standard clinical diagnosis made at 6 months' follow-up by a movement disorder specialist blinded to the imaging results (Jennings *et al.*, 2004). With reference to the specialist diagnosis, dopamine transporter SPECT imaging had sensitivity of 92% and specificity of 100%, versus 92% sensitivity and 30% specificity for the community neurologist's diagnosis. Imaging would have

improved community physicians' diagnosis to levels of sensitivity and specificity similar to those achieved by specialists.

In a single centre study, 248 patients with an unclassified parkinsonian syndrome had baseline SPECT imaging using either [<sup>123</sup>I]FP-CIT or [<sup>123</sup>I]iodobenzamide (a D<sub>2</sub> receptor ligand). Subjects were followed for 18 months post-scans. [<sup>123</sup>I]FP-CIT, in comparison with clinical diagnosis from the latest available clinical records or examination by a blinded movement disorders specialist, discriminated between Parkinson's disease and essential tremor with 80% sensitivity and 95% specificity, between Parkinson's disease and vascular parkinsonism with 80% sensitivity and 100% specificity, and between Parkinson's disease and drug-induced parkinsonism with 80% sensitivity and 100% specificity (Vlaar *et al.*, 2008). The corresponding odds ratios (95% confidence interval) were 82 (11–674) for Parkinson's disease versus essential tremor, 61 (8–490) for Parkinson's disease versus vascular parkinsonism, and 36 (2–97) for Parkinson's disease versus drug-induced parkinsonism (Vlaar *et al.*, 2008). Sensitivity and specificity values for [<sup>123</sup>I]iodobenzamide were less than or equal to those for [<sup>123</sup>I]FP-CIT, and combining the two did not significantly improve diagnostic accuracy. Both [<sup>123</sup>I]FP-CIT [80% sensitivity, 24% specificity, odds ratio 1 (0–4)] and [<sup>123</sup>I]iodobenzamide SPECT [80% sensitivity, 62% specificity, odds ratio 7 (2–17)] had low ability to differentiate between Parkinson's disease and atypical parkinsonism.

A 3-year prospective, multicentre study compared clinical diagnosis with [<sup>123</sup>I]FP-CIT SPECT in 199 patients in whom there was diagnostic uncertainty between degenerative parkinsonism and non-degenerative tremor disorders (Marshall *et al.*, 2009). The gold standard clinical diagnosis was performed at 36 months by two movement disorder specialists using clinical data and video recordings, and dopamine transporter images were assessed by three readers blinded to the clinical diagnosis. Of 99 patients who had imaging at baseline, 18 and 36 months and had a 36-month gold standard video consensus diagnosis, 71 had a gold standard clinical (video) diagnosis of degenerative parkinsonism (66 probable and five possible Parkinson's disease); of these patients, 56 had an abnormal baseline SPECT image (all with probable Parkinson's disease). Of the 71 patients with gold standard clinical (video) diagnosis of degenerative parkinsonism, 17 were not taking anti-parkinsonian medication at 36 months (decisions about medication were made by the patient's clinician); 10 of these 17 (56%) had normal baseline SPECT images. Of the 28 patients with a gold standard clinical (video) diagnosis of non-Parkinson's disease at 36 months, 27 had a normal SPECT image, and 13 were incorrectly clinically diagnosed with Parkinson's disease on study entry. With reference to the 3-year gold standard clinical (video) diagnosis, baseline [<sup>123</sup>I]FP-CIT SPECT showed a mean sensitivity of 78% and a specificity of 97%, in comparison with values of 93% and 46% for baseline clinical diagnosis. Inter-reader agreement with regard to visual assessment (normal or abnormal) of scans was high at all time-points (Cohen's  $\kappa$  0.94–0.97).

A number of recently completed clinical trials in early Parkinson's disease used SPECT imaging as a secondary outcome measure (Fahn *et al.*, 2004; Parkinson Study Group PRECEPT Investigators, 2007). About 10–15% of subjects recruited by

movement disorders experts with the diagnosis of Parkinson's disease had dopaminergic imaging scans without evidence of dopaminergic deficit (Fahn *et al.*, 2004; Seibyl *et al.*, 2005a). Although scans without evidence of dopaminergic deficit may be false-negatives, indicative of low sensitivity of the imaging technique (Morrish, 2010), substantial evidence suggests that most, if not all, patients with scans without evidence of dopaminergic deficit do not have involvement of the nigrostriatal pathway and do not have Parkinson's disease, indicating that this is an issue of misdiagnosis rather than inadequate sensitivity of the scan. The fact that dopaminergic imaging changes are evident in the preclinical stages in most patients with Parkinson's disease (Pavese and Brooks, 2009) makes it unlikely that dopaminergic imaging would be normal in patients with symptoms. In addition, long-term follow-up of patients with scans without evidence of dopaminergic deficit indicates poor response to levodopa and lack of progression on sequential dopaminergic imaging (Marek *et al.*, 2005; Schneider *et al.*, 2007). Thus, a normal image in a patient with symptoms is suggestive of a diagnosis other than neurodegenerative parkinsonism, while an abnormal image supports a diagnosis of parkinson's disease or other neurodegenerative striatonigral disease. Clinical progression indicative of neurodegenerative parkinsonism is noted in a small proportion of cases (3%) with normal baseline dopamine transporter imaging, establishing that false negative scans occur in a few patients and highlighting the need for clinical follow-up of scans without evidence of dopaminergic deficit, as a normal baseline scan may not definitively exclude Parkinson's disease (Marshall *et al.*, 2006). There is a consensus that a normal scan excludes presynaptic parkinsonism in a majority of clinical cases.

The results of these studies indicate that abnormal dopamine transporter imaging, at least in cases in which there is diagnostic uncertainty, is strongly supportive of a diagnosis of neurodegenerative parkinsonism. The clinical profile and response to therapy of patients with a clinical diagnosis of Parkinson's disease but normal [<sup>123</sup>I]FP-CIT SPECT imaging is consistent in most cases with the diagnosis of a non-degenerative movement disorder.

## Essential tremor

In one study of patients diagnosed with essential tremor, approximately one-third were judged upon careful review by movement disorder specialists to be erroneously diagnosed, with clinical evidence of Parkinson's disease present in 15%, dystonia in 8% and Parkinson's disease with essential tremor in 7% (Jain *et al.*, 2006). Although distinguishing Parkinson's disease from essential tremor on a clinical basis is simple in classic presentations, essential tremor is increasingly recognized as a heterogeneous disorder that can encompass features such as rest tremor (Cohen *et al.*, 2003; Louis *et al.*, 2009), which can challenge accurate diagnosis. A recent autopsy series of nine cases demonstrated a lack of Lewy body pathology in cases of essential tremor with upper extremity rest tremor (Louis *et al.*, 2010). A series of studies, cross-sectional and longitudinal, have shown a decrease in dopamine transporter density in Parkinson's disease in comparison with essential tremor, and no differences between essential tremor and healthy controls (Table 1) (Asenbaum *et al.*, 1998; Benamer *et al.*, 2000; Antonini

**Table 1 Dopaminergic imaging studies in patients with Parkinson's disease/essential tremor**

Study	Imaging modality	Clinical diagnosis	Key findings
Asenbaum <i>et al.</i> (1998)	[ <sup>123</sup> I]β-CIT SPECT	Essential tremor ( <i>n</i> = 32), Parkinson's disease ( <i>n</i> = 29), controls ( <i>n</i> = 30)	Striatal [ <sup>123</sup> I]β-CIT essential tremor within normal range; significantly lower in Parkinson's disease than essential tremor and controls
Benamer <i>et al.</i> (2000)	[ <sup>123</sup> I]FP-CIT SPECT	Essential tremor ( <i>n</i> = 27), parkinsonism ( <i>n</i> = 158), controls ( <i>n</i> = 35)	Image rating normal/abnormal (consensus reading) corresponded with clinical diagnosis in 94.9% parkinsonism, 92.6% essential tremor, 94.3% controls
Antonini <i>et al.</i> (2001)	[ <sup>11</sup> C]FE-CIT PET	Essential tremor ( <i>n</i> = 5), parkinson's disease ( <i>n</i> = 31), controls ( <i>n</i> = 8)	[ <sup>11</sup> C]FE-CIT in caudate and putamen significantly lower in Parkinson's disease than essential tremor and controls; essential tremor versus controls non-significant
Wang <i>et al.</i> (2005)	[ <sup>99m</sup> Tc]TRODAT-1 SPECT	Essential tremor ( <i>n</i> = 12), Parkinson's disease ( <i>n</i> = 27), controls ( <i>n</i> = 10)	Striatal [ <sup>99m</sup> Tc]TRODAT-1 significantly lower in Parkinson's disease than essential tremor and controls; 96.4% sensitivity and 91.7% specificity in differentiating Parkinson's disease from essential tremor
Breit <i>et al.</i> (2006)	[ <sup>11</sup> C]dMP PET	Essential tremor ( <i>n</i> = 6), Parkinson's disease ( <i>n</i> = 20), controls ( <i>n</i> = 10)	No difference in [ <sup>11</sup> C]dMP binding essential tremor versus controls In Parkinson's disease, binding 30% versus healthy controls in putamen, 52% versus controls in caudate
Doepp <i>et al.</i> (2008)	[ <sup>123</sup> I]FP-CIT SPECT	Essential tremor ( <i>n</i> = 46), Parkinson's disease, ( <i>n</i> = 25)	Abnormal [ <sup>123</sup> I]FP-CIT SPECT in 42/71. Ninety-one per cent sensitivity, 100% specificity versus clinical diagnosis
Isaias <i>et al.</i> (2010)	[ <sup>123</sup> I]FP-CIT SPECT	Essential tremor ( <i>n</i> = 20), Parkinson's disease ( <i>n</i> = 13), controls ( <i>n</i> = 23)	Reduced dopamine transporter binding in Parkinson's disease versus essential tremor and controls, with annual rate of decline of 7.3% in the contralateral putamen; no differences in uptake between essential tremor and controls at baseline and no loss of uptake over time in essential tremor

[<sup>11</sup>C]dMP = [<sup>11</sup>C]d-threo-methylphenidate; FE-CIT = (*N*-(2-fluoroethyl)-2β-carbomethoxy-3β-(4-iodophenyl)nortropane; Tc = technetium; TRODAT-1 = [2-[[2-[[[3-(4-chlorophenyl)-8-methyl-8-azabicyclo[3.2.1]oct-2-yl]methyl](2-mercaptoethyl)amino]ethyl]amino]ethanethiolato(3-)-*N*2,*N*20,*S*2,*S*20]oxo-[1*R*-(exo-exo)].

*et al.*, 2001; Wang *et al.*, 2005; Breit *et al.*, 2006; Doepp *et al.*, 2008; Isaias *et al.*, 2010). The largest of these studies was a Phase III clinical trial in six centres assessing the reliability of visually assessed dopamine transporter imaging using [<sup>123</sup>I]FP-CIT SPECT in patients with clinically diagnosed parkinsonism (*n* = 158) or essential tremor (*n* = 27) and healthy volunteers (*n* = 35) (Benamer *et al.*, 2000). Images were rated as normal or abnormal by nuclear medicine experts blinded to clinical data within each institution and by a research consensus panel of five experts. The institutional reading scored 154/158 cases of parkinsonism as abnormal, all 27 cases of essential tremor as normal and 34/35 healthy volunteers as normal, in comparison with corresponding numbers of 150, 25 and 33, respectively, by the consensus blinded read. Sensitivity of [<sup>123</sup>I]FP-CIT SPECT imaging with reference to the clinical diagnosis of parkinsonism was 97% for the institutional read and 95% for the consensus read; specificity for essential tremor was 100% for the institutional read and 93% for the consensus read. Other studies have reached similar conclusions and indicated that dopamine transporter imaging identifies dysfunction of the nigrostriatal dopaminergic system, thus confirming the diagnosis in patients with parkinsonism and differentiating them from patients with essential tremor and healthy individuals (Asenbaum *et al.*, 1998; Benamer *et al.*, 2000; Antonini *et al.*, 2001; Wang *et al.*, 2005; Breit *et al.*, 2006; Doepp *et al.*, 2008; Isaias *et al.*, 2010). These

observations support the conclusion that an abnormal dopamine transporter SPECT image should be regarded as an exclusion criterion for essential tremor.

## Dystonic tremor

Patients with dystonic tremor may be misdiagnosed with Parkinson's disease, and dystonic tremor may be a cause of scans without evidence of dopaminergic deficit in suspected Parkinson's disease (Schneider *et al.*, 2007). In 10 cases diagnosed as possible Parkinson's disease, patients presented with asymmetric resting arm tremor, but had signs of dystonia and absence of true akinesia after a mean of 5.8 years of follow-up; all had normal baseline [<sup>123</sup>I]FP-CIT SPECT scans. Patients with dystonic tremor have normal dopamine transporter scans, thus making dopamine transporter imaging a useful tool by which to distinguish these patients from patients with Parkinson's disease.

## Vascular parkinsonism

Vascular parkinsonism may account for up to 12% of all cases of parkinsonism (Thanvi and Robinson, 2005). The diagnosis of vascular parkinsonism is challenging and there is no consensus on the diagnostic criteria (Kalra *et al.*, 2010). In addition, vascular

parkinsonism cannot always be confirmed on the basis of clinical features or structural neuroimaging, as coincidental vascular lesions are common in Parkinson's disease (Thanvi and Robinson, 2005; Kalra *et al.*, 2010). Dopaminergic imaging studies may help with the diagnosis of vascular parkinsonism, although studies have provided conflicting results (Table 2). Two studies found near normal dopamine transporter binding in patients with vascular parkinsonism, differentiating them from patients with Parkinson's disease (Tzen *et al.*, 2001; Gerschlager *et al.*, 2002), whereas other studies have found reduced dopamine transporter binding in patients with vascular parkinsonism, which in some cases, had a pattern different from that in Parkinson's disease (Lorberboym *et al.*, 2004; Zijlmans *et al.*, 2007). In general, patients with vascular parkinsonism have more diffuse and symmetrical abnormalities than those seen in Parkinson's disease. For example, one study of 13 patients fulfilling operational criteria for vascular parkinsonism found that mean [<sup>123</sup>I]FP-CIT binding in the basal ganglia was significantly lower than in healthy controls, and the only significant difference between patients with vascular parkinsonism and those with Parkinson's disease was that the asymmetry index was significantly lower in patients with vascular parkinsonism (Zijlmans *et al.*, 2007). Taken together, these studies suggest a normal dopamine transporter imaging study excludes Parkinson's disease, but an abnormal result could represent vascular parkinsonism or Parkinson's disease. Specific features (diffuse uptake, more synaptic uptake in vascular parkinsonism) may help differentiate the two conditions. Patients with cerebrovascular disease with an abnormal dopamine transporter image may be more likely to benefit from a trial of dopamine replacement therapy. In addition, a trial of dopamine therapy may be warranted in patients in whom MRI reveals a lesion close to the nigrostriatal pathway or extensive white matter ischaemic injury in this area.

## Drug-induced parkinsonism

Drug-induced parkinsonism is the second most common cause of parkinsonism in older people (Thanvi and Treadwell, 2009). Drug-induced parkinsonism in the majority of cases results from

postsynaptic dopamine receptor blockade, with the most common offending agents being neuroleptics and related compounds (e.g. anti-emetics). Some other drugs have been reported to cause drug-induced parkinsonism, including lithium, valproic acid and certain calcium channel blockers (cinnarizine and flunarizine) (Van Gerpen 2002; Teive *et al.*, 2004). Discontinuation of the causative drug usually leads to progressive improvement in symptoms. However, in some patients parkinsonism may persist and eventually worsen; this is thought to result from unmasking of preclinical Parkinson's disease (Lorberboym *et al.*, 2006). It is difficult to distinguish drug-induced parkinsonism from degenerative parkinsonism on a clinical basis. Dopaminergic SPECT or PET may be helpful in making the differentiation (Table 3). The uptake of tracer is normal in drug-induced parkinsonism unless there is presymptomatic Parkinson's disease or other unrelated causes of dopaminergic system neurodegeneration (Burn and Brooks, 1993; Tolosa *et al.*, 2003; Lorberboym *et al.*, 2006; Diaz-Corrales *et al.*, 2010). A normal scan identifies patients with drug-induced parkinsonism, in whom parkinsonism is expected to resolve with the discontinuation of the causative agent. An abnormal scan indicates the presence of presynaptic dopamine deficiency. Such patients should be followed clinically and, in case of lack of resolution of parkinsonism after discontinuation of the presumed offending agent, they may benefit from initiation of dopaminergic therapy. The time required for resolution of drug-induced parkinsonism has not been clearly established. In one large study, median time to resolution after stopping medication was 7 weeks, with a range up to 36 weeks (Stephen and Williamson, 1984), but in some individuals symptoms may persist up to 18 months (Marsden and Jenner, 1980). In another study of 17 elderly patients with drug-induced parkinsonism, ~60% experienced total remission over a range of 2–19 months (mean 10 months) (Esper and Factor, 2008). The availability of an abnormal dopamine transporter SPECT image will facilitate the decision regarding initiation of dopaminergic therapy. In some patients with incipient Parkinson's disease, D<sub>2</sub> blocking medication may make the patient seek medical help earlier than would be expected in the natural course of Parkinson's disease, which requires the loss of 60–80%

**Table 2 Dopaminergic imaging studies in patients with Parkinson's disease/vascular parkinsonism**

Study	Imaging modality	Clinical diagnosis	Key findings
Tzen <i>et al.</i> (2001)	[ <sup>99m</sup> Tc]TRODAT-1 SPECT	Vascular parkinsonism ( <i>n</i> = 14), Parkinson's disease ( <i>n</i> = 30), controls ( <i>n</i> = 26)	Striatal [ <sup>99m</sup> Tc]TRODAT binding significantly lower in Parkinson's disease than vascular parkinsonism and healthy controls; vascular parkinsonism not significantly different from controls
Gerschlager <i>et al.</i> (2002)	[ <sup>123</sup> I]β-CIT SPECT	Vascular parkinsonism ( <i>n</i> = 13), Parkinson's disease ( <i>n</i> = 20), controls ( <i>n</i> = 30)	Age-corrected striatal [ <sup>123</sup> I]β-CIT binding significantly reduced by 41% in Parkinson's disease; vascular parkinsonism not significantly different from controls
Lorberboym <i>et al.</i> (2004)	[ <sup>123</sup> I]FP-CIT SPECT	Vascular parkinsonism ( <i>n</i> = 20), controls ( <i>n</i> = 10)	Striatal [ <sup>123</sup> I]FP-CIT binding normal in nine vascular parkinsonism, significantly reduced versus controls in 11
Zijlmans <i>et al.</i> (2007)	[ <sup>123</sup> I]FP-CIT SPECT	Vascular parkinsonism ( <i>n</i> = 13), Parkinson's disease ( <i>n</i> = 14), controls ( <i>n</i> = 14)	[ <sup>123</sup> I]FP-CIT binding in basal ganglia significantly lower in vascular parkinsonism than controls; mean asymmetry index significantly lower in vascular parkinsonism than Parkinson's disease

Tc = technetium; TRODAT-1 = [2-[[[2-[[[3-(4-chlorophenyl)-8-methyl-8-azabicyclo[3.2.1]oct-2-yl]methyl](2-mercaptoethyl)amino]ethyl]amino]ethanethiolato(3-)-N2,N20,S2,S20]oxo-[1R-(exo-exo)].

**Table 3 Dopaminergic imaging studies in patients with suspected drug-induced parkinsonism**

Study	Imaging modality	Clinical diagnosis	Key findings
Lorberboym <i>et al.</i> (2006)	[ <sup>123</sup> I]FP-CIT SPECT	DIP (neuroleptic) ( <i>n</i> = 20), controls ( <i>n</i> = 10)	Striatal [ <sup>123</sup> I]FP-CIT binding normal in nine patients (55%), significantly reduced versus controls in 11
Tinazzi <i>et al.</i> (2008)	[ <sup>123</sup> I]FP-CIT SPECT	Extrapyramidal symptoms on DRBAs ( <i>n</i> = 32), controls ( <i>n</i> = 26)	[ <sup>123</sup> I]FP-CIT SPECT binding normal in 18/32 (56%) and abnormal in 14/32 (44%)
Tinazzi <i>et al.</i> (2009)	[ <sup>123</sup> I]FP-CIT SPECT	Follow-up of Tinazzi <i>et al.</i> (2008). Ten normal baseline scan, nine abnormal	[ <sup>123</sup> I]FP-CIT SPECT binding results same as baseline (normal still normal, abnormal still abnormal)
Diaz-Corrales <i>et al.</i> (2010)	[ <sup>123</sup> I]FP-CIT SPECT	DIP ( <i>n</i> = 32), PDU ( <i>n</i> = 25), Parkinson's disease with no previous anti-dopaminergic therapy ( <i>n</i> = 22)	[ <sup>123</sup> I]FP-CIT image normal in 29 (90.6%) DIP and abnormal in 100% Parkinson's disease
Hambÿe <i>et al.</i> (2010)	[ <sup>123</sup> I]FP-CIT SPECT	Parkinsonism during amiodarone therapy ( <i>n</i> = 22)	11 normal, 11 abnormal [ <sup>123</sup> I]FP-CIT SPECT image. Modification of amiodarone in patients (5/11) with normal scan ameliorated or normalized parkinsonism. In patients with Parkinson's disease (abnormal scan), optimizing treatment had more impact than modifying amiodarone

DIP = drug-induced parkinsonism; DRBA = dopamine receptor blocking agent; PDU = Parkinson's disease unmasked by anti-dopaminergic drugs.

of presynaptic dopaminergic neurons before symptoms occur. These patients may have an intermediate scan i.e. one showing abnormal binding but not as low as is typical in Parkinson's disease. In such cases, although the patient may make a complete recovery after cessation of the offending drug, they will re-present with clinical features of idiopathic Parkinson's disease at a later date. Dopaminergic imaging can help to identify such patients, and therapy may be beneficial in these individuals (Table 3) (Lorberboym *et al.*, 2006; Tinazzi *et al.*, 2008, 2009; Hambÿe *et al.*, 2010).

### Psychogenic parkinsonism

Accurate and early diagnosis of psychogenic parkinsonism is important to enable appropriate treatment, avoid multiple unrevealing and potentially harmful diagnostic procedures and avoid inappropriate therapies (Lang *et al.*, 1995). Normal dopamine transporter imaging or [<sup>18</sup>F]DOPA PET or alternative dopaminergic functional scan supports a diagnosis of psychogenic parkinsonism, whereas an abnormal image indicates an underlying neurodegenerative disease and should lead to re-evaluation of the diagnosis (Benaderette *et al.*, 2006; Gaig *et al.*, 2006; Felicio *et al.*, 2010b). In the study by Gaig *et al.* (2006), one of the cases of suspected psychogenic Parkinson's disease had an abnormal scan; the parkin gene was subsequently identified in this patient.

### Post-traumatic parkinsonism

Post-traumatic parkinsonism is defined as a parkinsonian clinical syndrome that may occur after cumulative head trauma (e.g. contact sports) or, rarely, after an isolated head injury (Lees *et al.*, 1997). Post-traumatic parkinsonism may be difficult to distinguish clinically from Parkinson's disease when the role of the trauma or its temporal relationship to parkinsonism is uncertain. The role of dopamine transporter imaging in the diagnosis of post-traumatic parkinsonism remains to be determined. A small study of

[<sup>18</sup>F]DOPA PET in six patients with clinically diagnosed post-traumatic parkinsonism suggested uniform reduction in binding in the caudate and putamen (40% versus age-matched controls) in comparison with a greater reduction in binding in the putamen relative to the caudate in patients with Parkinson's disease (Turjanski *et al.*, 1997). Dopamine transporter imaging would be expected to be normal in these disorders unless the traumatic injury disrupted the nigrostriatal projection.

## Dementia with Lewy bodies and Parkinson's disease with dementia

DLB is thought to be the second most common form of degenerative dementia (after Alzheimer's disease) (Zaccai *et al.*, 2005). Estimates of its prevalence vary, ranging from 0–5% of the general population and 0–30.5% of all dementia cases (Zaccai *et al.*, 2005). DLB is distinguished from Parkinson's disease with dementia where dementia occurs within 1 year after the diagnosis of Parkinson's disease, while Parkinson's disease with dementia is dementia occurring in the context of well-established ( $\geq 1$  year) Parkinson's disease (McKeith *et al.*, 2005). The pathology of DLB includes Lewy bodies, amyloid plaques and deficiencies in numerous neurotransmitter systems including dopaminergic, cholinergic and serotonergic neurotransmission. The clinical syndrome is characterized by dementia with cognitive fluctuations, visual hallucinations and/or parkinsonism. DLB may occur in a pure form or with substantial Alzheimer's disease-type changes (Lewy body variant of Alzheimer's disease). Clinical diagnosis of DLB carries high specificity (>95%) but low sensitivity (32% for pure DLB and 12% for Alzheimer's disease plus DLB) in comparison with neuropathological findings (Nelson *et al.*, 2010). Correct diagnosis of DLB is necessary to establish an accurate



**Table 4 Dopaminergic imaging studies in patients with dementia**

Study	Imaging modality	Clinical diagnosis	Key findings
Hu <i>et al.</i> (2000)	[ <sup>18</sup> F]DOPA PET	DLB ( <i>n</i> = 7), Alzheimer's disease ( <i>n</i> = 10)	DLB distinguished from Alzheimer's disease with 86% sensitivity and 100% specificity
Ceravolo <i>et al.</i> (2004)	[ <sup>123</sup> I]FP-CIT SPECT	Alzheimer's disease with parkinsonism ( <i>n</i> = 13), DLB ( <i>n</i> = 15), Parkinson's disease ( <i>n</i> = 20), controls ( <i>n</i> = 8)	Striatal [ <sup>123</sup> I]FP-CIT binding similar in Alzheimer's disease with parkinsonism and controls; significantly lower in DLB and Parkinson's disease than Alzheimer's disease with parkinsonism and controls
Colloby <i>et al.</i> (2004)	[ <sup>123</sup> I]FP-CIT SPECT	Parkinson's disease ( <i>n</i> = 38), DLB ( <i>n</i> = 23), Alzheimer's disease ( <i>n</i> = 34), controls ( <i>n</i> = 33)	Significant reduction in striatal uptake DLB and Parkinson's disease versus Alzheimer's disease and controls, and Alzheimer's disease versus controls. Striatal binding indistinguishable between Parkinson's disease and DLB
Gilman <i>et al.</i> (2004)	[ <sup>11</sup> C]DTBZ	DLB ( <i>n</i> = 6 DLB/Parkinson's disease, <sup>a</sup> <i>n</i> = 14 DLB/Alzheimer's disease), Alzheimer's disease ( <i>n</i> = 25), controls ( <i>n</i> = 19)	Mean striatal binding decreased by 62–77% in DLB/Parkinson's disease and by 45–67% in DLB/Alzheimer's disease versus Alzheimer's disease and controls
O'Brien <i>et al.</i> (2004)	[ <sup>123</sup> I]FP-CIT SPECT	Alzheimer's disease ( <i>n</i> = 34), DLB ( <i>n</i> = 23), Parkinson's disease ( <i>n</i> = 38), PDD ( <i>n</i> = 36), controls ( <i>n</i> = 33)	Significantly reduced striatal binding in DLB versus Alzheimer's disease and controls. Similar extent of binding reduction in DLB and Parkinson's disease, but flatter rostrocaudal gradient. Greatest loss in PDD. DLB and Alzheimer's disease differentiated with 78% sensitivity and 94% specificity
Walker <i>et al.</i> (2002)	[ <sup>123</sup> I]FP-CIT SPECT	DLB ( <i>n</i> = 27), Alzheimer's disease ( <i>n</i> = 17), drug-naïve Parkinson's disease ( <i>n</i> = 19), controls ( <i>n</i> = 16)	DLB and Parkinson's disease significantly lower binding in caudate nucleus and putamen than controls
Walker <i>et al.</i> (2004)	[ <sup>123</sup> I]FP-CIT SPECT	DLB ( <i>n</i> = 21), Parkinson's disease ( <i>n</i> = 19), controls ( <i>n</i> = 16)	Significantly lower binding in all striatal areas in DLB and Parkinson's disease than controls. Binding in caudate nucleus significantly lower in DLB than Parkinson's disease. Caudate:putamen ratio Parkinson's disease higher than controls but not significantly different between DLB and controls
Colloby <i>et al.</i> (2005)	[ <sup>123</sup> I]FP-CIT SPECT	DLB ( <i>n</i> = 20), Parkinson's disease ( <i>n</i> = 20), PDD ( <i>n</i> = 15), controls ( <i>n</i> = 22)	Rates of decline in striatal binding similar in DLB, PDD and Parkinson's disease; differences between patients and controls seen in caudate, anterior putamen and posterior putamen
Hilker <i>et al.</i> (2005)	[ <sup>18</sup> F]DOPA PET	Parkinson's disease ( <i>n</i> = 17), PDD ( <i>n</i> = 10), controls ( <i>n</i> = 31)	Striatal [ <sup>18</sup> F]DOPA binding significantly decreased in Parkinson's disease and PDD with no difference between Parkinson's disease and PDD
Vaamonde-Gamo <i>et al.</i> (2005)	[ <sup>123</sup> I]FP-CIT SPECT	Parkinsonism and dementia ( <i>n</i> = 6)	Normal image in two patients, pathological in four
McKeith <i>et al.</i> (2007)	[ <sup>123</sup> I]FP-CIT SPECT	Probable DLB ( <i>n</i> = 94), possible DLB ( <i>n</i> = 57), non-DLB dementia ( <i>n</i> = 147)	[ <sup>123</sup> I]FP-CIT SPECT detected clinically probable DLB with 77.7% sensitivity and excluded non-DLB dementia with 90.4% specificity. Diagnostic accuracy 85.7%, positive predictive value 82.4%, negative predictive value 87.5%
Walker <i>et al.</i> (2007)	[ <sup>123</sup> I]FP-CIT SPECT	DLB ( <i>n</i> = 13), Alzheimer's disease ( <i>n</i> = 6), cortico-basal degeneration ( <i>n</i> = 1)	In comparison to autopsy diagnosis, [ <sup>123</sup> I]FP-CIT SPECT had 88% sensitivity and 100% specificity for DLB diagnosis; initial clinical diagnosis 75% sensitivity and 42% specificity
Colloby <i>et al.</i> (2008)	[ <sup>123</sup> I]FP-CIT SPECT	Alzheimer's disease ( <i>n</i> = 33), DLB ( <i>n</i> = 28), controls ( <i>n</i> = 33)	Clinical diagnosis and consensus [ <sup>123</sup> I]FP-CIT SPECT assessment matched in 84% of cases for Alzheimer's disease versus DLB. Sensitivity 78.6%, specificity 87.9% (ROC analysis); superior to [ <sup>99m</sup> Tc]exametazime SPECT
Koeppel <i>et al.</i> (2008)	[ <sup>11</sup> C]DTBZ PET	DLB ( <i>n</i> = 25), Parkinson's disease ( <i>n</i> = 30), Alzheimer's disease ( <i>n</i> = 25), controls ( <i>n</i> = 57)	Striatal binding significantly lower in DLB and Parkinson's disease than Alzheimer's disease and controls. Combining blood-to-brain ligand transport and presynaptic binding distribution volume classified 90% of cases correctly
Lim <i>et al.</i> (2009)	[ <sup>123</sup> I]β-CIT SPECT	DLB ( <i>n</i> = 14), Alzheimer's disease ( <i>n</i> = 1)	Four DLB and one Alzheimer's disease confirmed at autopsy. [ <sup>123</sup> I]β-CIT SPECT achieved 100% accuracy. More robust methodology than [ <sup>18</sup> F]FDG PET

(continued)

Table 4 Continued

Study	Imaging modality	Clinical diagnosis	Key findings
O'Brien <i>et al.</i> (2009)	[ <sup>123</sup> I]FP-CIT SPECT	Follow-up from McKeith <i>et al.</i> (2007). Possible DLB at baseline ( <i>n</i> = 44), changed to probable DLB in 19 and Alzheimer's disease in seven	In patients originally diagnosed with possible DLB, baseline scan diagnosed Alzheimer's disease with 100% specificity and probable DLB with 63% sensitivity
Rossi <i>et al.</i> (2009)	[ <sup>123</sup> I]FP-CIT SPECT	PDD ( <i>n</i> = 30), DLB ( <i>n</i> = 30)	Striatal [ <sup>123</sup> I]FP-CIT binding significantly lower in PDD and DLB than controls. No difference between PDD and DLB
Klein <i>et al.</i> (2010)	[ <sup>18</sup> F]DOPA PET	PDD ( <i>n</i> = 8), DLB ( <i>n</i> = 6), Parkinson's disease without dementia ( <i>n</i> = 9)	Reduced [ <sup>18</sup> F]DOPA uptake in all groups

<sup>a</sup>DLB/Parkinson's disease = patients in whom parkinsonism developed  $\geq$  1 year before dementia; DLB/Alzheimer's disease = patients developing dementia before or around the same time as parkinsonism.

DLB = dementia with Lewy bodies; DTBZ = dihydrotetabenazine; PDD = Parkinson's disease with dementia; ROC = receiver operating characteristic.

prognosis and likely clinical course, and can be extremely helpful for patients and their carers (Kemp and Holmes, 2007). Distinguishing between Alzheimer's disease and DLB is a major diagnostic challenge, but differentiation is important for several reasons. Therapy with typical antipsychotics for behavioural disturbances commonly associated with this dementia, because of D<sub>2</sub> receptor blockade in a patient with pre-existing nigrostriatal disease, will greatly exacerbate the parkinsonism in patients with DLB. Approximately 80% of patients with DLB show this neuroleptic sensitivity; the adverse reaction is severe in ~50% and associated with increased mortality (McKeith *et al.*, 1992). Differentiation of DLB from Alzheimer's disease also identifies patients with dementia likely to benefit from dopaminergic therapy and avoids unnecessary treatment in patients with Alzheimer's disease who are unlikely to benefit. Preliminary evidence suggests that patients with DLB benefit more from treatment with cholinesterase inhibitors than those with Alzheimer's disease (Samuel *et al.*, 2000). Finally, accurate diagnosis is important for patient/family counselling and is critical in recruitment for clinical trials of new therapies. Patients with DLB should be excluded from Alzheimer's disease trials and trials of agents being developed for DLB would benefit from a biomarker identifying the specific desired population.

DLB and Parkinson's disease with dementia have essentially identical pathology at time of autopsy, although patients with Parkinson's disease with dementia may have additional Alzheimer's and vascular pathology. Dementia is common in patients with Parkinson's disease, with an estimated point prevalence of 30% (Aarsland and Kurz, 2010). The cumulative incidence of dementia steadily increases with age and duration of Parkinson's disease and, conditional on survival, increases to 80–90% by 90 years of age (Buter *et al.*, 2008). At the age of 70 years, a male with Parkinson's disease but no dementia has a life expectancy of 8 years, of which five would be expected to be free of dementia and 3 years would be expected to be with dementia (Buter *et al.*, 2008). Females live with Parkinson's disease longer than males, and spend more years with dementia (Butler *et al.*, 2008). One long-term study of patients with Parkinson's disease demonstrated

that after 20 years of follow-up, 80% of survivors had dementia (Hely *et al.*, 2008).

Unlike Alzheimer's disease, DLB is characterized by severe nigrostriatal dopaminergic neurodegeneration (Piggott *et al.*, 1999), making dopaminergic imaging a potentially useful differential diagnostic tool. Dopamine transporter SPECT imaging can differentiate patients with either DLB or Parkinson's disease with dementia, who have abnormal imaging results, from those with Alzheimer's disease, who have normal tracer uptake (Table 4). The largest of these studies was a multicentre Phase III trial of [<sup>123</sup>I]FP-CIT SPECT in 326 patients with clinical consensus diagnoses of probable (*n* = 94) or possible (*n* = 57) DLB or non-DLB dementia (*n* = 147) (McKeith *et al.*, 2007). Images were rated as normal or abnormal by visual inspection by three readers blinded to the clinical diagnoses. Mean sensitivity of [<sup>123</sup>I]FP-CIT SPECT imaging for a clinical diagnosis of probable DLB was 77.7%, while the mean specificity for excluding non-DLB dementia (which was predominantly due to Alzheimer's disease) was 90.4%, giving overall diagnostic accuracy of 85.7%. Follow-up consensus clinical diagnosis at 12 months, when diagnosis had become clearer in nearly 60% of patients, confirmed the ability of [<sup>123</sup>I]FP-CIT SPECT imaging to discriminate DLB from non-DLB dementia (O'Brien *et al.*, 2009). Of 44 patients with a clinical diagnosis of possible DLB at baseline, the diagnosis at follow-up remained as possible DLB in 18 but was changed to probable DLB in 19, 12 of whom had abnormal scans at baseline and to non-DLB dementia in seven, all of whom had normal baseline scans. These results suggest that [<sup>123</sup>I]FP-CIT SPECT imaging is likely to be of diagnostic value in clinically uncertain DLB cases. Imaging with the vesicular monoamine transporter PET tracer [<sup>11</sup>C]dihydrotetabenazine has also shown potential utility in discriminating DLB and Alzheimer's disease (Gilman *et al.*, 2004). Dopaminergic imaging cannot distinguish DLB from Parkinson's disease with dementia, as both are associated with presynaptic dopaminergic deficiency, and thus the scans will be abnormal in both cases.

[<sup>123</sup>I]FP-CIT SPECT imaging has demonstrated higher sensitivity and specificity for differentiating DLB from non-DLB than clinical

diagnosis in a series of 20 patients who had post-mortem brain examination (Walker *et al.*, 2007). In this prospective study, against gold standard autopsy diagnosis, sensitivity of an initial clinical diagnosis of DLB was 75% and specificity was 42%, in comparison with 88% sensitivity and 100% specificity with [<sup>123</sup>I]FP-CIT SPECT imaging.

Approximately 5–10% of [<sup>123</sup>I]FP-CIT SPECT studies in patients with clinical dementia have intermediate scans, i.e. between Alzheimer's disease and DLB, showing abnormal binding but not as low as is usual in DLB (Kemp and Holmes, 2007). Such intermediate images may represent mixed DLB/Alzheimer's disease or DLB/vascular disease in which DLB pathology at clinical presentation is less than in patients with pure DLB. Depending on the criteria used, 30–60% of patients with clinically diagnosed Alzheimer's disease may fulfil histological criteria for both DLB and Alzheimer's disease (Kemp and Holmes, 2007). Furthermore, in autopsy-proven DLB, concomitant Alzheimer's disease pathology has an important influence on clinical characteristics, such that patients with mixed DLB/Alzheimer's disease pathology have a lower prevalence of core DLB symptoms than those with pure DLB and show a pattern of clinical and behavioural change more typical of Alzheimer's disease than DLB (Merdes *et al.*, 2003).

DLB typically exhibits a preponderance of brainstem over limbic and neocortical Lewy body pathology. Pathological examination of brains from a population-based brain donor cohort has indicated that in 8% of brains with Lewy bodies the pathology was confined to the cortex with little or no involvement of the substantia nigra (Zaccai *et al.*, 2008). The donors were a mixture of healthy subjects and individuals with dementia and, unfortunately, the histological findings in this study were not compared against the clinical syndrome. This situation could, however, theoretically give rise to a false negative dopamine transporter imaging scan in patients presenting with the cortical form of DLB.

Low dopamine transporter uptake in the basal ganglia demonstrated by SPECT or PET imaging has been included as a suggestive feature in the most recent diagnostic criteria for DLB (McKeith *et al.*, 2005). One suggestive feature plus one core feature is sufficient to allow a diagnosis of probable DLB. Dopaminergic imaging identifies dopaminergic deficit, and the reliability with which DLB is identified will depend on the population of patients tested; false positives would occur in patients with other forms of parkinsonism with dementia (e.g. corticobasal degeneration and progressive supranuclear palsy), emphasizing the need for detailed clinical assessment.

Noradrenergic post-ganglionic cardiac sympathetic denervation is a common feature of Parkinson's disease and related Lewy body disorders. [<sup>123</sup>I]Meta-iodobenzylguanidine cardiac scintigraphy, which visualizes catecholaminergic (noradrenergic) terminals, may be useful in the diagnosis of Lewy body disease and its differentiation from Alzheimer's disease and other types of dementia (Hanyu *et al.*, 2006). In addition, patterns of [<sup>18</sup>F]fluorodeoxyglucose PET (Mosconi *et al.*, 2008) and amyloid imaging (Rowe *et al.*, 2007; Gomperts *et al.*, 2008) may differ between Alzheimer's disease and DLB.

## Atypical parkinsonism

The most common atypical parkinsonism syndromes comprise multiple system atrophy, corticobasal degeneration and progressive supranuclear palsy. Multiple system atrophy is a sporadic, progressive neurodegenerative disease characterized by varying severity of parkinsonian features, cerebellar ataxia, autonomic failure and corticospinal disorders (Gilman *et al.*, 2008). Multiple system atrophy is categorized as one of two types, multiple system atrophy with predominant parkinsonism, where parkinsonian symptoms predominate, and multiple system atrophy with cerebellar features, where cerebellar ataxia predominates (Gilman *et al.*, 2008). Corticobasal syndrome is characterized by the phenotype of apraxia, asymmetrical parkinsonism and cognitive dysfunction. Clinical diagnosis is complicated by both the variability of presentation of the true disease (corticobasal degeneration), and the similarity of syndromes that resemble it but are caused by other neurodegenerative diseases (Mahapatra *et al.*, 2004). Progressive supranuclear palsy is the second most common cause of parkinsonism after Parkinson's disease (Lubarsky and Juncos, 2008), and presents with early onset postural instability associated with supranuclear vertical gaze impairment as well as symmetrical rather than asymmetrical akinetic-rigid syndrome together with prominent bulbar dysfunction, dementia and axial rigidity (Brooks 2002).

These atypical parkinsonian syndromes can be difficult to differentiate clinically from each other and from Parkinson's disease, especially in early stages (Litvan *et al.*, 2003). Correct differentiation is important as Parkinson's disease has a better prognosis than atypical parkinsonism syndromes and responds better to symptomatic treatment (Adbo *et al.*, 2006). Dopamine transporter imaging is not helpful in the differential diagnosis of atypical parkinsonism (Varrone *et al.*, 2001) as all these syndromes are associated with presynaptic dopaminergic deficiency. Although there are group differences in the pattern of nigrostriatal degeneration revealed by dopamine transporter imaging between patients with Parkinson's disease and atypical parkinsonism (Table 5), dopamine transporter imaging has not been shown to improve diagnostic accuracy in individual cases. In a proportion of cases with corticobasal syndrome, however, there may be a unilateral reduction in dopaminergic function that could be a useful, albeit subtle, sign suggestive of the corticobasal syndrome (Sawle *et al.*, 1991).

Postsynaptic D<sub>2</sub> receptor imaging may be useful in differentiating Parkinson's disease from atypical parkinsonism. Patients with Parkinson's disease usually show normal or upregulated postsynaptic D<sub>2</sub> receptor binding in the early stages, while atypical forms are associated with reduced binding as a reflection of the postsynaptic as well as presynaptic dopaminergic degeneration (Antonini *et al.*, 1997; Schreckenberger *et al.*, 2004). A PET study using [<sup>18</sup>F]desmethoxyfallypride (a post synaptic D<sub>2</sub> receptor ligand) in 16 patients with Parkinson's disease, 19 with atypical parkinsonism and 16 controls showed specificity, sensitivity and accuracy of 100, 74 and 86%, respectively (Schreckenberger *et al.*, 2004). Sensitivity and specificity of 68.4 and 57.1%, respectively, have been reported for [<sup>123</sup>I]iodobenzamide SPECT in the differential diagnosis of Parkinson's disease versus atypical

**Table 5 Dopaminergic imaging studies in patients with atypical parkinsonism**

Study	Imaging modality	Clinical diagnosis	Key findings
Brooks <i>et al.</i> (1990)	[ <sup>18</sup> F]DOPA PET	Parkinson's disease ( <i>n</i> = 16), multiple system atrophy ( <i>n</i> = 18), PSP ( <i>n</i> = 10), controls ( <i>n</i> = 30)	Parkinson's disease, significantly reduced [ <sup>18</sup> F]DOPA uptake in caudate and putamen versus controls, particularly in posterior putamen; PSP, equally severe impairment in anterior and posterior putamen; multiple system atrophy, binding in anterior putamen and caudate intermediate between Parkinson's disease and multiple system atrophy
Otsuka <i>et al.</i> (1991)	[ <sup>18</sup> F]DOPA PET	Parkinson's disease ( <i>n</i> = 8), atypical parkinsonism ( <i>n</i> = 8)	[ <sup>18</sup> F]DOPA significantly lower in putamen in Parkinson's disease and atypical parkinsonism than controls; also lower than controls in caudate, but more so in atypical parkinsonism than Parkinson's disease
Brooks <i>et al.</i> (1992)	[ <sup>11</sup> C]Raclopride PET	Parkinson's disease untreated ( <i>n</i> = 6), chronically treated Parkinson's disease ( <i>n</i> = 5), striatonigral degeneration ( <i>n</i> = 10), PSP ( <i>n</i> = 9)	Striatal [ <sup>11</sup> C]raclopride uptake normal or increased in untreated Parkinson's disease, reduced in chronically treated Parkinson's disease (by 30% caudate, 18% putamen) and PSP (by 24% caudate, 9% putamen)
Burn <i>et al.</i> (1994)	[ <sup>18</sup> F]DOPA PET	Probable Parkinson's disease ( <i>n</i> = 28), multiple system atrophy ( <i>n</i> = 25), PSP ( <i>n</i> = 10), controls ( <i>n</i> = 27)	Clinical diagnosis matched PET criteria in 64% of patients with Parkinson's disease and 70% of patients with PSP; patients with multiple system atrophy assigned to Parkinson's disease, multiple system atrophy and PSP with equal frequency by PET criteria
Antonini <i>et al.</i> (1997)	[ <sup>11</sup> C]Raclopride and [ <sup>18</sup> F]DOPA PET	Parkinson's disease ( <i>n</i> = 10), multiple system atrophy ( <i>n</i> = 9), controls ( <i>n</i> = 2 × 10)	Striatal [ <sup>18</sup> F]DOPA binding separated patients with Parkinson's disease and multiple system atrophy from controls, but did not distinguish multiple system atrophy from Parkinson's disease. [ <sup>11</sup> C]Raclopride binding differentiated all multiple system atrophy cases from Parkinson's disease and controls
Brücke <i>et al.</i> (1997)	[ <sup>123</sup> I]β-CIT SPECT	Parkinson's disease ( <i>n</i> = 113), multiple system atrophy ( <i>n</i> = 9), PSP ( <i>n</i> = 4)	45% reduction in striatal [ <sup>123</sup> I]β-CIT binding in Parkinson's disease, with sparing of caudate relative to putamen; similar findings in multiple system atrophy and PSP, but less marked difference between caudate and putamen
Pirker <i>et al.</i> (2000)	[ <sup>123</sup> I]β-CIT SPECT	Multiple system atrophy ( <i>n</i> = 18), PSP ( <i>n</i> = 8), corticobasal degeneration ( <i>n</i> = 4), Parkinson's disease ( <i>n</i> = 48), controls ( <i>n</i> = 14)	Striatal binding significantly reduced in multiple system atrophy (–51%), PSP (–60%), corticobasal degeneration (–35%) and Parkinson's disease (–58%) versus controls; no differentiation between disorders
Prunier <i>et al.</i> (2001)	[ <sup>123</sup> I]Iodosiluride (D <sub>2</sub> ligand) SPECT	Parkinson's disease ( <i>n</i> = 9), Parkinson-plus syndromes ( <i>n</i> = 8)	Differentiated Parkinson's disease from Parkinson-plus syndromes versus 2 year clinical diagnosis with 89% sensitivity and 75% specificity
Varrone <i>et al.</i> (2001)	[ <sup>123</sup> I]β-CIT SPECT	Parkinson's disease ( <i>n</i> = 157), multiple system atrophy ( <i>n</i> = 26)	Striatal [ <sup>123</sup> I]β-CIT binding significantly reduced in Parkinson's disease and multiple system atrophy. More symmetrical loss in multiple system atrophy than Parkinson's disease
Arnold <i>et al.</i> (2002)	[ <sup>123</sup> I]iodobenzamide	PSP/probable PSP ( <i>n</i> = 13)	Striatal D <sub>2</sub> receptor binding normal in three, reduced in 10
Ghaemi <i>et al.</i> (2002)	[ <sup>18</sup> F]DOPA and [ <sup>11</sup> C]Raclopride	Parkinson's disease ( <i>n</i> = 24), multiple system atrophy ( <i>n</i> = 9), controls ( <i>n</i> = 7)	[ <sup>18</sup> F]DOPA binding equally impaired versus controls in multiple system atrophy and Parkinson's disease; [ <sup>11</sup> C]raclopride significantly different from multiple system atrophy versus Parkinson's disease
Kim <i>et al.</i> (2002)	[ <sup>123</sup> I]β-CIT and [ <sup>123</sup> I]IBF (D <sub>2</sub> receptor ligand)	Parkinson's disease ( <i>n</i> = 18, 12 dopa-naïve), multiple system atrophy ( <i>n</i> = 7), PSP ( <i>n</i> = 6), controls ( <i>n</i> = 29)	[ <sup>123</sup> I]β-CIT binding decreased in all patients versus controls, but did not distinguish between patient groups. D <sub>2</sub> receptor binding in posterior putamen significantly lower (71%) in multiple system atrophy than controls, and significantly higher (33%) in untreated Parkinson's disease than controls
Oyanagi <i>et al.</i> (2002)	[ <sup>123</sup> I]IBF (D <sub>2</sub> ligand) SPECT	Parkinson's disease ( <i>n</i> = 7), PSP ( <i>n</i> = 6), controls ( <i>n</i> = 8)	Significantly lower D <sub>2</sub> receptor binding potential in PSP than Parkinson's disease and controls; no difference between Parkinson's disease and controls

(continued)

Table 5 Continued

Study	Imaging modality	Clinical diagnosis	Key findings
Pirker <i>et al.</i> (2002)	[ <sup>123</sup> I]β-CIT SPECT	Parkinson's disease short duration ( <i>n</i> = 24), Parkinson's disease long duration ( <i>n</i> = 12), atypical parkinsonism ( <i>n</i> = 10), controls ( <i>n</i> = 30)	Striatal [ <sup>123</sup> I]β-CIT binding reduced versus controls in all groups (by 42% parkinson's disease short duration, 51% Parkinson's disease long duration, 36% atypical parkinsonism). Over mean of 25.5 months, significant decrease in binding in atypical parkinsonism (14.9%/year) and short duration Parkinson's disease (7.1%), no change in long duration Parkinson's disease
Antonini <i>et al.</i> (2003)	[ <sup>123</sup> I]FP-CIT SPECT	Parkinson's disease ( <i>n</i> = 70), multiple system atrophy ( <i>n</i> = 10), PSP ( <i>n</i> = 10), controls ( <i>n</i> = 12)	Striatal [ <sup>123</sup> I]FP-CIT binding reduced in Parkinson's disease, multiple system atrophy and PSP versus controls; greater decrease in PSP than multiple system atrophy and Parkinson's disease, with more uniform reduction in PSP than Parkinson's disease
Berding <i>et al.</i> (2003)	[ <sup>123</sup> I]β-CIT SPECT	Parkinson's disease ( <i>n</i> = 14), multiple system atrophy ( <i>n</i> = 10), controls ( <i>n</i> = 20)	Bilateral striatal binding reduced 63–70% in Parkinson's disease, 40–48% in multiple system atrophy; least reduction in caudate ipsilateral to more affected side in Parkinson's disease, contralateral in multiple system atrophy
Knudsen <i>et al.</i> (2004)	[ <sup>123</sup> I]β-CIT SPECT and [ <sup>123</sup> I]epidepride (D <sub>2</sub> ligand)	Parkinson's disease ( <i>n</i> = 14), multiple system atrophy ( <i>n</i> = 8), controls ( <i>n</i> = 11)	Putamen [ <sup>123</sup> I]β-CIT binding 32% controls in Parkinson's disease and 19% controls in multiple system atrophy; multiple system atrophy more symmetrical binding than Parkinson's disease. Non-significant difference in D <sub>2</sub> binding in multiple system atrophy or Parkinson's disease versus controls
Lu <i>et al.</i> (2004)	[ <sup>99m</sup> Tc]TRODAT-1 SPECT	Probable multiple system atrophy ( <i>n</i> = 49, 30 multiple system atrophy with predominant parkinsonism, 19 cerebellar multiple system atrophy), probable Parkinson's disease ( <i>n</i> = 36), controls ( <i>n</i> = 33)	Striatal binding significantly reduced in multiple system atrophy with predominant parkinsonism (–59.8%), cerebellar multiple system atrophy (–29.9%) and Parkinson's disease (–58%) versus controls, with no overlap between groups. More symmetrical nigrostriatal damage in multiple system atrophy with predominant parkinsonism than Parkinson's disease
Schreckenberger <i>et al.</i> (2004)	[ <sup>18</sup> F]DMFP	Parkinson's disease ( <i>n</i> = 16), atypical parkinsonism ( <i>n</i> = 19), controls ( <i>n</i> = 16)	Striatal [ <sup>18</sup> F]DMFP uptake ratio significantly lower in atypical parkinsonism than controls and Parkinson's disease; no difference between controls and Parkinson's disease
Plotkin <i>et al.</i> (2005)	[ <sup>123</sup> I]FP-CIT and [ <sup>123</sup> I]iodobenzamide SPECT	Parkinson's disease ( <i>n</i> = 25), dementia with Lewy bodies ( <i>n</i> = 6), multiple system atrophy ( <i>n</i> = 13), PSP ( <i>n</i> = 8), corticobasal degeneration ( <i>n</i> = 9), essential tremor ( <i>n</i> = 11)	All patients with essential tremor had normal [ <sup>123</sup> I]FP-CIT binding; reduced binding in 57/61 (93.4%) patients with non-essential tremor. [ <sup>123</sup> I]iodobenzamide binding reduced in 7/13 multiple system atrophy, 6/8 PSP, 2/9 corticobasal degeneration and none with essential tremor, Parkinson's disease or dementia with Lewy bodies
Scherfler <i>et al.</i> (2005)	[ <sup>123</sup> I]β-CIT SPECT	Multiple system atrophy with predominant parkinsonism ( <i>n</i> = 15), Parkinson's disease ( <i>n</i> = 15), controls ( <i>n</i> = 13)	Caudate and midbrain binding indices correctly classified 95.2% of subjects
Stoffers <i>et al.</i> (2005)	[ <sup>123</sup> I]β-CIT SPECT	Parkinson's disease ( <i>n</i> = 72), with diagnosis changed to atypical parkinsonism in 10 over 62 months follow-up	Baseline [ <sup>123</sup> I]β-CIT binding lower in caudate in atypical parkinsonism than Parkinson's disease; putamen: caudate binding ratios higher in atypical parkinsonism. Binding patterns have little predictive value for later re-diagnosis of atypical parkinsonism in individual cases
Swanson <i>et al.</i> (2005)	[ <sup>99m</sup> Tc]TRODAT-1 SPECT	Multiple system atrophy ( <i>n</i> = 25), controls ( <i>n</i> = 48), Parkinson's disease ( <i>n</i> = 130)	[ <sup>99m</sup> Tc]TRODAT-1 binding significantly higher in multiple system atrophy, particularly in posterior putamen, than in Parkinson's disease, and lower than in controls. Multiple system atrophy and Parkinson's disease differentiated from controls, but not easily differentiated from each other
El Fakhri <i>et al.</i> (2006)	[ <sup>99m</sup> Tc]ECD/[ <sup>123</sup> I]FP-CIT SPECT	Parkinson's disease ( <i>n</i> = 5), multiple system atrophy ( <i>n</i> = 5), controls ( <i>n</i> = 9)	Striatal binding lower in Parkinson's disease (55%) and multiple system atrophy (23%) than controls; significantly lower in Parkinson's disease than multiple system atrophy

(continued)

Table 5 Continued

Study	Imaging modality	Clinical diagnosis	Key findings
Pifarré <i>et al.</i> (2010)	[ <sup>123</sup> I]iodobenzamide SPECT	Parkinsonism ( <i>n</i> = 26)	16/26 abnormal binding. Differential diagnosis of Parkinson's disease versus atypical parkinsonism 68.4% sensitivity, 57.1% specificity
Van Laere <i>et al.</i> (2010)	[ <sup>11</sup> C]Raclopride PET, combined binding and influx analysis	Multiple system atrophy with predominant parkinsonism ( <i>n</i> = 9), Parkinson's disease ( <i>n</i> = 10), controls ( <i>n</i> = 10)	Conventional binding analysis correctly classified 19/29 individuals (65.5%). Combined binding and influx analysis increased accuracy to 79.3%. Excluding controls, combination analysis discriminated multiple system atrophy with predominant parkinsonism and Parkinson's disease with 100% accuracy

DMFP = desmethoxyfallypride; ECD = ethylcysteinate dimer; IBF = iodobenzofuran; PSP = progressive supranuclear palsy; Tc = technetium; TRODAT-1 = [2-[[[3-(4-chlorophenyl)-8-methyl-8-azabicyclo[3.2.1]oct-2-yl]methyl](2-mercaptoethyl)amino]ethyl]amino]ethanethiolato(3-)-N2,N20,S2,S20]oxo-[1R-(exo-exo)].

parkinsonism (Pifarré *et al.*, 2010). A limitation of D<sub>2</sub> receptor imaging in this clinical situation is that, after the initial upregulation in Parkinson's disease, the D<sub>2</sub> receptors are downregulated (likely due to both dopaminergic treatment and the intrinsic disease process) (Thobois *et al.*, 2004) and therefore the images mimic those of the atypical syndromes later in the disease process. It may therefore be helpful in such cases to combine D<sub>2</sub> receptor imaging with fluorodeoxyglucose-PET (Tang *et al.*, 2010).

Patients with Parkinson's disease show a marked reduction in cardiac [<sup>123</sup>I]meta-iodobenzylguanidine uptake, in comparison with modest reductions in uptake in multiple system atrophy, progressive supranuclear palsy and corticobasal degeneration, such that meta-iodobenzylguanidine cardiac scintigraphy is moderately sensitive and specific in differentiating Parkinson's disease from atypical parkinsonism (Rascol and Schelosky, 2009). Meta-analysis has suggested [<sup>123</sup>I]meta-iodobenzylguanidine cardiac scintigraphy identifies patients with Parkinson's disease with 89.7% sensitivity and discriminates them from patients with multiple system atrophy with 94.6% specificity (Braune, 2001).

## Potential effects of drugs on dopaminergic imaging

Anti-parkinsonian medications (levodopa, dopamine agonists, N-methyl-D-aspartate receptor blockers, monoamine oxidase-B inhibitors and catechol-O-methyltransferase inhibitors), taken at standard doses, do not markedly affect dopamine transporter binding and therefore need not be withdrawn before dopaminergic imaging (Schillaci *et al.*, 2005; Darcourt *et al.*, 2010). However, there are a range of medications and drugs of abuse, including cocaine, amphetamines, modafinil, certain anti-depressants (mazindol, bupropion, radafaxine), adrenergic agents (phenylephrine, norepinephrine) and the anti-cholinergic agent benztropine, that may influence the visual and quantitative analysis of dopamine transporter ligands (Booij and Kemp, 2008; Darcourt *et al.*, 2010). Patients should ideally avoid taking any such agents before dopaminergic imaging, with a withdrawal period of at least five times the drug's biological half-life recommended (Darcourt *et al.*, 2010). Any decision to withdraw

medication should balance the potential risks of such withdrawal against the potential benefits of imaging (Booij and Kemp, 2008).

## Quantitative techniques in dopaminergic imaging

Visual assessment of images may be subject to inter- and intra-reader variability and subjectivity. Region of interest analysis provides a semi-quantitative measure termed the background-subtracted striatal uptake ratio for a ligand (V3'' index). To obtain the V3'' index, regions of interest are outlined in the striatum representing the compartment of specific and non-specific ligand uptake and a reference region with absent or low dopamine transporter density (e.g. occipital cortex, cerebellum) representing the non-specific ligand binding compartment (Scherfler and Nocker, 2009). If possible, delineation of the region of interest should be made with reference to individual morphology as obtained by image fusion with MRI. The V3'' index so obtained from an individual can be compared with reference values from an age-matched cohort of healthy individuals, increasing confidence in the correct assignment of the individual scan.

Visual assessment and semi-quantitative analysis using region of interest techniques give similar diagnostic performance, perhaps because experienced observers are able to identify subtle patterns of abnormality (Scherfler and Nocker, 2009). Quantification of striatal tracer uptake relative to background may be affected by certain medications (amphetamines and stimulants such as ephedrine; modafinil; some anti-depressants such as bupropion; anti-cholinergics such as benztropine; fentanyl) and substances of abuse [cocaine; 1-(1-phenylcyclohexyl)piperidine] despite having no significant effect on visual interpretation; this should be borne in mind when applying quantitative techniques (Booij and Kemp, 2008).

Reader-independent image-analysis techniques may in the future provide more reproducible results and the type of objective assessments that would be useful in assessing disease progression and allow use in multicentre studies. This may be achieved by registering an individual patient image against a template of images from healthy controls with previously identified regions of interest. Image processing programs analyse the images in

two or three dimensions against the normal image template. Such methods show high correlation with manual region of interest analysis and visual diagnoses and, in addition to removing inter- and intra-reader variability, save time (Scherfler and Nocker, 2009). At present, however, there are insufficient data from any of the available SPECT ligands to support their use in monitoring disease progression or the effects of treatment. In addition, quantitation is complicated by potential effects of treatment on expression of radioligand targets (dopamine transporter, D<sub>2</sub> receptor).

## Imaging the premotor stage of Parkinson's disease

At the point at which motor symptoms are evident in patients with Parkinson's disease, up to 60% of dopaminergic neuronal markers have already been lost (Marek and Jennings, 2009). There is an evolving concept of premotor Parkinson's disease manifested by a constellation of clinical features that appear to be associated with increased risk of development of Parkinson's disease (Tolosa *et al.*, 2007*b*). Such features include rapid eye movement sleep behaviour disorder (Postuma *et al.*, 2009), olfactory loss (Ponsen *et al.*, 2004), late age onset anxiety and depression (Shiba *et al.*, 2000) and somnolence (Abbott *et al.*, 2005). While none of these symptoms carries sufficient sensitivity to be used for screening, they may, in conjunction with dopamine transporter imaging, potentially identify a population at risk.

During the premotor period, which is thought to last for at least five and possibly as long as 20 years (Marek and Jennings 2009), individuals at risk might therefore be identified by genetic testing, imaging evidence of neurodegeneration, or early clinical signs such as olfactory loss or cardiac sympathetic denervation. The challenge is how to identify and focus on individuals at risk but without symptoms. Combining dopaminergic imaging with screening for the premotor signs of disease such as olfactory loss or rapid eye movement sleep behaviour disorder improves identification of premotor Parkinson's disease (Stiasny-Kolster *et al.*, 2005; Berendse and Ponsen, 2009). Pathology outside the substantia nigra, for example in the gastrointestinal tract, heart, kidneys and skin may be evident before involvement of the CNS (Djaldetti *et al.*, 2009). Identification of individuals with premotor Parkinson's disease raises the potential for rational strategies for early symptomatic and neuroprotective therapy once such therapies become available.

Imaging studies in family members of patients affected by 'genetic' Parkinson's disease are helping to characterize the premotor phase. Several studies have suggested that dopaminergic imaging is abnormal in clinically unaffected mutation carriers (Khan *et al.*, 2002; Adams *et al.*, 2005; Pavese *et al.*, 2009*a*). [<sup>18</sup>F]DOPA imaging reveals that subclinical dopamine transporter reductions are common in carriers of a single parkin mutation, but progression of neurodegeneration is substantially slower than in Parkinson's disease, such that few of these individuals will go on to develop clinical parkinsonism (Pavese *et al.*, 2009*a*). The Parkinson-Associated Risk Syndrome study is investigating premotor Parkinson's disease in a large cohort of individuals without motor symptoms at increased risk of Parkinson's disease (first-degree relatives of

patients with Parkinson's disease) using a combination of olfactory testing and [<sup>123</sup>I]β-CIT SPECT imaging (Marek and Jennings, 2009). The progression of clinical, olfactory and imaging deficits in those identified as having reduced dopamine transporter density coupled with loss of olfaction will be monitored over 2 years. The long-term goal of this study is to define a reliable and economically feasible population screening panel for identification of subjects at risk of Parkinson's disease. Combination of low cost olfactory testing with the higher cost dopamine transporter imaging for subjects with an abnormal olfaction test might fulfil that requirement.

Large-scale screening for premotor Parkinson's disease will be most justified when safe and effective neuroprotective therapies targeting the pathogenetic processes underlying Parkinson's disease are available.

## Dopaminergic imaging in clinical trials

Dopamine system imaging has two potential uses in clinical studies, as an inclusion criterion and as a means of monitoring outcome, for example in disease-modifying trials. Neuroprotective strategies are most likely to be beneficial in the early stages of disease, when disease is least advanced but clinical diagnosis is more uncertain. As discussed above, imaging shows no evidence of dopaminergic deficit in ~10–15% of patients with clinically diagnosed early Parkinson's disease. Inclusion/exclusion of scans without evidence of dopaminergic deficit has been shown to alter the statistical significance of effect of therapy on striatal [<sup>123</sup>I]β-CIT binding (Fahn *et al.*, 2004). If such scans without evidence of dopaminergic deficit indeed represent patient misdiagnosis, these individuals should be excluded from clinical trials. Using dopamine transporter or other dopaminergic imaging providing evidence of neurodegeneration as an inclusion criterion for a clinical trial could provide a more uniform study population with a lower proportion of misdiagnosed patients, thus improving the power of the trial to detect any putative neuroprotective effect. The first large-scale study designed to explore biomarkers of Parkinson's disease progression, the Parkinson's Progression Markers Initiative, will recruit 400 patients with early Parkinson's disease and 200 age-matched healthy controls, all of whom will undergo baseline dopamine transporter imaging as the confirmation of the diagnosis of parkinsonism (Anon, 2010).

Large clinical trials have explored the utility of imaging outcomes for assessing the effects of potentially neuroprotective or neurotoxic agents, but demonstrate some of the challenges in using this technology as a biomarker of disease progression. In the Earlier versus Later Levodopa Therapy in Parkinson Disease (ELLDOPA) study, intended to assess the effect of levodopa on the rate of progression in Parkinson's disease, mean percentage decline in striatal [<sup>123</sup>I]β-CIT uptake was significantly higher in patients treated with levodopa than in those given placebo, consistent with a neurotoxic effect, but clinical data suggested that levodopa therapy either slowed the progression of Parkinson's disease or had a prolonged effect on the symptoms of the disease (Fahn *et al.*, 2004). This inconsistency could result from a direct pharmacological effect of levodopa on dopamine transporter, such that the decline in striatal [<sup>123</sup>I]β-CIT uptake resulted from

reduced expression of dopamine transporter induced by levodopa rather than from a neurotoxic degenerative effect of levodopa on striatal neurons (Pavese *et al.*, 2009b). The conclusion, if this were the case, would be that levodopa does not increase degeneration of striatal neurons. Most studies, however, suggest long-term levodopa therapy has no effect on striatal dopamine transporter levels (Pavese *et al.*, 2009b). Alternatively, the discrepancy between the clinical and imaging results could have resulted from an intermediate-term effect of levodopa on disease symptoms persisting after treatment withdrawal. The possibility of symptomatic effects of levodopa more prolonged than predicted in this study design make it possible that the washout period (of 2 weeks) was not sufficient, and that any effect of levodopa on disease progression could have been masked by its symptomatic properties (Pavese *et al.*, 2009b). If this were the case, it would remain possible that levodopa is neurotoxic. Other trials have used [ $^{123}$ I] $\beta$ -CIT SPECT [comparison of the agonist pramipexole with levodopa on motor complications of Parkinson's disease (CALM-Parkinson's disease)]; Parkinson Study Group, 2002 or [ $^{18}$ F]DOPA PET [ReQuip as Early Therapy versus L-dopa—PET (REAL-PET); Whone *et al.*, 2003] imaging to compare potential neuroprotective benefits of the dopamine receptor agonists pramipexole or ropinirole, respectively, with levodopa. Both trials showed a significantly lower decline in SPECT or PET imaging signal with dopamine agonist than with levodopa, suggesting a lower rate of disease progression. However, the clinical outcomes pointed in the opposite direction, with greater improvement from baseline in Unified Parkinson Disease Rating Scale in the levodopa subgroups (Parkinson Study Group, 2000; Whone *et al.*, 2003; Brooks, 2004). The lack of a control group in CALM-Parkinson's disease and REAL-PET complicates interpretation of the results. Another critique of studies with a design such as these is the lack of knowledge regarding the effect of levodopa or dopamine agonists on the binding of the nuclear ligand. In a study designed to address concerns that the treatments may have a pharmacological effect on dopamine transporter (InSPECT), short-term treatment (12 weeks) with levodopa or pramipexole was found to have no significant effect on dopamine transporter SPECT imaging (Jennings *et al.*, 2007).

As these studies have demonstrated, clinical trials of neuroprotection in neurodegenerative diseases present several challenges, including symptomatic effects of agents that may mask neuroprotective effects and the need for very large numbers of patients to achieve adequate statistical power (Clarke, 2004). *In vivo* imaging has potential as an objective measure to monitor neuronal degeneration independent of any short-term symptomatic effects of a drug, but if neuroimaging is to be used, the possibility of an effect of the therapy on handling of the tracer must be eliminated. Serial imaging studies have suggested therapeutic dosing of dopaminergic agents in patients with Parkinson's disease does not alter dopamine transporter levels, but the possibility remains that clinically relevant dopaminergic treatments or other therapies modify dopamine transporter expression over the longer term (Seibyl *et al.*, 2005b). In addition, if an imaging study attempts to evaluate the effect of a neuroprotective effect over time, the imaging technique must demonstrate extremely robust reliability and high accuracy in quantitation. A neuroprotective effect is likely to result

in only a small slowing in the rate of signal loss relative to untreated patients (Seibyl *et al.*, 2005b). Thus any clinical trial would need to have low variance in the quantitative imaging outcome measure, coupled with superior trial design and execution, adequate patient numbers and sufficient duration between baseline and post-intervention imaging.

## Limitations of studies reviewed

The majority of the studies reviewed here have one major limitation, using clinical diagnosis as the gold standard against which to assess sensitivity and specificity of imaging. While it is recognized that definitive diagnosis requires pathological confirmation, such an approach is not feasible for most studies. Despite this limitation, however, the research indicates that dopaminergic imaging, particularly dopamine transporter imaging, is an effective tool in the identification of diseases involving presynaptic dopaminergic system neurodegeneration.

## Conclusions

Accurate clinical diagnosis of a specific syndrome in patients with symptoms of parkinsonism may be challenging, especially early in the course of disease, owing to overlap in signs and symptoms. Accuracy of diagnosis improves with longer disease duration and increased clinical information (Seibyl *et al.*, 2005a). However, an early and accurate diagnosis is desirable as it improves management, particularly since early intervention may lead to superior outcome (Hauser, 2009).

Dopamine transporter imaging can aid differentiation between Parkinson's disease and non-degenerative mimics including essential tremor, vascular parkinsonism and drug-induced parkinsonism and differentiation between DLB/Parkinson's disease with dementia and Alzheimer's disease (Table 6). In patients with clinically inconclusive parkinsonism, imaging has the potential to provide valuable additional information to assist diagnosis. Patients with a clinical diagnosis of possible DLB are another group in whom dopaminergic imaging may be particularly helpful. Abnormal dopamine transporter imaging indicates underlying neurodegeneration, supportive of a diagnosis of Parkinson's disease or atypical parkinsonism, or DLB, and thus identifies patient groups in whom dopaminergic therapy may be beneficial. Conversely, normal dopaminergic imaging supports an alternative diagnosis such as Alzheimer's disease, essential tremor, psychogenic parkinsonism or drug-induced parkinsonism, and hence a different therapeutic approach. Dopamine transporter imaging is not helpful in differentiating between Parkinson's disease and atypical parkinsonism (multiple system atrophy, corticobasal degeneration, progressive supranuclear palsy); postsynaptic dopaminergic imaging may be helpful in this situation, but more data are required. Positive scans may also occur in vascular parkinsonism when the nigrostriatal system is affected. Potential future uses of dopaminergic imaging include: (i) improving accurate diagnosis; (ii) assisting in differential diagnosis; (iii) identification of patients with premotor Parkinson's disease, essential if a neuroprotective intervention becomes available as this would be a step to



**Table 6** Striatal dopaminergic imaging in patients with movement disorders or dementia (Nikolaus *et al.*, 2009)

Disorder	Presynaptic dopaminergic imaging versus healthy individuals	Postsynaptic dopaminergic imaging versus healthy individuals
Idiopathic Parkinson's disease	Decreased striatal dopamine synthesis Decreased dopamine storage Decreased dopamine release Decreased dopamine transporter	Unchanged D <sub>1</sub> receptor Normal or increased D <sub>2</sub> receptor in early stages of disease; reduced D <sub>2</sub> receptor in advanced disease
Essential tremor	No alterations of dopamine function	No data
Vascular parkinsonism	Variable reduction in dopamine function	No data
Drug-induced parkinsonism	No alterations of dopamine function	No data
Psychogenic parkinsonism	No alterations of dopamine function	No data
Dementia with Lewy bodies	Decreased striatal dopamine synthesis Decreased dopamine storage Decreased dopamine transporter	Conflicting reports (decreased versus normal/increased D <sub>2</sub> receptor)
Parkinson's disease with dementia	Decreased striatal dopamine synthesis Decreased dopamine storage Decreased dopamine transporter	Normal or increased D <sub>2</sub> receptor
Multiple system atrophy	Decreased striatal dopamine synthesis Decreased dopamine storage Decreased dopamine transporter	Decreased D <sub>1</sub> and D <sub>2</sub> receptor <sup>a</sup>
Progressive supranuclear palsy	Decreased striatal dopamine synthesis Decreased dopamine storage Decreased dopamine transporter	Decreased D <sub>2</sub> receptor
Corticobasal degeneration	Decreased striatal dopamine synthesis Decreased dopamine storage Decreased dopamine transporter	Conflicting reports (slightly decreased versus normal D <sub>2</sub> receptor)
Alzheimer's disease	No alterations of dopamine function	Conflicting reports (decreased D <sub>2</sub> receptor versus no significant difference)

<sup>a</sup>D<sub>2</sub> receptor also decreased relative to Parkinson's disease.

preventative therapy; (iv) monitoring disease progression in testing novel therapeutics; and (v) as an inclusion criterion for entry into clinical trials.

## Conflict of interest

J.C. has provided consultation to Abbott, Acadia, Acerra, ADAMAS, Astellas, Avanir, Bristol-Myers Squibb, CoMentis, Eisai, Elan, EnVivo, Forest, GE Healthcare, Genentech, GlaxoSmithKline, Janssen, Lilly, Lundbeck, Medivation, Medtronic, Merck, Merz, Myriad, Neuren, Neurokos, Novartis, Noven, Orion, Pfizer, Prana, reMYND, Schering Plough, Signum Bioscience, Sonexa, Takeda, Toyama and Wyeth pharmaceutical companies and to, Avid, Bayer, GE, MedAvante, Neurotrax and UBC assessment companies; owns stock in ADAMAS, Prana, Sonexa, MedAvante, Neurotrax and Neurokos; has given lectures for Eisai, Forest, Janssen, Novartis, Pfizer, Lundbeck and Merz; and owns the copyright of the Neuropsychiatric Inventory.

C.H. has contributed to advisory boards for Allergan, GE Healthcare, Merz, Teva, and UCB; speakers' bureau for Allergan, Boehringer-Ingelheim, Glaxo-Smith-Kline, Novartis and Teva; and received honoraria from the American Parkinson's Disease Association, the Parkinson's Disease Foundation, Neuro Alert, Network for Continuing Medical Education and New York University.

S.S. is an employee of PAREXEL, Inc, which has received funding from GE Healthcare to provide editorial assistance in the development of this article.

T.S. has contributed to advisory boards for GE Healthcare, Teva, Novartis, BI and UCB, to speakers' bureaus for Boehringer-Ingelheim, Ibsen, Novartis and Teva, and received honoraria from the Parkinson's Disease Foundation and National Parkinson Foundation.

A.W. has provided consultation to GE Healthcare.

P.K. has provided consultation to, and received research grants from, GE Healthcare.

## References

- Aarsland D, Kurz MW. The epidemiology of dementia associated with Parkinson disease. *J Neurol Sci* 2010; 289: 18–22.
- Abbott RD, Ross GW, White LR, Tanner CM, Masaki KH, Nelson JS, *et al.* Excessive daytime sleepiness and subsequent development of Parkinson disease. *Neurology* 2005; 65: 1442–6.
- Adams JR, van Netten H, Schulzer M, Mak E, McKenzie J, Strongosky A, *et al.* PET in LRRK2 mutations: comparison to sporadic Parkinson's disease and evidence for presymptomatic compensation. *Brain* 2005; 128 (Pt 12): 2777–85.
- Adbo WF, Borm GF, Munneke M, Verbeek MM, Esselink RA, Bloem BR. Ten steps to identify atypical parkinsonism. *J Neurol Neurosurg Psychiatry* 2006; 77: 1367–9.
- Anon. Biomarker promise for Parkinson's disease. *Lancet Neurol* 2010; 9: 1139.

- Antonini A, Leenders KL, Vontobel P, Maguire RP, Missimer J, Psylla M, et al. Complementary PET studies of striatal neuronal function in the differential diagnosis between multiple system atrophy and Parkinson's disease. *Brain* 1997; 120 (Pt 12): 2187–95.
- Antonini A, Moresco RM, Gobbo C, De Notaris R, Panzacchi A, Barone P, et al. The status of dopamine nerve terminal in Parkinson's disease and essential tremor: a PET study with the tracer [ $^{11}\text{C}$ ]FE-CIT. *Neurol Sci* 2001; 22: 47–8.
- Antonini A, Benti R, De Notaris R, Tesesi S, Zecchinelli A, Sacilotto G, et al.  $^{123}\text{I}$ -ioflupane/SPECT binding to striatal dopamine transporter (DAT) uptake in patients with Parkinson's disease, multiple system atrophy, and progressive supranuclear palsy. *Neurol Sci* 2003; 24: 149–50.
- Arnold G, Tatsch K, Kraft E, Oertel WH, Schwarz J. Steele-Richardson-Olszewski-syndrome: reduction of dopamine  $\text{D}_2$  receptor binding relates to the severity of midbrain atrophy in vivo: ( $^{123}\text{I}$ )BZM SPECT and MRI study. *Mov Disord* 2002; 17: 557–62.
- Asenbaum S, Pirker W, Angelberger P, Bencsits G, Pruckmayer M, Brücke T. [ $^{123}\text{I}$ ]beta-CIT and SPECT in essential tremor and Parkinson's disease. *J Neural Trans* 1998; 105: 1213–28.
- Benaderette S, Zanotti Fregonara P, Aparisi E, Nguyen C, Trocillo JM, Remy P, et al. Psychogenic Parkinsonism: a combination of clinical, electrophysiological, and [ $^{123}\text{I}$ ]FP-CIT SPECT scan explorations improves diagnostic accuracy. *Mov Disord* 2006; 21: 310–7.
- Benamer TS, Patterson J, Grosset DG, Booij J, de Bruin K, van Royen E, et al. Accurate differentiation of Parkinsonism and essential tremor using visual assessment of [ $^{123}\text{I}$ ]FP-CIT SPECT imaging: the [ $^{123}\text{I}$ ]FP-CIT Study Group. *Mov Disord* 2000; 15: 503–10.
- Berding G, Brücke T, Odin P, Brooks DJ, Kolbe H, Gielow P, et al. [ $^{123}\text{I}$ ]beta-CIT SPECT imaging in dopamine and serotonin transporters in Parkinson's disease and multiple system atrophy. *Nuklearmedizin* 2003; 42: 31–8.
- Berendse HW, Ponsen MM. Diagnosing premotor Parkinson's disease using a two-step approach combining olfactory testing and DAT SPECT imaging. *Parkinsonism Relat Disord* 2009; 15 (Suppl. 1): S26–30.
- Booij J, Kemp P. Dopamine transporter imaging with [ $^{123}\text{I}$ ]FP-CIT SPECT: potential effects of drugs. *Eur J Nucl Med Mol Imaging* 2008; 35: 424–38.
- Booij J, Tissingh G, Winogrodzka A, Boer GJ, Stoof JC, Wolters EC, et al. Practical benefit of [ $^{123}\text{I}$ ]FP-CIT SPET in the demonstration of the dopaminergic deficit in Parkinson's disease. *Eur J Nucl Med* 1997; 24: 68–71.
- Booij J, Speelman JD, Horstink MW, Wolters EC. The clinical benefit of imaging striatal dopamine transporters with [ $^{123}\text{I}$ ]FP-CIT SPET in differentiating patients with presynaptic parkinsonism from those with other forms of parkinsonism. *Eur J Nucl Med* 2001; 28: 266–72.
- Braak H, Del Tredici K, Rüb U, de Vos RA, Jansen Steur EN, Braak E. Staging of brain pathology related to sporadic Parkinson's disease. *Neurobiol Aging* 2003; 24: 197–211.
- Braune S. The role of cardiac metaiodobenzylguanidine uptake in the differential diagnosis of parkinsonian syndromes. *Clin Auton Res* 2001; 11: 351–5.
- Breit S, Reimold M, Reischi G, Klockgether T, Wüllner U. [ $^{11}\text{C}$ ]d-threo-methylphenidate PET in patients with Parkinson's disease and essential tremor. *J Neural Transm* 2006; 113: 187–93.
- Brooks DJ. Diagnosis and management of atypical parkinsonian syndromes. *J Neurol Neurosurg Psychiatry* 2002; 72: i10–6.
- Brooks DJ, Ibanez V, Sawle GV, Quinn N, Lees AJ, Mathias CJ, et al. Differing patterns of striatal  $^{18}\text{F}$ -dopa uptake in Parkinson's disease, multiple system atrophy, and progressive supranuclear palsy. *Ann Neurol* 1990; 28: 547–55.
- Brooks DJ, Ibanez V, Sawle GV, Playford ED, Quinn N, Mathias CJ, et al. Striatal  $\text{D}_2$  receptor status in patients with Parkinson's disease, striato-nigral degeneration, and progressive supranuclear palsy, measured with  $^{11}\text{C}$ -raclopride and positron emission tomography. *Ann Neurol* 1992; 31: 184–92.
- Brooks DJ. Neuroimaging in Parkinson's disease. *NeuroRx* 2004; 1: 243–54.
- Brücke T, Asenbaum S, Pirker W, Djamshidian S, Wenger S, Wöber C, et al. Measurement of the dopaminergic degeneration in Parkinson's disease with [ $^{123}\text{I}$ ]beta-CIT and SPECT. Correlation with clinical findings and comparison with multiple system atrophy and progressive supranuclear palsy. *J Neural Transm Suppl* 1997; 50: 9–24.
- Burn DJ, Brooks DJ. Nigral dysfunction in drug-induced Parkinsonism: an  $^{18}\text{F}$ -dopa PET study. *Neurology* 1993; 43: 552–6.
- Burn DJ, Sawle GV, Brooks DJ. Differential diagnosis of Parkinson's disease, multiple system atrophy, and Steele-Richardson-Olszewski syndrome: discriminant analysis of striatal  $^{18}\text{F}$ -dopa PET data. *J Neurol Neurosurg Psychiatr* 1994; 57: 278–84.
- Buter TC, van den Hout A, Matthews FE, Larsen JP, Brayne C, Aarsland D. Dementia and survival in Parkinson disease a 12-year population study. *Neurology* 2008; 70: 1017–22.
- Catafau AM, Tolosa E. Impact of dopamine transporter SPECT using 123-iodoflupane on diagnosis and management of patients with clinically uncertain Parkinsonian syndromes. *Mov Disord* 2004; 19: 1175–82.
- Ceravolo R, Volterrani D, Gambaccini G, Bernardini S, Rossi C, Logi C, et al. Presynaptic nigrostriatal function in a group of Alzheimer's disease patients with Parkinsonism: evidence from a dopamine transporter imaging study. *J Neural Transm* 2004; 111: 1065–73.
- Cheng HC, Ulane CM, Burke RE. Clinical progression in Parkinson disease and the neurobiology of axons. *Ann Neurol* 2010; 67: 715–23.
- Clarke CE. A 'cure' for Parkinson's disease: can neuroprotection be proven with current trial designs? *Mov Disord* 2004; 19: 491–8.
- Cohen O, Pullman S, Jurewicz E, Watner D, Louis ED. Rest tremor in patients with essential tremor: prevalence, clinical correlates, and electrophysiologic characteristics. *Arch Neurol* 2003; 60: 405–10.
- Colloby SJ, O'Brien JT, Fenwick JD, Firbank MJ, Burn DJ, McKeith IG, et al. The application of statistical parametric mapping to  $^{123}\text{I}$ -FP-CIT SPECT in dementia with Lewy bodies, Alzheimer's disease and Parkinson's disease. *Neuroimage* 2004; 23: 956–66.
- Colloby SJ, Williams ED, Burn DJ, Lloyd JJ, McKeith IG, O'Brien JT. Progression of dopaminergic degeneration in dementia with Lewy bodies and Parkinson's disease with and without dementia assessed using  $^{123}\text{I}$ -FP-CIT SPECT. *Eur J Nucl Med Mol Imaging* 2005; 32: 1176–85.
- Colloby SJ, Firbank MJ, Pakrasi S, Lloyd JJ, Driver I, McKeith IG, et al. A comparison of  $^{99\text{m}}\text{Tc}$ -exametazime and  $^{123}\text{I}$ -FP-CIT-SPECT imaging in the differential diagnosis of Alzheimer's disease and dementia with Lewy bodies. *Int Psychogeriatr* 2008; 20: 1124–40.
- Darcourt J, Booij J, Tatsch K, Varrone A, Vander Borgh T, Kapucu OL, et al. EANM procedure guidelines for brain neurotransmission SPECT using  $^{123}\text{I}$ -labelled dopamine transporter ligands, version 2. *Eur J Nucl Med Mol Imaging* 2010; 37: 443–50.
- Diaz-Corrales FJ, Sanz-Viedma S, Garcia-Solis D, Escobar-Delgado T, Mir P. Clinical features and  $^{123}\text{I}$ -FP-SPECT imaging in drug-induced Parkinsonism and Parkinson's disease. *Eur J Med Mol Imaging* 2010; 37: 556–64.
- Djaldetti R, Lev N, Melamed E. Lesions outside the CNS in Parkinson's disease. *Mov Disord* 2009; 24: 793–800.
- Doepf F, Plotkin M, Siegal L, Kivi A, Gruber D, Lobsien E, et al. Brain parenchyma sonography and  $^{123}\text{I}$ -FP-CIT in Parkinson's disease and essential tremor. *Mov Disord* 2008; 23: 405–10.
- El Fakhri G, Habert MO, Maksud P, Kas A, Malek Z, Kijewski MF, et al. Quantitative simultaneous  $^{99\text{m}}\text{Tc}$ -ECD/ $^{123}\text{I}$ -FP-CIT SPECT in Parkinson's disease and multiple system atrophy. *Eur J Nucl Med Mol Imaging* 2006; 33: 87–92.
- Eller M, Williams DR. Biological fluid biomarkers in neurodegenerative Parkinsonism. *Nat Rev Neurol* 2009; 5: 561–70.
- Eshuis SA, Jager PL, Maguire RP, Jonkman S, Dierckx RA, Leenders KL. Direct comparison of FP-CIT SPECT and F-DOPA PET in patients with Parkinson's disease and healthy controls. *Eur J Nucl Med Mol Imaging* 2009; 36: 454–62.

- Esper CD, Factor SA. Failure of recognition of drug-induced Parkinsonism in the elderly. *Mov Disord* 2008; 23: 401–4.
- Fahn S, Oakes D, Shoulson I, Kieburtz K, Randolph A, Lang A, et al. Levodopa and the progression of Parkinson's disease. *N Engl J Med* 2004; 351: 2498–508.
- Felicio AC, Godeiro-Junior C, Shih MC, Borges V, Silva SM, Aguiar Pde C, et al. Evaluation of patients with clinically unclear parkinsonian syndromes submitted to brain SPECT imaging using the technetium-99m labelled tracer TRODAT-1. *J Neurol Sci* 2010a; 291: 64–8.
- Felicio AC, Godeiro-Junior C, Moriyama TS, Shih MC, Hoexter MQ, Borges V, et al. Degenerative Parkinsonism in patients with psychogenic Parkinsonism: a dopamine transporter imaging study. *Clin Neurol Neurosurg* 2010b; 112: 282–5.
- Gaig C, Martí MJ, Tolosa E, Valldeoriola F, Paredes P, Lomeña FJ, et al. <sup>123</sup>I-Ioflupane SPECT in the diagnosis of suspected psychogenic Parkinsonism. *Mov Disord* 2006; 21: 1994–8.
- Gerschlagler W, Bencsits G, Pirker W, Bloem BR, Asenbaum S, Prayer D, et al. [<sup>123</sup>I]beta-CIT SPECT distinguishes vascular parkinsonism from Parkinson's disease. *Mov Disord* 2002; 17: 518–23.
- Ghaemi M, Hilker R, Rudolf J, Sobesky J, Heiss WD. Differentiating multiple system atrophy from Parkinson's disease: contribution of striatal and midbrain MRI volumetry and multi-tracer PET imaging. *J Neurol Neurosurg Psychiatry* 2002; 73: 517–23.
- Gilman S, Koeppe RA, Little R, An H, Junck L, Giordani B, et al. Striatal monoamine terminals in Lewy body dementia and Alzheimer's disease. *Ann Neurol* 2004; 55: 774–80.
- Gilman S, Wenning GK, Low PA, Brooks DJ, Mathias CJ, Trojanowski JQ, et al. Second consensus statement on the diagnosis of multiple system atrophy. *Neurology* 2008; 71: 670–6.
- Gomperts SN, Rentz DM, Moran E, Becker JA, Locascio JJ, Klunk WE, et al. Imaging amyloid deposition in Lewy body diseases. *Neurology* 2008; 71: 903–10.
- Hambÿe AS, Vervaet A, Dethy S. FP-CIT SPECT in clinically inconclusive Parkinsonian syndrome during amiodarone treatment: a study with follow-up. *Nucl Med Commun* 2010; 31: 583–9.
- Hanyu H, Shimizu S, Hirao K, Sakurai H, Iwamoto T, Chikamori T, et al. The role of <sup>123</sup>I-metaiodobenzylguanidine myocardial scintigraphy in the diagnosis of Lewy body disease in patients with dementia in a memory clinic. *Dement Geriatr Cogn Disord* 2006; 22: 379–84.
- Hauser RA. New considerations in the medical management of early Parkinson's disease: impact of recent clinical trials on treatment strategy. *Parkinsonism Relat Disord* 2009; 15 (Suppl. 3): S17–21.
- Hely MA, Reid WG, Adena MA, Halliday GM, Morris JG. The Sydney multicenter study of Parkinson's disease: the inevitability of dementia at 20 years. *Mov Disord* 2008; 23: 837–44.
- Hilker R, Thomas AV, Klein JC, Weisenbach S, Kalbe E, Burghaus L, et al. Dementia in Parkinson disease: functional imaging of cholinergic and dopaminergic pathways. *Neurology* 2005; 65: 1716–22.
- Hu XS, Okamura N, Arai H, Higuchi M, Matsui T, Tashiro M, et al. <sup>18</sup>F-fluorodopa PET study of striatal dopamine uptake in the diagnosis of dementia with Lewy bodies. *Neurology* 2000; 55: 1575–7.
- Huang WS, Chiang YH, Lin JC, Chou YH, Cheng CY, Liu RS. Crossover study of <sup>99m</sup>Tc-TRODAT-1 SPECT and <sup>18</sup>F-FDOPA PET in Parkinson's disease patients. *J Nucl Med* 2003; 44: 999–1005.
- Hughes AJ, Daniel SE, Kilford L, Lees AJ. Accuracy of clinical diagnosis of idiopathic Parkinson's disease: a clinico-pathological study of 100 cases. *J Neurol Neurosurg Psychiatry* 1992; 55: 181–4.
- Hughes AJ, Daniel SE, Ben-Shlomo Y, Lees AJ. The accuracy of diagnosis of parkinsonian syndromes in a specialist movement disorder service. *Brain* 2002; 125: 861–70.
- Hwang WJ, Yao WJ, Wey SP, Ting G. Reproducibility of <sup>99m</sup>Tc-TRODAT-1 SPECT measurement of dopamine transporters in Parkinson's disease. *J Nucl Med* 2004; 45: 207–13.
- Isaias IU, Marotta G, Hirano S, Canesi M, Benti R, Righini A, et al. Imaging essential tremor. *Mov Disord* 2010; 25: 679–86.
- Jain S, Lo SE, Louis ED. Common misdiagnosis of a common neurological disorder: how are we misdiagnosing essential tremor? *Arch Neurol* 2006; 63: 1100–4.
- Jennings DL, Seibyl JP, Oakes D, Eberly S, Murphy J, Marek K. <sup>123</sup>I β-CIT and single-photon emission computed tomographic imaging vs clinical evaluation in Parkinsonian syndrome: unmasking a diagnosis. *Arch Neurol* 2004; 61: 1224–9.
- Jennings DL, Tabamo RT, Seibyl JS, Marek KM. InSPECT: Investigating the effect of short-term treatment with pramipexole or levodopa on [<sup>123</sup>I]β-CIT and SPECT imaging. The 11<sup>th</sup> International Congress of Parkinson's Disease and Movement Disorders, Istanbul 2007. Abstract 465.
- Kalra S, Grosset DG, Benamer HT. Differentiating vascular Parkinsonism from idiopathic Parkinson's disease: a systematic review. *Mov Disord* 2010; 25: 49–56.
- Kemp PM, Holmes C. Imaging in dementia with Lewy bodies: a review. *Nucl Med Commun* 2007; 28: 511–9.
- Khan NL, Valente EM, Bentivoglio AR, Wood NW, Albanese A, Brooks DJ, et al. Clinical and subclinical dopaminergic dysfunction in PARK6-linked Parkinsonism: an <sup>18</sup>F-dopa PET study. *Ann Neurol* 2002; 52: 849–53.
- Kim YJ, Ichise M, Ballinger JR, Vines D, Erami SS, Tatschida T, et al. Combination of dopamine transporter and D<sub>2</sub> receptor SPECT in the diagnostic evaluation of PD, MSA, and PSP. *Mov Disord* 2002; 17: 303–12.
- Kish SJ, Shannak K, Hirnykiewicz O. Uneven pattern of dopamine loss in the striatum of patients with idiopathic Parkinson's disease. Pathophysiological and clinical implications. *N Engl J Med* 1988; 318: 876–56.
- Klein JC, Eggers C, Kalbe E, Weisenbach S, Hohmann C, Vollmar S, et al. Neurotransmitter changes in dementia with Lewy bodies and Parkinson disease dementia in vivo. *Neurology* 2010; 74: 885–92.
- Koeppe RA, Gilman S, Junck L, Wernette K, Frey KA. Differentiating Alzheimer's disease from dementia with Lewy bodies and Parkinson's disease with (+)-[<sup>11</sup>C] dihydrotetrabenazine positron emission tomography. *Alzheimers Dement* 2008; 4 (1 Suppl. 1): S67–76.
- Knudsen GM, Karlsborg M, Thomsen G, Krabbe K, Regeur L, Nygaard T, et al. Imaging of dopamine transporters and D<sub>2</sub> receptors in patients with Parkinson's disease and multiple system atrophy. *Eur J Nucl Med Mol Imaging* 2004; 31: 1631–8.
- Lang AE, Koller WC, Fahn S. Psychogenic parkinsonism. *Arch Neurol* 1995; 52: 802–10.
- Lees AJ. Trauma and Parkinson disease. *Rev Neurol* 1997; 153: 541–6.
- Lim SM, Katsifis A, Villemagne VL, Best R, Jones G, Saling M, et al. The <sup>18</sup>F-FDG PET cingulate island sign and comparison to <sup>123</sup>I-beta-CIT SPECT for diagnosis of dementia with Lewy bodies. *J Nucl Med* 2009; 50: 1638–45.
- Litvan I, Bhatia KP, Burn DJ, Goetz CG, Lang AE, McKeith I, et al. Movement Disorders Society Scientific Issues Committee report: SIC Task Force appraisal of clinical diagnostic criteria for Parkinsonian disorders. *Mov Disord* 2003; 18: 467–86.
- Lorberboym M, Djaldetti R, Melamed E, Sadeh M, Lampl Y. <sup>123</sup>I-FP-CIT SPECT imaging of dopamine transporters in patients with cerebrovascular disease and clinical diagnosis of vascular parkinsonism. *J Nucl Med* 2004; 45: 1688–93.
- Lorberboym M, Treves TA, Melamed E, Lampl Y, Hellman M, Djaldetti R. [<sup>123</sup>I]-FP/CIT SPECT imaging for distinguishing drug-induced parkinsonism from Parkinson's disease. *Mov Disord* 2006; 21: 510–4.
- Louis ED. Essential tremors: a family of neurodegenerative disorders? *Arch Neurol* 2009; 66: 1202–8.
- Louis ED, Asabere N, Agnew A, Moskowitz CB, Lawton A, Cortes E, et al. Rest tremor in advanced essential tremor: a post-mortem study of nine cases. *J Neurol Neurosurg Psychiatry* 2011; 82: 261–5.
- Lu CS, Weng YH, Chen MC, Chen RS, Tzen KY, Wey SP, et al. <sup>99m</sup>Tc-TRODAT-1 imaging of multiple system atrophy. *J Nucl Med* 2004; 45: 49–55.
- Lubarsky M, Juncos JL. Progressive supranuclear palsy: a current review. *Neurologist* 2008; 14: 79–88.
- Mahapatra RK, Edwards MJ, Schott JM, Bhatia KP. Corticobasal degeneration. *Lancet Neurol* 2004; 3: 736–43.

- Marek K, Jennings D. Can we image premotor Parkinson disease? *Neurology* 2009; 72 (Suppl. 2): S21–6.
- Marek K, Jennings D, Seibyl J. Long-term follow-up of patients with scans without evidence of dopaminergic deficit (SWEDD) in the ELLDOPA study. *Neurology* 2005; 64 (Suppl. 1): A274.
- Marsden CD, Jenner P. The pathophysiology of extrapyramidal side-effects of neuroleptic drugs. *Psychol Med* 1980; 10: 55–72.
- Marshall VL, Patterson J, Hadley DM, Grosset KA, Grosset DG. Two-year follow-up in 150 consecutive cases with normal dopamine transporter imaging. *Nucl Med Commun* 2006; 27: 933–7.
- Marshall VL, Reininger CB, Marquardt M, Patterson J, Hadley DM, Oertel WH, et al. Parkinson's disease is overdiagnosed clinically at baseline in diagnostically uncertain cases: a 3-year European multicenter study with repeat [<sup>123</sup>I]FP-CIT SPECT. *Mov Disord* 2009; 24: 500–8.
- McKeith I, Fairburn A, Perry R, Thompson P, Perry E. Neuroleptic sensitivity in patients with senile dementia of Lewy body type. *BMJ* 1992; 305: 673–8.
- McKeith IG, Dickson DW, Lowe J, Emre M, O'Brien JT, Feldman H, et al. Diagnosis and management of dementia with Lewy bodies: third report of the DLB consortium. *Neurology* 2005; 65: 1863–72.
- McKeith I, O'Brien J, Tatsch K, Booi J, Darcourt J, Padovani A, et al. Sensitivity and specificity of dopamine transporter imaging with [<sup>123</sup>I]-FP-SPECT in dementia with Lewy bodies: a phase III, multicentre study. *Lancet Neurol* 2007; 6: 305–13.
- Meara J, Bhowmick BK, Hobson P. Accuracy of diagnosis in patients with presumed Parkinson's disease. *Age Aging* 1999; 28: 99–102.
- Merdes AR, Hansen LA, Jeste DV, Galasko D, Hofstetter CR, Ho GJ, et al. Influence of Alzheimer pathology on clinical diagnostic accuracy in dementia with Lewy bodies. *Neurology* 2003; 27: 1568–90.
- Morrish PK. DAT-SPECTAll that glitters is not gold. <http://jnnp.bmj.com/content/81/1/5/reply> (May 27, 2010, date last accessed).
- Mosconi L, Tsui WH, Herholz K, Pupi A, Drzezga A, Lucignani G, et al. Multicenter standardized [<sup>18</sup>F]-FDG PET diagnosis of mild cognitive impairment, Alzheimer's disease, and other dementias. *J Nucl Med* 2008; 49: 390–8.
- National Institute of Neurological Disorders and Stroke Parkinson's disease background [http://www.ninds.nih.gov/disorders/parkinsons\\_disease/parkinsons\\_disease\\_background.htm](http://www.ninds.nih.gov/disorders/parkinsons_disease/parkinsons_disease_background.htm) (May 27, 2010, date last accessed).
- Nelson PT, Jicha GA, Kryscio RJ, Abner EL, Schmitt FA, Cooper G, et al. Low sensitivity in clinical diagnosis of dementia with Lewy bodies. *J Neurol* 2010; 257: 359–66.
- Newman EJ, Breen K, Patterson J, Hadley DM, Grosset KA, Grosset DG. Accuracy of Parkinson's disease diagnosis in 610 general practice patients in the West of Scotland. *Mov Disord* 2009; 24: 2379–85.
- Nikolaus S, Antke C, Müller HW. In vivo imaging of synaptic function in the central nervous system I. Movement disorders and dementia. *Behav Brain Res* 2009; 204: 1–31.
- Nussbaum RL, Ellis CE. Alzheimer's disease and Parkinson's disease. *N Engl J Med* 2003; 348: 1356–64.
- O'Brien JT, Colloby S, Fenwick J, Williams ED, Firbank M, Burn D, et al. Dopamine transporter loss visualized with FP-CIT SPECT in the differential diagnosis of dementia with Lewy bodies. *Arch Neurol* 2004; 61: 919–25.
- O'Brien J, McKeith IG, Walker Z, Tatsch K, Booi J, Darcourt J, et al. Diagnostic accuracy of [<sup>123</sup>I]-FP-CIT SPECT in possible dementia with Lewy bodies. *Br J Psychiatry* 2009; 194: 34–9.
- Otsuka M, Ichiya Y, Hosokawa S, Kuwabara Y, Tahara T, Fukumura T, et al. Striatal blood flow, glucose metabolism and [<sup>18</sup>F]-uptake: difference in Parkinson's disease and atypical parkinsonism. *J Neurol Neurosurg Psychiatry* 1991; 54: 898–904.
- Oyanagi C, Katsumi Y, Hanakawa T, Hayashi T, Thuy DD, Hashikawa K, et al. Comparison of striatal dopamine D<sub>2</sub> receptors in Parkinson's disease and progressive supranuclear palsy patients using [<sup>123</sup>I] iodo-benzofuran single-photon emission computed tomography. *J Neuroimaging* 2002; 12: 316–24.
- Parkinson Study Group. Pramipexole vs levodopa as initial treatment for Parkinson disease. *JAMA* 2000; 284: 1931–8.
- Parkinson Study Group. Dopamine transporter brain imaging to assess the effects of pramipexole vs levodopa on Parkinson disease progression. *JAMA* 2002; 287: 1653–61.
- Parkinson Study Group PRECEPT Investigators. Mixed lineage kinase inhibitor CEP-1347 fails to delay disability in early Parkinson disease. *Neurology* 2007; 69: 1480–90.
- Pavese N, Brooks DJ. Imaging neurodegeneration in Parkinson's disease. *Biochim Biophys Acta* 2009; 1792: 722–9.
- Pavese N, Khan NL, Scherfler C, Cohen L, Brooks DJ, Wood NW, et al. Nigrostriatal dysfunction in homozygous and heterozygous parkin gene carriers: an [<sup>18</sup>F]-dopa PET progression study. *Mov Disord* 2009a; 24: 2260–6.
- Pavese N, Kiferle L, Piccini P. Neuroprotection and imaging studies in Parkinson's disease. *Parkinsonism Relat Disord* 2009b; 15S: S33–7.
- Pifarré P, Cuberas G, Hernández J, Lorenzo C, Miquel F, Castell-Conesa J. Cortical and subcortical patterns of I-123 iodobenzamide SPECT in striatal D(2) receptor parkinsonisms. *Clin Nucl Med* 2010; 35: 228–33.
- Piggott MA, Marshall EF, Thomas N, Lloyd S, Court JA, Jaros E, et al. Striatal dopaminergic markers in dementia with Lewy bodies, Alzheimer's and Parkinson's diseases: rostrocaudal distribution. *Brain* 1999; 122 (Pt 8): 1449–68.
- Pirker W, Asenbaum S, Bencsits G, Prayer D, Gerschlager W, Deecke L, et al. [<sup>123</sup>I]beta-CIT SPECT in multiple system atrophy, progressive supranuclear palsy, and corticobasal degeneration. *Mov Disord* 2000; 15: 1158–67.
- Pirker W, Djamshidian S, Asenbaum S, Gerschlager W, Tribl G, Hoffman M, et al. Progression of dopaminergic degeneration in Parkinson's disease and atypical parkinsonism: a longitudinal beta-CIT SPECT study. *Mov Disord* 2002; 17: 45–53.
- Plotkin M, Amthauer H, Klaffe S, Kühn A, Lüdemann L, Arnold G, et al. Combined [<sup>123</sup>I]-FP-CIT and [<sup>123</sup>I]-IBZM SPECT for the diagnosis of parkinsonian syndromes: study on 72 patients. *J Neural Transm* 2005; 112: 677–92.
- Ponsen MM, Stoffers D, Booi J, van Eck-Smit BL, Wolters ECh, Berendse HW. Idiopathic hyposmia as a preclinical sign of Parkinson's disease. *Ann Neurol* 2004; 56: 173–81.
- Postuma RB, Gagnon JF, Vendette M, Fantini ML, Massicotte-Marquez J, Montplaisir J. Quantifying the risk of neurodegenerative disease in idiopathic REM sleep behavior disorder. *Neurology* 2009; 72: 1296–300.
- Prunier C, Tranquart F, Cottier JP, Giraudeau B, Chalon S, Guilloteau D, et al. Quantitative analysis of striatal dopamine D<sub>2</sub> receptors with [<sup>123</sup>I]-iodolisuride SPECT in degenerative extrapyramidal diseases. *Nucl Med Commun* 2001; 22: 1207–14.
- Rajput A, Rozdilsky B, Ang L. Accuracy of clinical diagnosis in parkinsonism—a prospective study. *Can J Neurol Sci* 1991; 18: 275–8.
- Rascol O, Schelosky L. [<sup>123</sup>I]-metaiodobenzylguanidine scintigraphy in Parkinson's disease and related disorders. *Mov Disord* 2009; 24 (Suppl. 2): S732–41.
- Rossi C, Volterrani D, Nicoletti V, Manca G, Frosini D, Kiferle L, et al. "Parkinson-dementia" diseases: a comparison by double tracer SPECT studies. *Parkinsonism Relat Disord* 2009; 15: 762–6.
- Rowe CC, Ng S, Ackermann U, Gong SJ, Pike K, Savage G, et al. Imaging beta-amyloid burden in aging and dementia. *Neurology* 2007; 68: 1718–25.
- Samuel W, Caligiuri M, Galasko D, Lacro J, Marini M, McClure FS, et al. Better cognitive and psychopathologic response to donepezil in patients prospectively diagnosed as dementia with Lewy bodies: a preliminary study. *Int J Geriatr Psychiatry* 2000; 15: 794–802.
- Sawle GV, Brooks DJ, Marsden CD, Frackowiak RS. Corticobasal degeneration. A unique pattern of regional cortical oxygen hypometabolism and striatal fluorodopa uptake demonstrated by positron emission tomography. *Brain* 1991; 114 (Pt 1B): 541–56.
- Scherfler C, Nocker M. Dopamine transporter SPECT: how to remove subjectivity. *Mov Disord* 2009; 24 (Suppl. 2): S721–4.
- Scherfler C, Seppi K, Donnemiller E, Goebel G, Brenneis C, Virgolini I, et al. Voxel-wise analysis of [<sup>123</sup>I]beta-CIT SPECT differentiates the

- Parkinson variant of multiple system atrophy from idiopathic Parkinson's disease. *Brain* 2005; 128: 1605–12.
- Schillaci O, Pierantozzi M, Filippi L, Manni C, Brusa L, Danieli R, et al. The effect of levodopa therapy on dopamine transporter SPECT imaging with <sup>123</sup>I-FP-CIT in patients with Parkinson's disease. *Eur J Nucl Med Mol Imaging* 2005; 32: 1452–6.
- Schneider SA, Edwards MJ, Mir P, Cordivari C, Hooker J, Dickson J, et al. Patients with adult-onset dystonic tremor resembling Parkinsonism tremor have scans without evidence of dopaminergic deficit (SWEDDs). *Mov Disord* 2007; 22: 2210–15.
- Schrag A, Ben-Shlomo Y, Quinn N. How valid is the clinical diagnosis of Parkinson's disease in the community? *J Neurol Neurosurg Psychiatry* 2002; 73: 529–34.
- Schreckenberger M, Hägele S, Seissmeier T, Buchholz HG, Armbrust-Henrich H, Rösch F, et al. The dopamine D<sub>2</sub> receptor ligand <sup>18</sup>F-desmethoxyfallypride: an appropriate fluorinated PET tracer for the differential diagnosis of Parkinsonism. *Eur J Nucl Med Mol Imaging* 2004; 31: 1128–35.
- Seibyl J, Jennings D, Tabamo R, Marek K. The role of neuroimaging in the early diagnosis and evaluation of Parkinson's disease. *Minerva Med* 2005; 96: 353–64.
- Seibyl J, Jennings D, Tabamo R, Marek K. Unique roles of SPET brain imaging in clinical and research studies. *Q J Nucl Med Mol Imaging* 2005b; 49: 215–21.
- Shiba M, Bower JH, Maraganore DM, McDonnell SK, Peterson BJ, Ahlskog JE, et al. Anxiety disorders and depressive disorders preceding Parkinson's disease: a case-control study. *Mov Disord* 2000; 15: 669–77.
- Shih MC, Amaro E Jr, Ferraz HB, Hoexter MQ, Goulart FO, Wagner J, et al. Neuroimaging of the dopamine transporter in Parkinson's disease: first study using [<sup>99m</sup>Tc]-TRODAT and SPECT in Brazil. *Arq Neuropsiquiatr* 2006; 64 (3A): 628–34.
- Stephen PJ, Williamson J. Drug-induced parkinsonism in the elderly. *Lancet* 1984; 2 (8411): 1082–3.
- Stiasny-Kolster K, Doerr Y, Möller JC, Höffken H, Behr TM, Oertel WJ, et al. Combination of 'idiopathic' REM sleep behaviour disorder and olfactory dysfunction as possible indicator for alpha-synucleinopathy demonstrated by dopamine transporter FP-CIT SPECT. *Brain* 2005; 128 (Pt 1): 126–37.
- Stoffers D, Booij J, Bosscher L, Winogrodzka A, Wolters EC, Berendse HW. Early-stage [<sup>123</sup>I]beta-CIT SPECT and long-term clinical follow-up in patients with an initial clinical diagnosis of Parkinson's disease. *Eur J Med Mol Imaging* 2005; 32: 689–95.
- Swanson RL, Newberg AB, Acton PD, Siderowf A, Winterring N, Alavi A, et al. Differences in [<sup>99m</sup>Tc]TRODAT-1 SPECT binding to dopamine transporters in patients with multiple system atrophy and Parkinson's disease. *Eur J Med Mol Imaging* 2005; 32: 302–7.
- Tang CC, Poston KL, Eckert T, Feigin A, Frucht S, Gudesblatt M, et al. Differential diagnosis of parkinsonism: a metabolic imaging study using pattern analysis. *Lancet Neurol* 2010; 9: 149–58.
- Teive HA, Troiano AR, Germiniani FM, Werneck LC. Flunarizine and cinnarizine-induced Parkinsonism: a historical and clinical analysis. *Parkinsonism Relat Disord* 2004; 10: 243–5.
- Thanvi B, Robinson T. Vascular Parkinsonism—an important cause of parkinsonism in older people. *Age Ageing* 2005; 34: 114–9.
- Thanvi B, Treadwell S. Drug induced Parkinsonism: a common cause of parkinsonism in older people. *Postgrad Med J* 2009; 85: 322–6.
- Thobois S, Vingerhoets F, Fraix V, Xie-Brustolin J, Mollion H, Costes N, et al. Role of dopaminergic treatment in dopamine receptor down-regulation in advanced Parkinson disease: a positron emission tomographic study. *Arch Neurol* 2004; 61: 1705–9.
- Tinazzi M, Ottaviani S, Isaias IU, Pasquin I, Steinmayr M, Vampini C, et al. [<sup>123</sup>I]FP-CIT SPET imaging in drug-induced Parkinsonism. *Mov Disord* 2008; 23: 1825–9.
- Tinazzi M, Antonini A, Bovi T, Pasquin I, Steinmayr M, Moretto G, et al. Clinical and [<sup>123</sup>I]FP-CIT SPET imaging follow-up in patients with drug-induced Parkinsonism. *J Neurol* 2009; 256: 910–15.
- Tolosa E, Coelho M, Gallardo M. DAT imaging in drug-induced and psychogenic Parkinsonism. *Mov Disord* 2003; 18 (Suppl. 7): S28–33.
- Tolosa E, Borghet TV, Moreno E. DaTSCAN™ Clinically Uncertain Parkinsonian Syndromes Study Group. Accuracy of DaTSCAN™ (<sup>123</sup>I-ioflupane) SPECT in diagnosis of patients with clinically uncertain Parkinsonism: 2-year follow-up of an open-label study. *Mov Disord* 2007a; 22: 2346–51.
- Tolosa E, Compta Y, Gaig C. The premotor phase of Parkinson's disease. *Parkinsonism Relat Disord* 2007b; 13 (Suppl): S2–7.
- Turjanski N, Lees AJ, Brooks DJ. Dopaminergic function in patients with posttraumatic Parkinsonism: an <sup>18</sup>F-dopa PET study. *Neurology* 1997; 49: 183–9.
- Tzen KY, Lu CS, Yen TC, Wey SP, Ting G. Differential diagnosis of Parkinson's disease and vascular Parkinsonism by <sup>99m</sup>Tc-TRODAT-1. *J Nucl Med* 2001; 42: 408–13.
- Vaamonde-Gamo J, Flores-Barragán JM, Ibáñez R, Gudín M, Hernández A. DaT-SCAN SPECT in the differential diagnosis of dementia with Lewy bodies and Alzheimer's disease. *Rev Neurol* 2005; 41: 276–9.
- Van Gerpen JA. Drug-induced Parkinsonism. *Neurologist* 2002; 8: 363–70.
- Van Laere K, Clerinx K, D'Hondt E, de Groot T, Vandenberghe W. Combined striatal binding and cerebral influx analysis of dynamic <sup>11</sup>C-raclopride PET improves early differentiation between multiple-system atrophy and Parkinson disease. *J Nucl Med* 2010; 51: 588–95.
- Varrone A, Marek KL, Jennings D, Innis RB, Seibyl JP. [<sup>123</sup>I]β-CIT SPECT imaging demonstrates reduced density of striatal dopamine transporters in Parkinson's disease and multiple system atrophy. *Mov Disord* 2001; 16: 1023–32.
- Vlaar AM, de Nijs T, Kessels AG, Vreeling FW, Winogrodzka A, Mess WH, et al. Diagnostic value of <sup>123</sup>I-ioflupane and <sup>123</sup>I-iodobenzamide SPECT scans in 248 patients with Parkinsonian syndromes. *Eur Neurol* 2008; 59: 258–66.
- Walker Z, Costa DC, Walker RW, Shaw K, Gacinovic S, Stevens T, et al. Differentiation of dementia with Lewy bodies from Alzheimer's disease using a dopaminergic presynaptic ligand. *J Neurol Neurosurg Psychiatry* 2002; 73: 134–40.
- Walker Z, Costa DC, Walker RW, Lee L, Livingston G, Jaros E, et al. Striatal dopamine transporter in dementia with Lewy bodies and Parkinson disease: a comparison. *Neurology* 2004; 62: 1568–72.
- Walker Z, Jaros E, Walker RW, Lee L, Costa DC, Livingston G, et al. Dementia with Lewy bodies: a comparison of clinical diagnosis, FP-CIT single photon emission computed tomography imaging and autopsy. *J Neurol Neurosurg Psychiatry* 2007; 78: 1176–81.
- Wang J, Jiang YP, Liu XD, Chen ZP, Yang LQ, Liu CJ, et al. <sup>99m</sup>Tc-TRODAT-1 SPECT study in early Parkinson's disease and essential tremor. *Acta Neurol Scand* 2005; 112: 380–5.
- Weng YH, Yen TC, Chen MC, Kao PF, Tzen KY, Chen RS, et al. Sensitivity and specificity of <sup>99m</sup>Tc-TRODAT-1 SPECT imaging in differentiating patients with idiopathic Parkinson's disease from healthy subjects. *J Nucl Med* 2004; 45: 393–401.
- Whone AL, Watts RL, Stoessl AJ, Davis M, Reske S, Nahmias C, et al. Slower progression of Parkinson's disease with ropinirole versus levodopa: the REAL-PET study. *Ann Neurol* 2003; 54: 93–101.
- Zaccai J, McCracken C, Brayne C. A systematic review of prevalence and incidence studies of dementia with Lewy bodies. *Age Ageing* 2005; 34: 561–6.
- Zaccai J, Brayne C, McKeith I, Matthews F, Ince PG; MRC Cognitive Function, Ageing Neuropathology Study. Patterns and stages of alpha-synucleinopathy: relevance in a population-based cohort. *Neurology* 2008; 70: 1042–8.
- Zijlmans J, Evans A, Fontes F, Katzenschlager R, Gacinovic S, Lees AJ, et al. [<sup>123</sup>I]FP-spect study in vascular Parkinsonism and Parkinson's disease. *Mov Disord* 2007; 2: 1278–85.