

Diagnosis and Management of Parapneumonic Effusions and Empyema

Steve A. Sahn

Division of Pulmonary, Critical Care, Allergy, and Sleep Medicine, Medical University of South Carolina, Charleston

Approximately 1 million patients develop parapneumonic effusions (PPEs) annually in the United States. The outcome of these effusions is related to the interval between the onset of clinical symptoms and presentation to the physician, comorbidities, and timely management. Early antibiotic treatment usually prevents the development of a PPE and its progression to a complicated PPE and empyema. Pleural fluid analysis provides diagnostic information and guides therapy. If the PPE is small to moderate in size, free-flowing, and nonpurulent (pH, >7.30), it is highly likely that antibiotic treatment alone will be effective. Prolonged pneumonia symptoms before evaluation, pleural fluid with a pH <7.20, and loculated pleural fluid suggest the need for pleural space drainage. The presence of pus (empyema) aspirated from the pleural space always requires drainage. Fibrinolytics are most likely to be effective during the early fibrinolytic stage and may make surgical drainage unnecessary. If pleural space drainage is ineffective, video-assisted thoracic surgery should be performed without delay.

Parapneumonic effusion (PPE; i.e., pleural fluid that results from pneumonia or lung abscess) is the most common cause of an exudative pleural effusion. PPE may be the consequence of either community-acquired or nosocomial pneumonia. Between 20% and 57% of the 1 million patients hospitalized yearly in the United States with pneumonia develop a PPE [1–3]. Although PPEs are relatively common, empyema (i.e., the accumulation of pus in the pleural space) is less common, occurring in 5%–10% of patients who experience PPE [4]. In a review of 14 studies of empyema that involved a total of 1383 patients, 70% of PPEs were secondary to pneumonia (figure 1) [4].

CLASSIFICATION

A practical, clinical classification of PPE is as follows: (1) an uncomplicated parapneumonic effusion (UPPE) resolves with antibiotic therapy alone, without pleural space sequelae; (2) a complicated parapneumonic effusion (CPPE) requires pleural space drainage to resolve pleural sepsis and prevent progression

to an empyema; and (3) empyema, the end stage of a PPE, occurs. Empyema is defined by its appearance; it is an opaque, whitish-yellow, viscous fluid that is the result of serum coagulation proteins, cellular debris, and fibrin deposition. Empyemas develop primarily because of delayed presentation by the patient with advanced pneumonia and progressive pleural infection and, less often, from inappropriate clinical management. Early antibiotic treatment prevents progression of pneumonia and the development of a PPE. Early antibiotic treatment will prevent development of an UPPE and progression to empyema. Risk factors for empyema include age (empyemas occur most frequently among children and elderly persons), debilitation, male sex, pneumonia requiring hospitalization, and comorbid diseases, such as bronchiectasis, chronic obstructive pulmonary disease, rheumatoid arthritis, alcoholism, diabetes, and gastroesophageal reflux disease [5]. Bacterial pneumonia, pneumonia due to atypical bacteria, and viral pneumonia are all associated with PPE; however, the relative incidence of PPE varies with the organism. Viral pneumonia and *Mycoplasma pneumoniae* pneumonia cause small pleural effusions in 20% of patients [6]. *Streptococcus pneumoniae* pneumonia causes PPE in 40%–57% of cases [3], and cases of pneumonia due to *Staphylococcus aureus*, gram-negative bacilli, or anaerobes are associated with pleural effusions in ~50% of cases [9]. The morbidity and mortality of pneumonia increase when the patient presents with a PPE, because this stage correlates with more-advanced pneumonia. Patients with empyema have a reported mortality rate

Received 4 June 2007; accepted 26 July 2007; electronically published 24 October 2007.

Reprints or correspondence: Dr. Steven A. Sahn, Div. of Pulmonary, Critical Care, Allergy, and Sleep Medicine, Medical University of South Carolina, 96 Jonathan Lucas St., Ste. 812CSB, PO Box 250630, Charleston, SC 29425 (sahnsa@musc.edu).

Clinical Infectious Diseases 2007;45:1480–6

© 2007 by the Infectious Diseases Society of America. All rights reserved.

1058-4838/2007/4511-0014\$15.00

DOI: 10.1086/522996

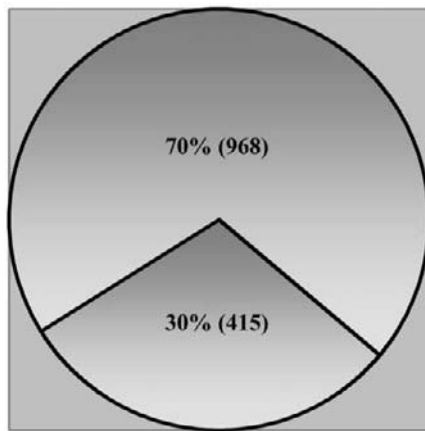


Figure 1. Causes of empyema in 14 prior studies. Of the 1383 patients in the studies, 70% were parapneumonic. For the other 30% of patients, trauma was the cause of empyema in 7%, empyema was postoperative in 6%, and prior tuberculosis was the cause in 4%; 12% of cases were due to other causes.

of 5%–30%, with the incidence varying on the basis of comorbid conditions [5]. The mortality rate may be as high as 40% among immunocompromised hosts [7]. Bilateral PPE at the time of hospital admission is associated with increased mortality (relative risk, 2.8) [8].

PATHOPHYSIOLOGY

An estimated time course of untreated or inappropriately treated PPE is shown in figure 2. The inciting event in most cases of pneumonia is the aspiration of organisms from the oropharynx. If the organism load is high and the patient's host defenses are impaired (e.g., as a result of cigarette smoking or alcohol ingestion), the patient is more likely to develop pneumonia. The interval between aspiration of organisms and the development of pneumonia varies from a few days up to 1 week. Pneumonia typically begins in dependent lobes at the periphery of the lung and, if untreated, spreads centripetally towards the hilum. If left untreated for the subsequent 2–5 days, an UPPE will likely develop. The effusion forms because of an increased capillary permeability secondary to endothelial injury induced by activated neutrophils, which release oxygen metabolites, granule constituents, and products of membrane phospholipases. The resultant extravascular lung water increases the interstitial-pleural pressure gradient and promotes a pleural effusion as fluid moves between mesothelial cells into the pleural space [10]. If interstitial fluid formation exceeds the capacity of the lung and pleural lymphatics, a pleural effusion will accumulate. If left untreated for the subsequent 5–10 days, the PPE transitions to the fibrinopurulent stage, which is characterized by the development of fibrinous adhesions, increased neutrophils, and the presence of bacteria. Fibrin forms as intravascular clotting proteins enter the pleural space, with con-

comitant inhibition of pleural space fibrinolysis. Fibroblasts enter the pleural space by 2 possible mechanisms: (1) movement of bone marrow fibrocytes to the site of inflammation, and (2) mesothelial cell transformation to fibroblasts by cytokines, such as basic fibroblast growth factor-2 [11]. Later in the fibrinopurulent stage, pus will be aspirated at thoracentesis; however, the lung is typically still expandable. As the fibrinopurulent stage progresses, it becomes increasingly unlikely that the patient can be successfully treated without pleural space drainage. If left untreated for the subsequent 10–21 days, the PPE will evolve into the final organizational or empyema stage, with evidence of lung entrapment due to visceral pleural fibrosis. Patients with empyema always require pleural space drainage for adequate resolution of pleural sepsis and often require decortication.

CLINICAL PRESENTATION

Unfortunately, the symptoms of pneumonia involving a PPE or empyema (i.e., fever, malaise, cough, dyspnea, and pleuritic chest pain) are similar to those of pneumonia without a PPE [1]. Elderly patients may be relatively asymptomatic, presenting only with fatigue or altered mental status, without pulmonary symptoms. Other factors, such as age, peak temperature, leukocyte count, or number of lobes involved, cannot predict the presence of a PPE or differentiate between persons with and persons without a PPE [1]. Furthermore, the clinical presentation is frequently similar to those for an UPPE or a CPPE.

The patient with empyema usually represents a neglected pleural infection. Patients who are hospitalized with a PPE and who receive appropriate antibiotic treatment rarely (<2%) develop empyema [5]. In a large study from the United Kingdom, patients presented to their physician 5 days after the onset of pneumonia symptoms, with an additional 13-day interval from

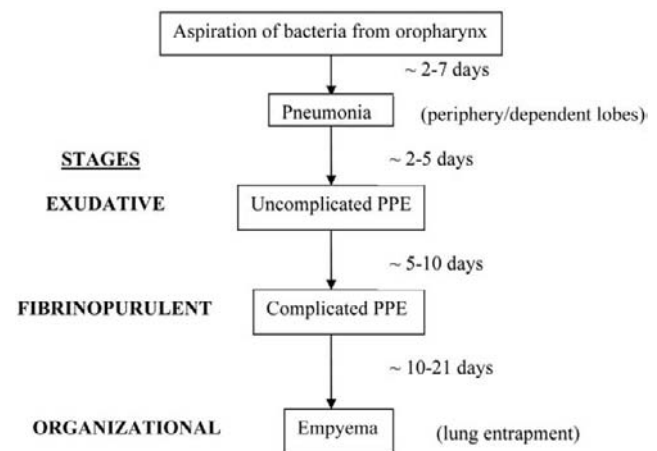


Figure 2. The estimated time course of untreated or inappropriately treated parapneumonic effusions. In general, an empyema will develop 4–6 weeks after the onset of aspiration of bacteria into the lung.

the time of the initial outpatient visit and admission to the hospital. The admitting physician considered pleural space infection in only 29 (17%) of 119 patients [5]. Delayed thoracentesis in the hospital is also associated with a prolonged hospital stay [12]. It is recommended that all patients with pneumonia be evaluated for the presence of pleural fluid. With the possible or definite presence of pleural fluid noted on a chest radiograph, an ultrasound-guided thoracentesis should be performed [13]. Ultrasonography can detect stranding or septation in the fluid suggestive of a CPPE and can facilitate its drainage (figure 3). However, if the patient is relatively asymptomatic and has only a minimal volume of fluid demonstrated by ultrasonography, observation is warranted.

Pleural fluid analysis allows the clinician to stage the PPE and guides initial management. As shown in table 1, a PPE can be reliably classified into UPPE, CPPE, or empyema on the basis of pleural fluid analysis. Although the nucleated cell count is typically elevated in a PPE, representing virtually all neutrophils, this finding cannot differentiate an UPPE from a CPPE. It has been shown clinically [1, 14, 15] and confirmed by meta-analysis [16] that a pleural fluid pH <7.28 strongly suggests that pleural space drainage is necessary for a good outcome; a pleural fluid glucose level <40 mg/dL or a ratio of pleural fluid to serum glucose <0.5 and a pleural fluid lactate dehydrogenase (LDH) level >1000 IU/L also suggest the need for drainage. UPPEs have a turbid appearance, with a pH >7.30, a glucose level >60 mg/dL, an LDH level <700 IU/L, and negative microbiologic test results. In contrast, CPPEs are associated with a pleural fluid pH <7.20 (CPPEs with a pH <7.30 has been documented on numerous occasions [14, 15]), a glucose level <40 mg/dL, and an LDH level >1000 IU/L; Gram stain and culture results may be positive. Pus aspirated from the pleural space is diagnostic of empyema, and the patient always requires drainage. Culture of an empyema specimen may yield negative results if the patient has been treated with antibiotics or cultures were not processed optimally. The bacteriologic yield of empyema fluid or CPPE specimens could be improved by bedside inoculation into the culture medium [17].

In patients with a CPPE or empyema, chest CT can demonstrate pleural abnormalities at an early stage; the use of contrast provides the best visualization of the pleural space because of pleural enhancement [18]. Chest CT can distinguish pleural from parenchymal abnormalities, determine the precise location and extent of the pleural disease, detect loculations, and find airway and parenchymal abnormalities that may be relevant to the etiology of the pleural infection. If a chest tube has been placed, its precise location can be documented [18].

MANAGEMENT

The management of a PPE should proceed with a sense of urgency. It is important for the clinician to have a management

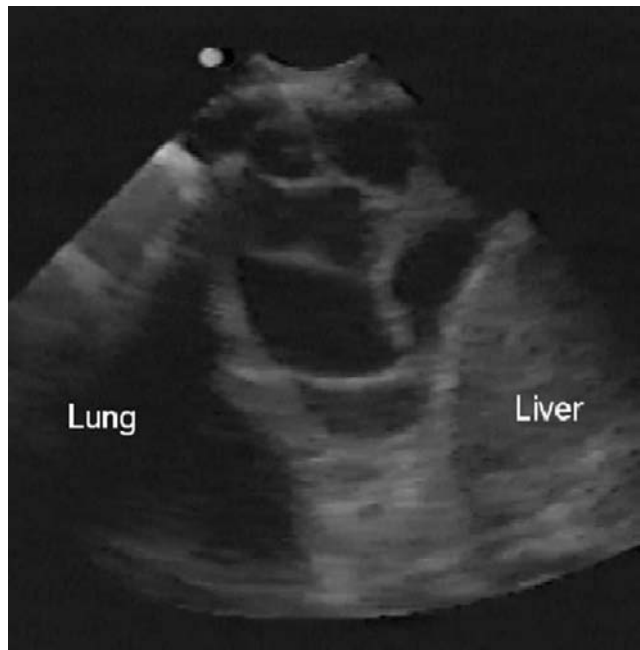


Figure 3. A complex, septate pleural effusion demonstrated by ultrasonography in a patient with spontaneous hemorrhage into a pre-existing pleural effusion. This precise pattern is typical of a complicated parapneumonic effusion as well. (Reprinted from [13] with permission.)

plan that limits any delay in invasive treatment. In general, early and appropriate antibiotic treatment will prevent the development of a PPE and its progression. Therefore, “the sun should never set on a parapneumonic effusion” [19]. A PPE is one of the few clinical situations (others include suspected hemothorax and esophageal rupture) in which a diagnostic thoracentesis should be performed as soon as possible. There should be timely escalation of treatment, if the PPE progresses with continued pleural sepsis. Unfortunately, management decisions must be based primarily on case studies, expert consensus, and clinical judgment. I tend to be more aggressive in escalating management if the patient has significant comorbidities [16]. Failure to treat elderly persons who have a CPPE or empyema substantially increases the risk of death.

Antibiotic therapy. Early antibiotic therapy will prevent the development of a PPE and its progression to a CPPE and empyema. Virtually all antibiotics have good pleural fluid penetration, with pleural fluid to serum levels generally exceeding 1.0 [20], with pleural fluid antibiotic concentrations usually exceeding the accepted MIC breakpoint for organisms most likely to cause empyemas [20, 21]. Aminoglycosides appear to be inactivated by the low pH and oxygen environment of an empyema [22]. Patients with empyema—particularly those who have an altered mental status, esophageal disease, or a history of alcoholism—should be treated with antibiotics that have anaerobic coverage. Anaerobes play an important role in pleural space infection because of their indolent course, as the patient

Table 1. Findings of pleural fluid analysis in parapneumonic effusions.

| Characteristic | Uncomplicated parapneumonic effusion | Complicated parapneumonic effusion | Empyema |
|---|--------------------------------------|------------------------------------|-----------------|
| Appearance | Slightly turbid | Cloudy | Pus |
| Biochemistry values | | | |
| pH | >7.30 | <7.20 | NA |
| Glucose level, mg/dL | >60 | <40 | |
| Ratio of pleural fluid to serum glucose | >0.5 | <0.5 | NA |
| Lactate dehydrogenase level, U/L | <700 | >1000 | NA |
| Polymorphonuclear leukocyte count, cells/ μ L | <15,000 | >25,000 | NA |
| Microbiologic test result | Negative | May be positive | May be positive |

NOTE. NA, not applicable.

presents 10–14 days after aspiration of anaerobes into the lung with either a necrotizing pneumonia, lung abscess, or empyema [2]. The antibiotic selection should be based on clinical factors and guidelines for treatment of pneumonia [7, 23].

Pleural space drainage. Clinical factors that suggest the need for pleural space drainage include prolonged pneumonia symptoms [3], comorbid disease [16], failure to respond to antibiotic therapy, and presence of anaerobic organisms [2]. Chest radiograph findings that suggest the need for pleural space drainage include an effusion involving >50% of the hemithorax [5], loculation, and an air-fluid level. Stranding or septation noted on an ultrasound suggests the need for pleural space drainage [13]; marked pleural enhancement, pleural thickening, and the split pleura sign noted by chest CT indicate the necessity for pleural space drainage [18]. The split pleura sign clearly demarcates loculations, because both the visceral and parietal pleurae are enhanced from the inflammatory process. Aspiration of pus, a putrid odor associated with an anaerobic infection, a positive Gram stain or culture result, pH <7.20, a glucose level <40 mg/dL, and an LDH level >1000 IU/L all support the need to drain the pleural space [1, 14–16]. A consensus statement published by the American College of Chest Physicians in 2000 recommended drainage of a PPE when there was a risk for a poor outcome (table 2) [24].

The options for pleural space drainage include repeated thoracentesis, use of a standard chest tube, or an image-guided insertion of a small-bore catheter. A number of nonrandomized studies have reported a variable success rate (24%–94%) and a mortality rate of 0%–25% associated with repeated thoracentesis [25, 26]. Standard chest tubes (size, 26–32 F) are often placed without ultrasound or CT guidance by thoracic surgeons for the treatment of CPPE and empyema; success rates range from 6% to 76%, with mortality rates of 0%–24% [5, 27, 28]. Drainage failure is a consequence of misplacement of the chest tube, tube malfunction, and loculations. Complications of use of standard chest tubes include pain, pneumothorax, hemorrhage, and subcutaneous emphysema.

Small-bore catheters (size, 8–14 F), which are more frequently used presently, can be placed under ultrasound or CT guidance. Their primary indication is for small, inaccessible, multiple-loculated effusions and nonloculated, nonpurulent effusions; however, these catheters have also been successful in draining empyemas. The variation in success rates for these catheters (72%–82%) is associated with patient selection, operator expertise, and the stage of the PPE [29–32]. The major advantage of small-bore catheters is better patient tolerance and avoidance of major complications. In addition, a small-bore catheter placed with the Seldinger technique, when used for an initial thoracentesis, can be left in place for continued drainage or removed after complete drainage if the fluid is nonpurulent and the pH is >7.30.

Intrapleural fibrinolytics. In 2004, *The Cochrane Database Review* stated that, although the evidence suggests that intrapleural fibrinolysis can be considered an important adjunctive therapy to tube drainage on the basis of evidence from randomized, controlled trials alone, routine use was not recommended for the management of CPPE and empyema, because the number of cases was too small [33]. They opined that streptokinase (no longer available as a result of a lack of market demand) and urokinase were equally efficacious and that life-threatening complications were not reported in any of the randomized, controlled trials.

Maskell et al. [34] reported the results of a large (427 patients), multicenter, randomized, double-blind trial in the United Kingdom that showed no advantage of streptokinase over saline with regard to mortality rates or the need for surgery at 3 or 12 months in patients who had empyema (83%) and whose time to randomization (~14 days) was prolonged. In a single-center, randomized, double-blind trial, 44 patients (81% of whom had empyema) were randomized to receive either streptokinase (250,000 U per day) or saline for 4–5 days. At day 7, the streptokinase group had fewer referrals for surgery (43% vs. 9%; $P = .02$) and a better clinical success rate (82% vs. 48%; $P = .02$) [35].

Table 2. Risk for a poor outcome of a parapneumonic effusion.

| Pleural fluid volume and configuration | Characteristic | | | Drainage requirement |
|---|-------------------------------|---------|----------|----------------------|
| | Bacteriologic test data | pH | Risk | |
| Minimal, free-flowing fluid | Unknown | Unknown | Very low | No |
| Free-flowing effusion involving $\leq 50\%$ of the hemothorax | Negative result | >7.20 | Low | No |
| Effusion involving $>50\%$ of the hemothorax or loculated configuration | Positive GS or culture result | <7.20 | Moderate | Yes |
| Irrelevant | Finding of pus | NA | High | Yes |

NOTE. Data are from [24], used with permission. GS, Gram stain; NA, not applicable.

The current indications for intrapleural fibrinolytics include an occluded small-bore catheter, decrease or cessation of pleural fluid drainage in the context of a complex pleural space, a multiloculated pleural space, and as a trial before committing the patient to surgery. Fibrinolytic agents would probably be most effective in the early fibrinolytic stage in avoiding the need for surgical drainage.

Currently, the only fibrinolytic agents available in the United States are urokinase [36–38] and tissue plasminogen activator [39–42]. The typical dosage of urokinase is 100,000 U once or twice per day (the cost per 250,000-U vial is ~\$465). Tissue plasminogen activator has been used in both pediatric and adult patients at dosages ranging from 2 to 16 mg per day, with 10 mg being the most common dose (the cost of a 10-mg dose ~\$460). Ongoing studies of CPPE in the United Kingdom include a multicenter, 4-arm trial comparing tissue plasminogen activator with and without DNase [43] and a European trial comparing fibrinolytics and thoracoscopy.

Surgery. Surgical options include thoracoscopy, both medical and video-assisted thoracic surgery (VATS), standard thoracotomy, and open drainage. The decision for surgery should

be made as soon as it is obvious that pleural space drainage by tube thoracostomy has been ineffective in controlling the pleural infection. In patients with an empyema that has been present for several days to weeks and that has multiple loculations, surgery should be recommended as soon as possible if the patient is a good candidate. Some patients with impaired pulmonary function and debilitation can be treated effectively with VATS (figure 4). Patients with a CPPE can be sent directly to surgery or treated with a 72-h trial of fibrinolytics. If fibrinolytics do not improve drainage, decrease temperature, and lower the leukocyte count, surgery should be strongly considered. However, it should be recognized that, with clinical improvement, despite an abnormal pleural space, observation may be warranted. There are patients who refuse surgery, despite minimal clinical improvement, who over several weeks to months have complete lung re-expansion without pleural space sequelae.

Seven studies evaluating VATS in CPPE (with a total of 440 patients from the period 1996–2006) yielded an overall success rate of 86% [45–51]. This high success rate was primarily generated by the largest study (234 patients), which was by Luh et

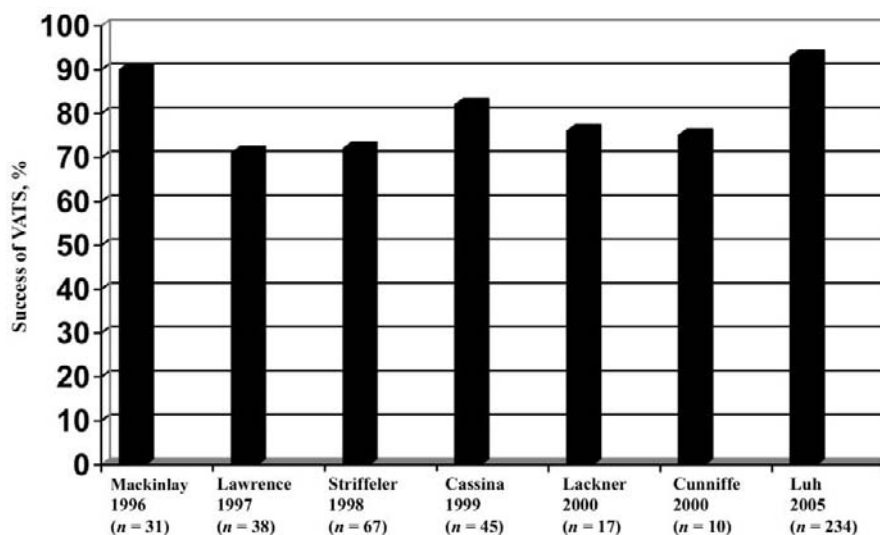


Figure 4. Success rates for video-assisted thoracic surgery (VATS) for treatment of complicated parapneumonic effusions in 7 studies that involved a total of 440 patients, 1996–2005. The overall success rate for VATS was 86%.

al. [50], who reported a success rate of 88%. VATS, the procedure of choice after fibrolysis has failed, requires single lung ventilation, general anesthesia, operator expertise, and availability. In these 440 patients, conversion to thoracotomy was required in 4%–30% and varied with patient selection [44–50].

Open thoracotomy for CPPE and empyema is recommended for persistent pleural sepsis and failure of less invasive procedures to control the infection [44, 51, 52]. Conversion to thoracotomy can be effective when VATS cannot adequately access the pleural space [44, 51–53] and is the optimal method for successful debridement and decortication. However, decortication is a major operation and can often not be performed in debilitated patients. Decortication (i.e., stripping of the visceral pleural peel) can be performed early to control pleural sepsis and late (3–6 months after the onset of empyema or CPPE) to treat a symptomatic, restrictive ventilatory defect. The success rate of standard thoracotomy for CPPE and empyema is 87%–100%, with the mortality rate ranging from 0% to 9% [44, 51, 52]. Open drainage for empyema is an alternative to decortication in the debilitated patient who cannot undergo a standard thoracotomy [53].

CONCLUSIONS

The outcome of a PPE depends on the point in the clinical course when the patient presents to the physician, comorbidities, and efficient clinical management. Early antibiotic therapy prevents the development of a PPE and progression to a CPPE and empyema. All patients with pneumonia should be evaluated for a PPE, and thoracentesis should be performed without delay if the amount of fluid is more than minimal. Pleural fluid analysis, performed with a small-bore catheter, will provide diagnostic information and guide therapy; the pleural space should be drained as completely as possible. If the fluid is deemed uncomplicated by appearance, a pH >7.30, and other clinical and radiographic features, the catheter should be removed. If the nonpurulent fluid has characteristics suggestive of a CPPE, the catheter should be left in place for continued drainage. Fibrinolytics are most likely to be effective in the early fibrinopurulent stage. If pleural drainage is ineffective, VATS should be performed without delay. Decortication should be considered with an unexpandable lung, multiple loculations, and continued pleural sepsis. If the patient is too debilitated for VATS or standard thoracotomy, open drainage should be considered.

Acknowledgments

Potential conflicts of interest. S.A.S.: no conflicts.

References

1. Light RW, Girard WN, Jenkinson SG, George RB. Parapneumonic effusions. *Am J Med* **1980**;69:507–12.
2. Bartlett JG, Finegold SM. Anaerobic infections of the lung and pleural space. *Am Rev Resp Dis* **1974**;110:56–77.
3. Taryle DA, Potts DE, Sahn SA. The incidence and clinical correlates of parapneumonic effusions in pneumococcal pneumonia. *Chest* **1978**;74:170–3.
4. Strange C, Sahn SA. The definition and epidemiology of pleural space infections. *Semin Respir Infec* **1999**;14:3–8.
5. Ferguson AD, Prescott RJ, Selkon JB, Watson D, Swinburn CR. The clinical course and management of thoracic empyema. *QJM* **1996**;89:285–9.
6. Fine NL, Smith LR, Sheedy PF. Frequency of pleural effusion in mycoplasma and viral pneumonias. *N Eng J Med* **1970**;283:790–3.
7. Niederman MS, Mandel LA, Ansueto A, et al. Guidelines for the management of adults with community-acquired pneumonia: diagnosis, assessment of severity, antimicrobial therapy, and prevention. *Am J Respir Crit Care Med* **2001**;163:1730–54.
8. Hasley PB, Albaum MN, Li Y-H, et al. Do pulmonary radiographic findings at presentation predict mortality in patients with community-acquired pneumonia? *Arch Intern Med* **1996**;156:2206–212.
9. Jerng JS, Hsueh PR, Teng, LJ, Lee LN, Yang PC, Luh KT. Empyema, thoracic, and lung abscess caused by *viridans streptococci*. *Am J Respir Crit Care Med* **1997**;156:1508–14.
10. Sahn SA. Management of complicated parapneumonic effusions. *Am Rev Resp Dis* **1993**;148:813–7.
11. Strutz F, Zeisberg M, Ziyadeh FN, et al. Role of basic fibroblast growth factor-2 in epithelial-mesenchymal transformation. *Kidney Int* **2002**;61:1714–28.
12. Heffner JE, McDonald J, Barbieri C, Klein J. Management of parapneumonic effusions: an analysis of physician practice patterns. *Arch Surg* **1995**;130:433–8.
13. Mayo PH, Doelken P. Pleural ultrasonography. *Clin Chest Med* **2006**;27:215–27.
14. Potts DE, Levin DC, Sahn SA. Pleural fluid pH in parapneumonic effusions. *Chest* **1976**;70:326–31.
15. Potts DE, Taryle DA, Sahn SA. The glucose-pH relationship in parapneumonic effusions. *Arch Intern Med* **1978**;138:1378–80.
16. Heffner JE, Brown LK, Barbieri C, DeLeo JM. Pleural fluid chemical analysis in parapneumonic effusions: a meta-analysis. *Am J Respir Crit Care Med* **1995**;151:1700–8.
17. Runyon BA, Antillon MR, Akeviadis EA, McHutchison JG. Bedside inoculation of blood culture bottles with ascitic fluid is superior to delayed inoculation in the detection of spontaneous bacterial peritonitis. *J Clin Microbiol* **1990**;28:2811–2.
18. Qureshi NR, Gleeson FV. Imaging of pleural disease. *Clin Chest Med* **2006**;27:193–213.
19. Sahn SA, Light RW. The sun should never set on a parapneumonic effusion. *Chest* **1989**;95:945–7.
20. Taryle DA, Good JT, Morgan EJ, Weller LB, Sahn SA. Antibiotic concentrations in human parapneumonic effusions. *Antimicrob Agents Ch* **1981**;7:171–7.
21. Hughes CE, Vanscoy RE. Antibiotic therapy of pleural empyema. *Semin Respir Infec* **1991**;6:94–102.
22. Shohet I, Yellin A, Meyerovitch J, Rubinstein E. Pharmacokinetics and therapeutic efficacy of gentomycin and an experimental empyema rabbit model. *Antimicrob Agents Chemother* **1987**;31:982–5.
23. Mandell LA, Wunderink RG, Anzueto A, et al. Infectious Diseases Society of America/American Thoracic Society consensus guidelines on the management of community-acquired pneumonia in adults. *Clin Infect Dis* **2007**;44:S27–72.
24. Colice GL, Curtis A, Deslauriers J, et al. Medical and surgical treatment of parapneumonic effusions: an evidence-based guideline. *Chest* **2000**;118:1158–71.
25. Mandal AK, Thadepalli H. Treatment of spontaneous bacterial empyema thoracis. *J Thorac Cardio Surg* **1987**;94:414–8.
26. Storm HK, Krasnik M, Bang K, Frimodt-Moler M. Treatment of pleural empyema secondary to pneumonia: thoracentesis regimen versus tube drainage. *Thorax* **1992**;47:821–4.

27. Hoover EL, Hsu HK, Webb H, Toporoff B, Minnard E, Cunningham JN. The surgical management of empyema thoracis in substance abuse patients: a 5-year experience. *Ann Thorac Surg* **1988**;46:563-6.
28. Huang HC, Chang HW, Chen CW, Lee CH, Hsiue TR. Predicting factors for outcome of tube thoracostomy in complicated parapneumonic effusion or empyema. *Chest* **1999**;115:751-6.
29. Merriam MA, Cronan JJ, Gorfman GS, Lambiase RE, Haas RA. Radiographically guided percutaneous catheter drainage of pleural fluid collections. *AJR Am J Roentgenol* **1988**;151:1113-6.
30. Silverman SG, Mueller PR, Saini S, et al. Thoracic empyema: management with image-guided catheter drainage. *Radiology* **1988**;169:5-9.
31. Shankar S, Gulati M, Kang M, Gupta S, Suri S. Image-guided percutaneous drainage of thoracic empyema, can sonography predict the outcome? *Eur Radiol* **2000**;10:495-9.
32. Ulmer JL, Choplin RH, Reed JC. Image-guided catheter drainage of the infected pleural space. *J Thorac Imaging* **1991**;6:65-73.
33. Cameron R, Davies HR. Intra-pleural fibrinolytic therapy versus conservative management in the treatment of parapneumonic effusions and empyema. *Cochrane Database Syst Rev* **2004**;2:CD002312.
34. Maskell NA, Davies CWH, Nunn AJ, et al. UK controlled trial of intrapleural streptokinase for pleural infection. *N Engl J Med* **2005**;352:865-74.
35. Diacon AH, Theron J, Schuurmans MN, VanDeWal BW, Bollinger CT. Intrapleural streptokinase for empyema in complicated parapneumonic effusions. *Am J Respir Crit Care Med* **2004**;170:49-53.
36. Bouros D, Schiza S, Patsourakis G, Chalkiadakis G, Panagou P, Siafakas NM. Intrapleural streptokinase versus urokinase in the treatment of complicated parapneumonic effusions: a prospective, double-blind study. *Am J Respir Crit Care Med* **1997**;155:291-5.
37. Temas RT, Follis F, Kessler RM, Pett SB Jr, Wernly JA. Intrapleural fibrinolytics in the management of empyema thoracis. *Chest* **1996**;110:102-6.
38. Moulton JS, Moore PT, Mancini RA. Treatment of loculated pleural effusions with transcatheter intracavitary urokinase. *AJR Am J Roentgenol* **1989**;153:941-5.
39. Bishop NB, Pon S, Ushay HM, Greenwald DM. Alteplase in the treatment of complicated parapneumonic effusions: a case report. *Pediatrics* **2003**;111:e188-90.
40. Skeete DA, Rutherford EJ, Schlidt SA, Abrams JE, Parker LA, Rich PB. Intrapleural tissue plasminogen activator for complicated pleural effusions. *J Trauma* **2004**;57:1178-83.
41. Weinstein M, Restrepo R, Chait PG, Connolly B, Tintal M, MacArthur C. Effectiveness and safety of tissue plasminogen activator in the management of complicated parapneumonic effusions. *Pediatrics* **2004**;113:e181-5.
42. Ray TL, Berkendosch JW, Russo P, Tobias JD. Tissue plasminogen activator as an adjunct therapy for pleural empyema in pediatric patients. *J Intensive Care Med* **2004**;19:44-50.
43. Light RW. Parapneumonic effusions and empyema. *Proc Am Thorac Soc* **2006**;3:75-80.
44. Mackinlay TAA, Lyons GA, Chimondeguy DJ, Piedras MAB, Angeramo G, Emery J. VATS debridement versus thoracotomy in the treatment of loculated postpneumonia empyema. *Ann Thorac Surg* **1996**;61:1626-30.
45. Lawrence DR, Ohri SK, Moxon RE, Townsend ER, William S. Fountainthoracoscopic debridement of empyema thoracis. *Ann Thorac Surg* **1997**;64:1448-50.
46. Striffeler H, Gugger M, Im Hof VI, Cerny A, Furrer M, Ris HB. Video-assisted thoracoscopic surgery for fibrinopurulent pleural empyema in 67 patients. *Ann Thorac Surg* **1998**;65:319-23.
47. Cassina PC, Hauser M, Hillejan L, Greschuchna D, Stamatis G. Video-assisted thoracoscopy in the treatment of pleural empyema: stage-based management and outcome. *J Thorac Cardiovasc Surg* **1999**;117:234-8.
48. Lackner RP, Hughes R, Anderson LA, Sammut PH, Thompson AB. Video-assisted evacuation of empyema is the preferred procedure for management of pleural space infections. *Am J Surg* **2000**;179:27-30.
49. Cunniffe MG, Maguire D, McAnena OJ, Johnston S, Gilmartin JJ. Video-assisted thoracoscopic surgery in the management of loculated empyema. *Surg Endosc* **2000**;14:175-8.
50. Luh SP, Chou MC, Wang LS, Chen JY, Tsai TP. Video-assisted thoracoscopic surgery in the treatment of complicated parapneumonic effusions or empyemas: outcome of 234 patients. *Chest* **2005**;127:1427-32.
51. Chen KY, Hsueh PR, Liaw YS, Yang PC, Luh KT. A 10-year experience with bacteriology of acute thoracic empyema. *Am Surg* **1985**;51:230-6.
52. Muskett A, Burton NA, Karwande SV, Collins MP. Management of refractory empyema with early decortication. *Am J Surg* **1988**;156:529-32.
53. Deslauriers J, Jacques LF, Gregorie J. Role of Eloesser flap in thoracoplasty in the third millennium. *Chest Surg Clin North Am* **2002**;12:605-23.