

Case Report

Rapamycin reduces kidney volume and delays the loss of renal function in a patient with autosomal-dominant polycystic kidney disease

Ramón Peces¹, Carlos Peces², Virginia Pérez-Dueñas³, Emilio Cuesta-López³, Sebastián Azorín¹ and Rafael Selgas¹

¹Servicio de Nefrología, Hospital Universitario La Paz, Madrid, ²Area de Tecnología de la Información, SESCAM, Toledo and

³Servicio de Radiología, Hospital Universitario La Paz, Madrid, Instituto Reina Sofía de Investigación Nefrológica, Spain

Abstract

This is the first report of a case of a reduction in kidney volume and preservation of renal function in a patient with autosomal-dominant polycystic kidney disease (ADPKD) receiving rapamycin. A 42-year-old man with ADPKD and a severe persistent bleeding from his solitary left kidney was successfully treated with tranexamic acid (TXA). He also received low-dose rapamycin for 8 months, and this was associated with a 23.5% reduction in kidney volume, improvement and stabilization of renal function, and normalization of haemoglobin levels. When treatment with rapamycin was interrupted, renal function deteriorated within an 8-month period and haemodialysis (HD) became necessary. Kidney volume increased at once, and life-threatening bleeding prompted a nephrectomy 4 months after the onset of HD. These data suggest that the reduction in kidney volume and preservation of renal function with rapamycin could be the result of the antiangiogenic, antiproliferative effects of rapamycin.

Keywords: ADPKD; mTOR; rapamycin; renal function; volume change

Introduction

Kidney enlargement resulting from the expansion of cysts in patients with ADPKD is continuous and quantifiable and is associated with a reduction in renal function. A baseline total kidney volume above 1500 ml is associated with an increase in total kidney volume of $6.76 \pm 3.78\%$ per year and a decrease in the glomerular filtration rate of 5.04 ± 5.86 ml/min/year [1]. Higher rates of kidney enlargement are associated with a more rapid decrease in renal function. ADPKD may become symptomatic with acute complications such as cyst haemorrhage, rupture and infection.

Correspondence and offprint requests to: Ramón Peces, Servicio de Nefrología, Hospital Universitario La Paz, Paseo de la Castellana 261, 28046 Madrid, Spain. Tel: +34-917277151; Fax: +34-917277382; E-mail: cpeces@varnet.com

ADPKD subjects with more episodes of gross haematuria have a larger renal size and higher serum creatinine levels than those with fewer episodes [2]. Currently, apart from invasive interventions such as embolization or removal of the entire kidney, no medical treatment for ADPKD patients with severe bleeding from the polycystic kidney is available. However, the observation that renal size correlates with the risk of cyst haemorrhage suggests that pharmacotherapy that reduces renal size may reduce the risk of bleeding.

Rapamycin, an inhibitor of the mammalian target of rapamycin (mTOR), has proven highly effective in reducing renal cystogenesis and loss of renal function in animal models of polycystic kidney disease (PKD) [3–5]. In addition, using rapamycin to treat transplant recipients suffering from ADPKD has resulted in a significant reduction in native polycystic kidney size [5]. More recently, rapamycin has also reduced polycystic liver volume in ADPKD transplant recipients [6]. However, the effect of low-dose rapamycin in kidney volume and renal function of nontransplanted ADPKD patients with chronic renal failure has not been established.

Case

A 42-year-old man with ADPKD presented in October 2004 with persistent severe macroscopic haematuria. Computerized tomography (CT) of the abdomen showed bleeding from the right kidney. He underwent nephrectomy of the right polycystic kidney (weight 700 g) and his postoperative serum creatinine level remained stable at ~ 2.6 mg/dl. In June 2006, the patient presented with persistent macroscopic haematuria from his left kidney. Magnetic resonance imaging (MRI) of the abdomen showed a left kidney (size, $17 \times 11.5 \times 10$ cm) with multiple cysts of different sizes scattered throughout the parenchyma. Some cysts showed evidence of recent bleeding. Renal function deteriorated and serum creatinine increased from 4.2 to 5.4 mg/dl. The haematuria could not be controlled by intensive conservative treatment, and an emergency nephrectomy was proposed when the bleeding became life threatening.

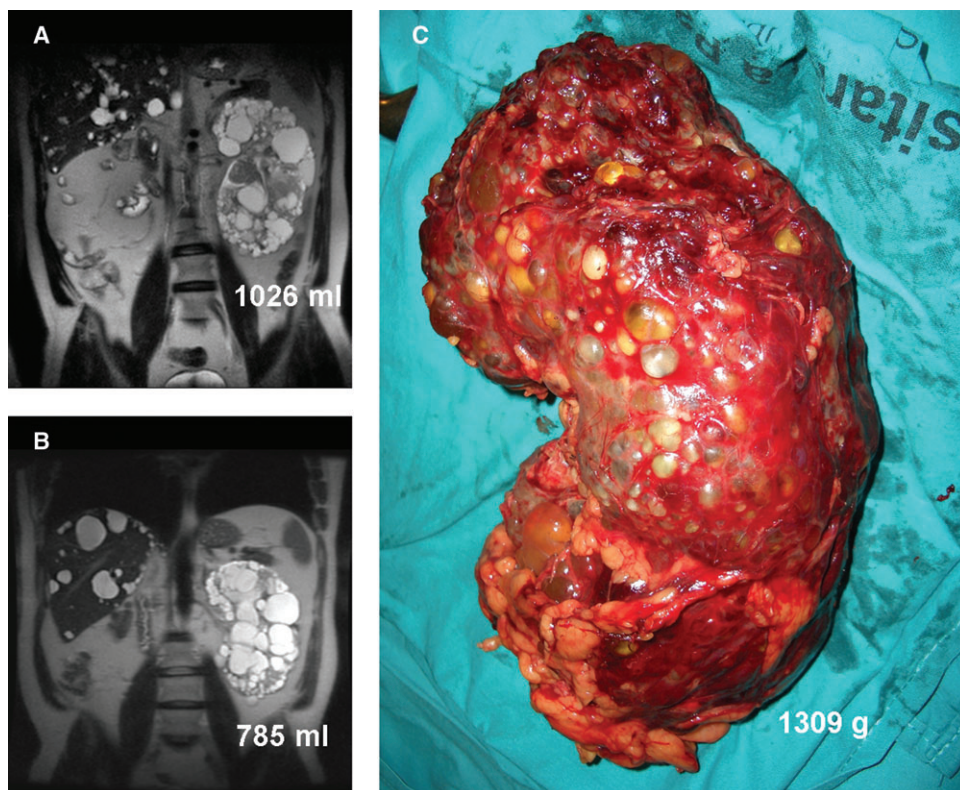


Fig. 1. Coronal MRI of a patient with ADPKD, before (A) and after (B) 6-months treatment with low-dose rapamycin. (C) Macroscopic view of the left kidney after nephrectomy.

Arterial embolization was also considered, but refused by the patient. We tried treatment with four doses of recombinant factor VII (Novoseven[®], Novo Nordisk, Spain), although this was unsuccessful. Since local and systemic hyperfibrinolysis play a role in bleeding in ADPKD patients, we administered intravenous TXA (Amchafibrin[®], Rottapharm, Spain) at a dose of 1 g/8 h. The massive bleeding promptly stopped, and haematuria gradually ceased. The haemoglobin level and renal function subsequently stabilized with serum creatinine at about 4.8 mg/dl and creatinine clearance of 13 ml/min. Because animal and human trials of PKD have shown an effect of rapamycin on renal cysts, our patient was administered rapamycin (1 to 2 mg/day) orally for 8 months. Informed consent for off-label therapy (compassionate use) with rapamycin during this period was obtained. The treatment was well tolerated. Renal function, haemoglobin level, blood rapamycin levels and total kidney volume measured by MRI were monitored throughout the treatment phase. The initial renal volume was 1026 ml and the final renal volume 785 ml, that is, a volume change of -241 ml (-23.5%) within 6 months (Figure 1A and B). During this time, renal function and haemoglobin level improved and remained stable (Table 1). According to the study protocol, in February 2007 rapamycin was stopped after 8 months of continuous treatment. Renal function declined progressively, and HD was initiated in October 2007. The restoration of rapamycin was refused by the patient. In January 2008, 4 months after HD was started, the patient presented with persistent se-

Table 1. Laboratory values of an ADPKD patient treated for 8 months with rapamycin

Date	Cr (mg/dl)	Cr Cl (ml/min)	Hb (g/dl)	Rapamycin dose (mg/day)	Rapamycin levels (ng/ml)
21 June 2006	4.8	13	10	–	–
4 July 2006	4.4	15	11.5	1	–
28 July 2006	4.3	16	12.8	1	1.5
8 August 2006	4.1	16	12.8	2	2.4
17 August 2006	3.8	18	13.6	2	3.4
5 September 2006	3.7	19	11.8	2	10
20 September 2006	3.5	20	12.2	1	2.1
26 October 2006	3.6	17	13	1	2.6
20 December 2006	3.9	17	14.7	1	–
1 February 2007	4.4	16	13.5	1	2.9

vere haematuria. By January 2008, the kidney volume had increased to 1409 ml (volume change $+624$ ml, $+44\%$) showing multiple cysts with evidence of bleeding. In February 2008, the haematuria became life threatening and the kidney was removed (weight 1309 g) (Figure 1C). The change in kidney volume during and after rapamycin is represented in Figure 2.

Discussion

Currently, there is no effective treatment available to retard cyst growth and to prevent progression to end-stage renal

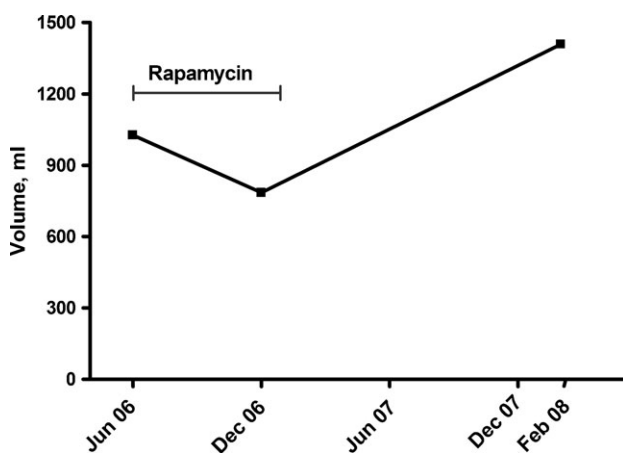


Fig. 2. Change in kidney volume. Rapamycin was administered from July 2006 to February 2007.

failure in patients with ADPKD. Evidence has recently been obtained from animal experiments that activation of the mTOR signaling pathway plays a crucial role in cyst growth and increase in renal volume, and that the inhibition of mTOR with rapamycin markedly slows cyst development and deterioration of renal function [3–5]. On the other hand, several clinical trials are now testing a host of therapeutic interventions in patients with ADPKD [7,8]. Their results may improve our therapeutic approach to this disease and allow us to confirm its effect on cyst growth and on renal function.

Although a reduction in end-stage kidney volume of $24.8 \pm 9.7\%$ has previously been reported in ADPKD renal transplant recipients receiving rapamycin as an immunosuppressive agent [5], to our knowledge, this is the first case of a reduction in kidney volume associated with preservation of renal function in a nontransplanted ADPKD patient with chronic renal failure receiving rapamycin. In addition, removal of a solitary kidney was prevented and initiation of HD was delayed for 16 months.

The therapeutic options to control severe bleeding from the polycystic kidney are limited. We show that it is reasonable to try antifibrinolytic treatment with TXA in such devastating uncontrolled bleeding [9,10]. Moreover, low-dose rapamycin reduced the total kidney volume and delayed the loss of renal function in our patient. The fact that there were no further episodes of bleeding during treatment reinforces the concept that rapamycin affects cyst growth and its consequences. Thus, the absence of further episodes of cystic bleeding could partly account for the observed efficacy of rapamycin in a kidney volume reduction. An antiproliferative and antiangiogenic role has been suggested [11], although its ability to reduce the risk of haemorrhagic complications from renal cysts has not been established. These

findings are preliminary and do not in themselves prove the efficacy of mTOR inhibition for the treatment of ADPKD-associated cystic bleeding. However, the increase in kidney volume when treatment was discontinued, followed by recurrence of cystic bleeding when HD was initiated, provides compelling circumstantial evidence.

In conclusion, severe persistent bleeding from a solitary kidney in a patient with ADPKD was successfully treated with TXA. Moreover, treatment with a low dose of rapamycin for 8 months resulted in a decrease in kidney volume and preservation of renal function in this non-transplanted ADPKD patient with chronic renal failure. Rapamycin could prove useful for retarding progressive renal failure in patients with ADPKD. These results, although encouraging, require confirmation and further elucidation by subsequent prospective trials.

Conflict of interest statement. None declared.

References

1. Grantham JJ, Torres VE, Chapman AB *et al.* CRISP Investigators. Volume progression in polycystic kidney disease. *N Engl J Med* 2006; 354: 2122–2130
2. Gabow PA, Duley I, Johnson AM. Clinical profiles of gross hematuria in autosomal dominant polycystic kidney disease. *Am J Kidney Dis* 1992; 20: 140–143
3. Tao Y, Kim J, Schrier RW *et al.* Rapamycin markedly slows disease progression in a rat model of polycystic kidney disease. *J Am Soc Nephrol* 2005; 16: 46–51
4. Wahl PR, Serra AI, Le Hir M *et al.* Inhibition of mTOR with sirolimus slows disease progression in Han:SPRD rats with autosomal dominant polycystic kidney disease (ADPKD). *Nephrol Dial Transplant* 2006; 21: 598–604
5. Shillingford JM, Murcia NS, Larson CH *et al.* The mTOR pathway is regulated by polycystin-1, and its inhibition reverses renal cystogenesis in polycystic kidney disease. *Proc Natl Acad Sci USA* 2006; 103: 5466–5471
6. Qian Q, Du H, King BF *et al.* Sirolimus reduces polycystic liver volume in ADPKD patients. *J Am Soc Nephrol* 2008; 19: 631–638
7. Serra AL, Kistler AD, Poster D *et al.* Clinical proof-of-concept trial to assess the therapeutic effect of sirolimus in patients with autosomal dominant polycystic kidney disease: SUISE ADPKD study. *BMC Nephrol* 2007; 8: 13
8. Ruggenti P, Remuzzi A, Ondei P *et al.* Safety and efficacy of long-acting somatostatin treatment in autosomal-dominant polycystic kidney disease. *Kidney Int* 2005; 68: 206–221
9. Vujkovic B, Sabovic M. A successful treatment of life-threatening bleeding from polycystic kidneys with antifibrinolytic agent tranexamic acid. *Blood Coagul Fibrinolysis* 2006; 17: 589–591
10. Downey P, Tagle R, Pereira J *et al.* Tranexamic acid and uremic bleeding: evidence-based treatment recommendations. *Nat Clin Pract Nephrol* 2007; 3: E2
11. Wei W, Popov V, Walocha JA *et al.* Evidence of angiogenesis and microvascular regression in autosomal-dominant polycystic kidney disease kidneys: a corrosion cast study. *Kidney Int* 2006; 70: 1261–1268

Received for publication: 27.8.08

Accepted in revised form: 22.12.08