

## Exceptional Case

# Discordant phenotypes in monozygotic twins with identical *de novo* *WT1* mutation

Zihua Yu<sup>1,2,3</sup>, Yonghui Yang<sup>1</sup> and Dongning Feng<sup>1</sup>

<sup>1</sup>Department of Pediatrics, Fuzhou Dongfang Hospital, Fuzhou, P. R. China, <sup>2</sup>Department of Pediatrics, Fuzhou Clinical Medical College, Fujian Medical University, Fuzhou, P. R. China and <sup>3</sup>Department of Pediatrics, Dongfang Hospital, Xiamen University, Fuzhou, Fujian, P. R. China

Correspondence and offprint requests to: Zihua Yu; E-mail: zihuayu@vip.sina.com

### Abstract

Mutations in the *WT1* gene, leading to Denys-Drash syndrome and Frasier syndrome, can also cause isolated steroid-resistant nephrotic syndrome (ISRNS). Previous studies have reported six pairs of monozygotic twins with *WT1* mutations, including one presenting with discordant phenotypes with identical *WT1* mutations being of paternal origin and five pairs of monozygotic twins presenting the same phenotype with identical *WT1* mutations. In this study, we report on female monozygotic twins showing discordant phenotypes with an identical *de novo* *WT1* mutation, R394W, and presenting incomplete Denys-Drash syndrome and ISRNS.

**Keywords:** Denys-Drash syndrome; steroid-resistant nephrotic syndrome; *WT1*

### Background

The *WT1* gene, located on chromosome 11p13, plays a crucial role in kidney and genital system development [1]. Recent studies have demonstrated that mutations in *WT1*, leading to Frasier syndrome and Denys-Drash syndrome (DDS), can also cause isolated steroid-resistant nephrotic syndrome (ISRNS) [2]. Incomplete DDS is characterized as a nephrotic syndrome associated with Wilms' tumor or male pseudohermaphroditism [3]. A previous study has reported one pair of monozygotic twins presenting discordant phenotypes with identical *WT1* mutations being of paternal origin [4]. Here, we report on discordant phenotypes in monozygotic twins with identical *de novo* *WT1* mutations.

### Case reports

Female monozygotic twins having very similar appearances and only one placenta were observed. Both twins had normal female phenotypes and karyotype 46, XX. Urinalyses of their parents and older sister were normal.

Twin A (Figure 1 (III4)) was admitted to the Department of Pediatrics, Fuzhou Dongfang Hospital, P. R. China for evaluation of edema at the age of two. A urine dipstick revealed 3+ albumin. Serum albumin was 22.8 g/L and creatinine 48 μmol/L. She failed to respond to 6 weeks of prednisone therapy (2 mg/kg/24 h). At the age of 3.49 years, she also presented with a right abdominal mass. Kidney ultrasound revealed a 9.85 cm by 8.32 cm Wilms' tumor in the right kidney, confirmed by computed tomography scan (Figure 2). She was diagnosed with incomplete DDS and died at the age of 3.50 years due to renal failure.

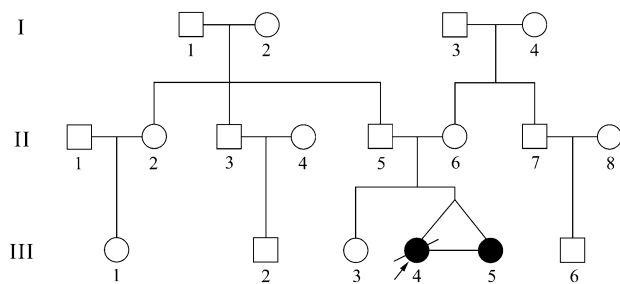
Twin B (Figure 1 (III5)) was examined at the age of two. Physical examination was unremarkable. A urine dipstick revealed 3+ albumin. Serum albumin was 25.3 g/L and creatinine 36 μmol/L. No therapeutic provision was implemented then because her parents refused to accept medical decision. She initially presented with eyelid edema at the age of 4.02 years. A urine dipstick revealed 3+ albumin. Serum albumin was 22 g/L and creatinine 42 μmol/L. She failed to respond to standard steroid therapy and was diagnosed with ISRNS. She had not displayed Wilms' tumor by kidney ultrasound by the age of 5.14 years, though her serum creatinine had increased to 66 μmol/L. She is now 5.85 years old and has not yet displayed Wilms' tumor, verified by both kidney ultrasound and computed tomography scan. Serum creatinine is 153 μmol/L.

With the subjects' informed consent, samples of blood were obtained for genetic analysis. A heterozygous variant in Exon 9 of *WT1*, 1180C > T, leading to an arginine to tryptophan substitution (R394W), was identified in both twins, whereas it was not found in 50 controls or the twins' parents or older sister. Three *WT1* polymorphisms, 126C > T, 903A > G and IVS7–32C > A, were also found in the twins.

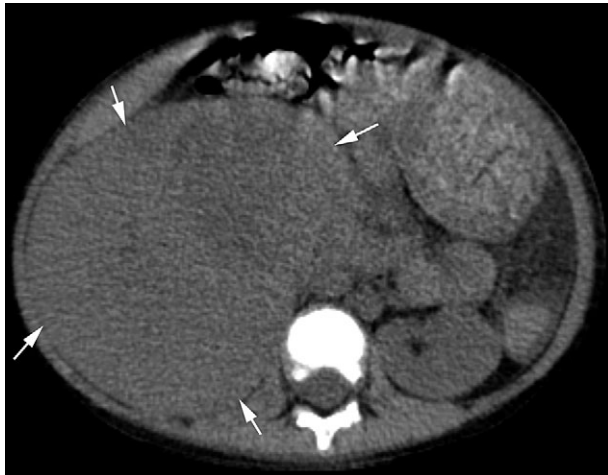### Discussion

In this study, we identified an identical *de novo* heterozygous *WT1* mutation, R394W, in monozygotic twins presenting with incomplete DDS and ISRNS, which was not observed in the parents. Previous studies have reported *WT1* mutation R394W can cause DDS or ISRNS [5]; therefore, we considered this mutation to be responsible for the phenotypes observed in the twins.

The twins, having very similar appearances, had only one placenta and three *WT1* polymorphisms, 126C > T,



**Fig. 1.** Pedigree of a Chinese family with steroid-resistant nephrotic syndrome.



**Fig. 2.** Abdominal computed tomography scan of Twin A at the age of 3.49 years, showing Wilms' tumor in right kidney (arrows).

903A > G and IVS7-32C > A, suggesting that they were monozygotic twins.

The twins possessed the same genotype and showed discordant phenotypes. Twin A presented with ISRNS at the age of two and developed unilateral Wilms' tumor at the age of 3.49. Twin B presented with ISRNS at the age of 4.02 and did not present with any renal tumors at the last follow-up when she was 5.85.

The possible reason for our observations is that discordant phenotypes in our twins with identical *WT1* mutation R394W could be associated with the 'two-hit' mutational model of Wilms' tumorigenesis [6]. Although the onset age of Wilms' tumor in DDS patients with *WT1* mutation R394W was from 0.3 to 2.7 years [5, 7, 8], we will still continue a clinical follow-up and make a prompt report if Wilms' tumor will appear in Twin B.

Consistent in part with our study, monozygotic twins with the same *WT1* mutation presenting incomplete DDS and ISRNS were reported by Fencl et al. [4]; however, in that case, the *WT1* mutation was R366P and inherited from the twins' father. Also, four studies have previously noted monozygotic twins with identical *WT1* mutations presenting the same phenotypes [1, 3, 9, 10].

In conclusion, the female monozygotic twins showed discordant phenotypes, had an identical *de novo WT1* mutation R394W and presented incomplete DDS and ISRNS.

**Acknowledgements.** We thank Professor Jie Ding for her help with the grants. This project was supported by the Natural Science Foundation of Fujian Province of China (2006J0119).

**Conflict of interest statement.** None declared.

## References

1. Furtado L, Pysher T, Opitz J et al. Denys-Drash syndrome with neonatal renal failure in monozygotic twins due to C.1097G>A mutation in the *WT1* gene. *Fetal Pediatr Pathol* 2011; 30: 266–272
2. Benoit G, Machuca E, Antignac C. Hereditary nephrotic syndrome: a systematic approach for genetic testing and a review of associated podocyte gene mutations. *Pediatr Nephrol* 2010; 25: 1621–1632
3. Takata A, Kikuchi H, Fukuzawa R et al. Constitutional *WT1* mutations correlate with clinical features in children with progressive nephropathy. *J Med Genet* 2000; 37: 698–701
4. Fencl F, Malina M, Stará V et al. Discordant expression of a new *WT1* gene mutation in a family with monozygotic twins presenting with congenital nephrotic syndrome. *Eur J Pediatr* 2011; 171: 121–124
5. Chernin G, Vega-Warner V, Schoeb DS et al. Genotype/phenotype correlation in nephrotic syndrome caused by *WT1* mutations. *Clin J Am Soc Nephrol* 2010; 5: 1655–1662
6. Pelletier J, Bruening W, Kashtan CE et al. Germline mutations in the Wilms' tumor suppressor gene are associated with abnormal urogenital development in Denys-Drash syndrome. *Cell* 1991; 67: 437–447
7. Royer-Pokora B, Beier M, Henzler M et al. Twenty-four new cases of *WT1* germline mutations and review of the literature: genotype/phenotype correlations for Wilms tumor development. *Am J Med Genet A* 2004; 127A: 249–257
8. Little M, Wells C. A clinical overview of *WT1* gene mutations. *Hum Mutat* 1997; 9: 209–225
9. Motoyama O, Arai K, Kawamura T et al. Clinical course of congenital nephrotic syndrome and Denys-Drash syndrome in Japan. *Pediatr Int* 2005; 47: 607–611
10. Dharnidharka VR, Ruteshouser EC, Rosen S et al. Pulmonary dysplasia, Denys-Drash syndrome and Wilms tumor 1 gene mutation in twins. *Pediatr Nephrol* 2001; 16: 227–231

Received for publication: 28.11.11; Accepted in revised form: 22.2.12