

## Outcome after mitral valve repair for acute and healed infective endocarditis

Harm H.H. Feringa<sup>a</sup>, Jeroen J. Bax<sup>b,\*</sup>, Patrick Klein<sup>a</sup>, Robert J.M. Klautz<sup>a</sup>, Jerry Braun<sup>a</sup>, Ernst. E. van der Wall<sup>b</sup>, Don Poldermans<sup>c</sup>, Robert A.E. Dion<sup>a</sup>

<sup>a</sup> Department of Cardiothoracic Surgery, Leiden University Medical Center, Albinusdreef 2, 2333 ZA Leiden, The Netherlands

<sup>b</sup> Department of Cardiology, Leiden University Medical Center, Leiden, The Netherlands

<sup>c</sup> Department of Anesthesiology, Erasmus Medical Center, Rotterdam, The Netherlands

Received 3 October 2005; received in revised form 2 December 2005; accepted 6 December 2005; Available online 19 January 2006

### Abstract

**Objective:** To evaluate the long-term clinical and echocardiographic outcomes after mitral valve surgery for acute and healed infective endocarditis. **Methods:** Of 37 consecutive patients presenting with native mitral valve endocarditis, mitral valve repair (MVRep) was feasible in 34 (92%) patients. In 17 (50%) patients, surgery was indicated during antibiotic therapy (acute endocarditis), whereas 17 (50%) underwent surgery after antibiotic therapy was completed (healed endocarditis). Patients were evaluated for early and long-term clinical and echocardiographic outcome. **Results:** In-hospital death occurred in two (6%) patients and two (6%) died during follow-up, with a 2-year survival of 100% in healed endocarditis as compared to 76% ( $p = 0.03$ ) in patients undergoing surgery in acute endocarditis. No patient with acute endocarditis needed repeat mitral valve surgery. Three (9%) patients underwent re-operation because of early mitral regurgitation ( $n = 1$ ) or late recurrent endocarditis ( $n = 2$ ). The average grade of mitral regurgitation was  $3.8 \pm 0.4$  (all grades 3 to 4+) before surgery and  $0.6 \pm 0.8$  during follow-up ( $p < 0.001$ ). Significant reductions in left atrial (from  $52 \pm 8$  mm to  $46 \pm 8$  mm,  $p = 0.004$ ), left ventricular end-diastolic (from  $61 \pm 8$  mm to  $54 \pm 8$  mm,  $p = 0.001$ ), and end-systolic dimensions (from  $41 \pm 8$  mm to  $36 \pm 9$  mm,  $p = 0.02$ ) were observed during follow-up, compared to preoperative dimensions. Of note, significant reverse remodeling was only observed in patients undergoing surgery in healed endocarditis. **Conclusion:** MVRep for mitral valve endocarditis is feasible with good clinical results, maintained valve competency with significant reductions in left atrial and left ventricular dimensions after surgery.

© 2005 Elsevier B.V. All rights reserved.

**Keywords:** Mitral valve repair; Mitral valve replacement; Infective endocarditis; Mitral valve disease; Prognosis; Echocardiography

### 1. Introduction

Mitral valve repair (MVRep) in comparison to mitral valve replacement (MVR) offers well-accepted benefits in terms of low perioperative mortality, improved survival, low risk of anticoagulant-related complications, low risk of endocarditis, and preservation of left ventricular function [1–5]. In patients with infective endocarditis, destruction of the mitral valve is commonly noted and reconstruction of the mitral valve remains challenging. During the last years, few reports have published promising results of MVRep in infective endocarditis [6–16]. In addition, minimal information is available about the long-term clinical outcome and the long-term echocardiographic results after MVRep in infective endocarditis. In particular, it is unknown whether MVRep prevents left ventricular dilatation or even induces reverse

remodeling (i.e. improved left ventricular geometry) during long-term follow-up, which is associated with a favorable prognosis [17].

Another issue of uncertainty is the precise timing of surgery in patients with mitral valve endocarditis. Heart failure and progressive left-sided valvular dysfunction are the most common indications for surgical treatment in patients with infective endocarditis [18]. Early surgical intervention may be necessary to prevent further hemodynamic deterioration and valvular destruction by the infectious process. On the other hand, in the early stages of the disease, the patient's condition is frequently critical and operation in infected tissue is needed. However, preliminary studies have demonstrated good results in patients who were operated in the acute phase [6–14,19–21].

In the present manuscript, the feasibility and durability of MVRep in consecutive patients with infective endocarditis is reported and the process of LV dilatation or reverse remodeling is evaluated by serial echocardiographic studies up to 3 years after surgery. In addition, the results in patients

\* Corresponding author. Tel.: +31 71 526 2020; fax: +31 71 526 6809.  
E-mail address: J.J.Bax@lumc.nl (J.J. Bax).

undergoing surgery in the acute phase are compared with patients undergoing surgery for healed endocarditis.

## 2. Methods

### 2.1. Study population

Between January 2000 and March 2004, 37 consecutive patients underwent surgery for acute or healed native mitral valve endocarditis and 34 (92%) patients underwent mitral valve repair. The analyses were restricted to the 34 patients who underwent mitral valve repair for native valve endocarditis. The patient characteristics are summarized in Table 1. A potential cause of endocarditis could be identified in seven patients (21%): a dental procedure in four and an infective source in three. Pre-existing mitral valve regurgitation before the onset of mitral valve endocarditis was known in 11 patients (32%). The microorganism responsible for endocarditis was isolated in blood cultures in 32 patients (94%). Streptococci were the most frequent responsible organisms (56%), followed by staphylococci (32%). Gram-negative organisms were identified in 6% of the patients. The diagnosis of endocarditis was based on the Duke criteria and was confirmed at surgery by the evidence of valve damage typical of infective endocarditis [15]. Surgery was indicated in 17 patients during the 6-week course of antibiotic treatment (acute group) and in 17 patients after the 6-week course of antibiotic treatment (healed group). The mean time interval from the start of antibiotic treatment to surgery was  $19 \pm 12$  days in the acute group. In addition to mitral valve regurgitation grade  $\geq 3$ , surgery was indicated for one or more of the following reasons (Table 2):

- progressive congestive heart failure,
- uncontrolled sepsis,
- large or mobile vegetations,
- systemic embolic events.

### 2.2. Surgery

All operations were performed through a midline sternotomy on cardiopulmonary bypass with bicaval cannulation

and with intermittent antegrade warm blood cardioplegia. Mean duration of cardiopulmonary bypass was  $190 \pm 52$  min and mean aortic cross-clamp time was  $139 \pm 40$  min. The mitral valve was exposed through a transseptal approach. The major pathologies observed at the time of operation are listed in Table 2. During surgery, all macroscopically infected tissue were first resected. MVRep was performed according to Carpentier's techniques and principles [8,22]. The single or combined surgical procedures used to achieve a competent valve are shown in Table 2. Leaflet perforations caused by endocarditis or by resection of vegetations were closed by direct suture in nine patients. Autologous fresh pericardial patches were used in 12 patients to close larger perforations. In 23 patients, a part of the posterior mitral valve leaflet was resected and reconstructed with a sliding plasty and annulus plication. Commissural resection and reconstruction by sliding plasty, annulus plication, or stitching, was performed in 18 patients. Subvalvular repair techniques included chordal transfer (3 patients), neo-chordae anchoring (15 patients), and papillary muscle plication (1 patient). The use of a prosthetic ring was necessary in 28 patients, either because of annular dilatation or for reinforcement of annular remodeling after extensive mitral valve leaflet reconstruction. Associated procedures were aortic valve replacement (three patients), tricuspid valve annuloplasty (three patients), and coronary artery bypass grafting (two patients).

### 2.3. Echocardiography

A transthoracic echocardiography (TTE) was performed in all patients before surgery (median of 2 days, interquartile range 1–8 days). For TTE, patients were imaged in the left lateral decubitus position using a commercially available system (Vingmed Vivid Seven, General Electric – Vingmed, Milwaukee, WI, USA). Images were obtained using a 3.5 MHz transducer at a depth of 16 cm in the parasternal and apical views (standard long-axis, 2-chamber and 4-chamber images). The left atrial diameter and left ventricular dimensions (end-systolic and end-diastolic diameter) were determined from parasternal M-mode acquisitions. The severity of mitral regurgitation was graded semi-quantitatively from color-flow Doppler in the conventional parasternal long-axis and apical 4-chamber images. Mitral

Table 1  
Baseline characteristics of the 34 patients with acute and healed endocarditis

	Acute endocarditis (n = 17)	Healed endocarditis (n = 17)
Age (years)	$53 \pm 16$	$54 \pm 16$
Gender (male)	15 (88%)	12 (71%)
Hypertension	4 (24%)	3 (18%)
Diabetes mellitus	0 (0%)	2 (12%)
Renal insufficiency	1 (6%)	1 (6%)
Chronic obstructive pulmonary disease	1 (6%)	2 (12%)
Previous myocardial infarction	2 (12%)	1 (6%)
Previous cardiac surgery	2 (12%)	1 (6%)
Peripheral arterial disease	0 (0%)	1 (6%)
Previous stroke	1 (6%)	0 (0%)
Intra-venous drug abuse	0 (0%)	0 (0%)
Previous infective endocarditis	0 (0%)	0 (0%)
Congestive heart failure	9 (53%)	3 (18%)
NYHA class	$2.5 \pm 1.1$	$1.8 \pm 0.9$
Logistic Euro-score (median and interquartile range)	$6.0 (4.4–13.2)$	$2.7 (1.5–5.0)$

Table 2  
Surgical data including preoperative time-intervals, indications for surgery and perioperative findings

	Acute endocarditis (n = 17)	Healed endocarditis (n = 17)
Time interval of symptom onset–operation	32 ± 27 days	>6 weeks
Time interval of diagnosis–operation	19 ± 13 days	>6 weeks
Time interval of start antibiotics–operation	19 ± 12 days	>6 weeks
Indication for surgery		
Progressive congestive heart failure	9 (53%)	3 (18%)
Uncontrolled sepsis	8 (47%)	0 (0%)
Large or mobile vegetations	2 (12%)	0 (0%)
Systemic embolic events	5 (29%)	0 (0%)
Mitral regurgitation grade ≥ 3	17 (100%)	17 (100%)
Perioperative findings		
Vegetations	13 (76%)	7 (41%)
Abscess	4 (24%)	1 (6%)
Chordal rupture	3 (18%)	7 (41%)
Commissural perforations	2 (12%)	5 (29%)
Noncommissural perforations	3 (18%)	9 (53%)
Commissural valve prolaps	4 (24%)	5 (29%)
Noncommissural valve prolaps	6 (35%)	14 (82%)
Surgical repair procedures		
Primary closure for perforations	2 (12%)	7 (41%)
Patch closure for perforations	5 (29%)	7 (41%)
Leaflet resection and sliding plasty	12 (71%)	11 (65%)
Commissural reconstruction	8 (47%)	10 (59%)
Transposition of chordae	2 (12%)	1 (6%)
Neo-chordae	5 (29%)	10 (59%)
Papillary muscle plication	1 (6%)	0 (0%)
Prosthetic ring	15 (88%)	13 (76%)
Concomitant aortic valve replacement	3 (18%)	0 (0%)
Concomitant tricuspid valve repair	1 (6%)	2 (12%)
Concomitant coronary artery bypass grafting	0 (0%)	2 (12%)

regurgitation was characterized as: mild = 1+ (jet area/left atrial area < 10%), moderate = 2+ (jet area/left atrial area 10–20%), moderately severe = 3+ (jet area/left atrial area 20–45%), and severe = 4+ (jet area/left atrial area > 45%) [23].

Immediately before surgery, a transesophageal echocardiogram (TEE) was performed to confirm the mechanism of mitral valve regurgitation. Immediately after surgery, TEE was performed to assess residual mitral valve regurgitation, the length of leaflet coaptation, and the transmitral diastolic gradient. ATTE was repeated before discharge (median of 7 days, interquartile range 4–10 days) and during follow-up (median of 1.8 years, interquartile range 0.7–2.8 years) to assess left atrial and ventricular dimensions, the presence of residual mitral valve regurgitation and the transmitral diastolic gradient. Two experienced cardiologists blinded to the clinical data analyzed all echocardiographic data.

#### 2.4. Postoperative outcome and follow-up

Postoperative events, including overall mortality, cardiac mortality, nonfatal myocardial infarction, relapse endocarditis, sepsis, repeat mitral valve surgery for mitral valve regurgitation or relapse endocarditis, cerebrovascular events, and renal dysfunction were recorded during hospital stay (early events) and during follow-up (late events). Renal dysfunction was defined when the serum creatinine level was ≥2.0 mg/dL (177 μmol/L) or when dialysis was required. During follow-up, the patient's status was determined at the outpatient clinic, by contacting the patient's general

practitioner or by telephone interviews. The patient's functional status was assessed according to the NYHA classification for symptoms of heart failure. Follow-up was complete in 31 patients (91%). Median follow-up time was 2.0 years (interquartile range 1.0–3.7 years).

#### 2.5. Statistical analysis

Continuous data were expressed as mean (±SD) or median (±interquartile range) and compared using the Student's *t*-test or Mann–Whitney *U*-test when appropriate. Categorical data are presented as percent frequencies and differences between proportions were compared using the Fisher's exact test. Survival over time was analyzed using Kaplan–Meier methods and differences between survival curves in different subgroups of patients were tested with the log-rank  $\chi^2$  statistic. For all tests, a *p*-value <0.05 (two-sided) was considered significant. All analyses were performed using SPSS-11.0 statistical software (SPSS Inc., Chicago, IL, USA).

### 3. Results

#### 3.1. Feasibility of MVRep

A total of 37 patients presented with native mitral valve endocarditis. Among them, three patients (two with acute endocarditis and one with healed endocarditis) underwent prosthetic MVR because of extensive destruction of the mitral valve apparatus. Thus, MVRep was feasible in 17 of 19

Table 3  
Clinical outcome after mitral valve repair

	Repair (n = 34)
<b>Early events</b>	
All-cause mortality	2 (6%)
Cardiac mortality	1 (3%)
Mitral valve surgery	1 (3%)
Myocardial infarction	1 (3%)
Sepsis	4 (12%)
Renal dysfunction	3 (9%)
Stroke or transient ischemic attack	1 (3%)
Relapse endocarditis	0 (0%)
<b>Late events</b>	
All-cause mortality	2 (6%)
Cardiac mortality	0 (0%)
Mitral valve surgery	2 (6%)
Myocardial infarction	0 (0%)
Relapse endocarditis	2 (6%)
Stroke or transient ischemic attack	0 (0%)

Early events include events during postoperative hospital stay. Late events are events after discharge and during follow-up. Mitral valve surgery denotes redo-surgery because of mitral regurgitation or relapse endocarditis.

patients (89%) with acute endocarditis and in 17 of 18 patients (94%) with healed endocarditis.

### 3.2. Clinical results after MVRep

Early mortality after MVRep for infective endocarditis occurred in two patients (6%) (Table 3). One patient had concomitant aortic valve replacement and tricuspid valve repair for acute triple valve endocarditis and died on the first postoperative day because of heart failure. The other patient died 26 days after acute MVRep because of persisting sepsis and multi-organ failure. In this patient, postoperative echocardiography revealed a competent valve, intact left ventricular function without signs of persistent endocarditis. One patient was re-operated during hospital stay, because of severe mitral valve regurgitation after MVRep for healed endocarditis. Papillary muscle plication sutures were ruptured and this patient received a prosthetic mitral valve on day 6 after surgery. Other early nonfatal events, including myocardial infarction, sepsis, renal dysfunction, cerebrovascular events, and relapse endocarditis are summarized in Table 3. Late mortality after MVRep for infective endocarditis occurred in two patients (one patient died of osteomyelitis with sepsis and one died of gastro-intestinal bleeding). During follow-up, two patients required a re-operation because of recurrent mitral valve endocarditis, 2 and 3

months after MVRep for healed endocarditis. At 2-year follow-up, 30 patients (88%) with MVRep were alive and all were in NYHA class I or II, including the patients who underwent re-operation for mitral repair failure or endocarditis in the early or late postoperative period. Follow-up results are summarized in Table 3. Of note, no significant differences in mortality/morbidity were observed between patients with and without mitral annuloplasty ring.

### 3.3. Echocardiographic results after MVRep

Table 4 summarizes the echocardiographic results. During follow-up, a TTE was performed in 29 patients with MVRep. All patients presented preoperatively with grades 3 to 4+ mitral regurgitation, which was reduced to  $0.6 \pm 0.8$  during follow-up ( $p < 0.001$ ). Mitral valve stenosis did not occur after surgery (mean transmitral gradient  $2.4 \pm 0.9$  mmHg at long-term follow-up). Left atrial, left ventricular end-diastolic and end-systolic dimensions decreased significantly after surgery, indicating reverse remodeling. Of note, 62% of the patients showed a  $>10\%$  reduction in left ventricular end-systolic and/or diastolic dimension during follow-up. Patients without this reverse remodeling had a significantly larger left ventricular end-systolic dimension ( $40 \pm 11$  mm vs  $31 \pm 5$  mm,  $p = 0.006$ ) and end-diastolic dimension ( $56 \pm 10$  mm vs  $50 \pm 4$  mm,  $p = 0.03$ ).

### 3.4. Acute versus healed endocarditis

None of the 17 patients who underwent surgery after healed endocarditis died; in contrast, 4 (24%) of 17 patients undergoing MVRep in the acute phase of endocarditis died ( $p = 0.03$ , Fig. 1). Of note however, no repeat mitral valve surgery was needed in patients who underwent MVRep for acute endocarditis. The details on mortality and morbidity in patients with healed versus acute endocarditis are summarized in Table 5.

A total of 17 patients with acute endocarditis had a follow-up TTE. The average grade of mitral valve regurgitation was  $3.4 \pm 0.5$  before surgery and  $0.3 \pm 0.7$  at follow-up ( $p < 0.001$ ). Nonsignificant reductions in left atrial dimension (from  $51 \pm 8$  mm to  $47 \pm 7$  mm,  $p = 0.2$ ), left ventricular end-diastolic dimension (from  $57 \pm 7$  mm to  $53 \pm 5$  mm,  $p = 0.06$ ), and left ventricular end-systolic dimension (from  $38 \pm 8$  mm to  $34 \pm 7$  mm,  $p = 0.2$ ) were observed during follow-up.

A follow-up TTE was performed in 12 patients with healed endocarditis. The average grade of mitral valve regurgitation

Table 4  
Echocardiographic results after mitral valve repair

Mitral valve repair	Baseline TTE (n = 34)	Intra-operative TEE (n = 34)	Follow-up TTE (n = 29)	p-value
MR (grade)	$3.8 \pm 0.4$	$0.3 \pm 0.6$	$0.6 \pm 0.8$	$<0.001$
LA (mm)	$52 \pm 8$	–	$46 \pm 8$	0.004
LVEDD (mm)	$61 \pm 8$	–	$54 \pm 8$	0.001
LVESD (mm)	$41 \pm 8$	–	$36 \pm 9$	0.02
LV FS (%)	$34 \pm 8$	–	$35 \pm 8$	0.5
Coaptation (mm)	–	$7.4 \pm 1.1$	–	–
Transmitral gradient (mmHg)	–	$3.1 \pm 0.9$	$2.4 \pm 0.9$	0.002

MR, mitral regurgitation; LA, left atrium; LVEDD, left ventricular end-diastolic dimension; LVESD, left ventricular end-systolic dimension; LV FS, left ventricular fractional shortening; TTE, transthoracic echocardiography; TEE, transesophageal echocardiography; transmitral gradient, mean transmitral diastolic gradient. Intra-operative TEE was performed during surgery immediately after the surgical mitral valve procedure.

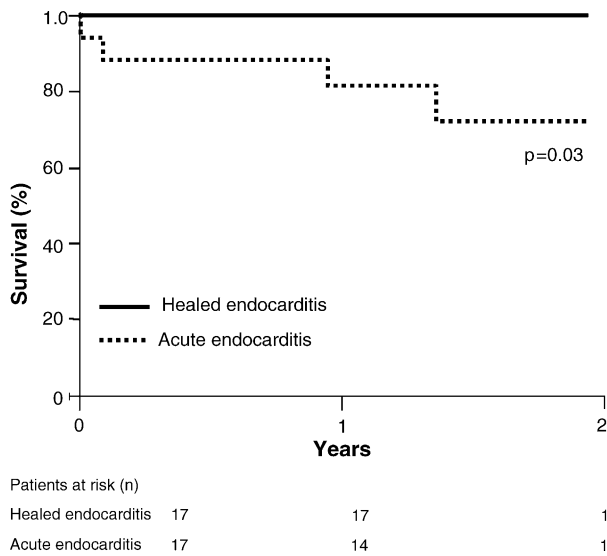


Fig. 1. Survival curves of patients undergoing mitral valve repair in the acute phase of endocarditis as compared to healed endocarditis.

was  $3.8 \pm 0.2$  before surgery and  $0.2 \pm 0.6$  at follow-up ( $p < 0.001$ ). Significant reductions in left atrial dimension (from  $52 \pm 7$  mm to  $45 \pm 10$  mm,  $p = 0.03$ ), left ventricular end-diastolic dimension (from  $63 \pm 8$  mm to  $53 \pm 10$  mm,  $p = 0.005$ ), and left ventricular end-systolic dimension (from  $43 \pm 7$  mm to  $36 \pm 10$  mm,  $p = 0.05$ ) were observed after surgery.

#### 4. Discussion

The findings in the present study demonstrate that MVRep is feasible in endocarditis with good clinical and echocardiographic results and significant reductions in left atrial and left ventricular dimensions. Two-year survival was excellent (100%) in patients undergoing surgery in healed endocarditis as compared to 76% ( $p = 0.03$ ) in patients undergoing surgery in acute endocarditis. Of note though, no repeat mitral valve

surgery was needed in patients who underwent MVRep for acute endocarditis.

#### 4.1. MVRep in infective endocarditis

In degenerative mitral valve disease, MVRep is preferred over MVR [1–5]. However, in the setting of infective endocarditis, MVRep may not be feasible because of the extent of destruction of the mitral valve apparatus. In addition, concerns have been raised about the durability of complex MVRep in inflammatory tissue during acute endocarditis. Limited studies have been published on the feasibility of MVRep in endocarditis. In 1990, Dreyfus et al. [8] published the first detailed report of valve repair in 40 patients with acute infective endocarditis (operated within 6 weeks after the beginning of antibiotic therapy) in which MVRep was performed in 34 patients. Of these patients, one died during hospital stay, one needed an early re-operation, and one died 2.5 years after repair. In a more recent report, lung et al. [6] evaluated the feasibility and immediate and late results of MVRep for acute (during course of antibiotic treatment) (25 patients) and healed endocarditis (38 patients). MVRep was feasible in 78% of patients with acute and in 83% of patients with healed endocarditis. An excellent survival was observed in patients operated for acute endocarditis. A total of six re-operations were performed of which five were needed after MVRep for acute endocarditis. Moreover, Zegdi et al. [10] evaluated 37 consecutive patients in whom MVRep for acute (during the first 6 weeks of antibiotic treatment) endocarditis was feasible (75%), and reported 89% survival at 5-year follow-up and 80% at 10-year follow-up.

In the present study, MVRep was feasible in 89% and 94% of patients with acute and healed endocarditis, respectively, which was higher than in previous studies (however, surgery was conducted before January 2000 in all of the previous reports) [6,8,10]. This observation may reflect the developing experience with MVRep and refinements in the technique. The extent of mitral valve tissue destruction was the only reason to decide for MVR over MVRep. All patients had combined repair procedures involving two or more repair

Table 5  
Clinical outcome after acute and healed endocarditis

	Acute endocarditis (n = 17)	Healed endocarditis (n = 17)	p-value
<b>Early events</b>			
All-cause mortality	2 (12%)	0 (0%)	0.5
Cardiac mortality	1 (6%)	0 (0%)	1.0
Myocardial infarction	0 (0%)	1 (6%)	1.0
Sepsis	4 (24%)	0 (0%)	0.1
Renal dysfunction	2 (12%)	1 (6%)	1.0
Stroke or transient ischemic attack	0 (0%)	1 (6%)	1.0
Relapse endocarditis	0 (0%)	0 (0%)	–
Mitral valve surgery	0 (0%)	1 (6%)	1.0
<b>Late events</b>			
All-cause mortality	2 (12%)	0 (0%)	0.5
Cardiac mortality	0 (0%)	0 (0%)	–
Myocardial infarction	0 (0%)	0 (0%)	–
Relapse endocarditis	0 (0%)	2 (12%)	0.5
Mitral valve surgery	0 (0%)	2 (12%)	0.5
Stroke or transient ischemic attack	0 (0%)	0 (0%)	–

Early events include events during postoperative hospital stay. Late events are events after discharge and during follow-up. Mitral valve surgery denotes surgery for mitral regurgitation or relapse endocarditis.

techniques. The results were monitored by intra-operative TEE to exclude residual mitral regurgitation or stenosis, and ensure adequate leaflet coaptation. In our study, an excellent long-term durability of MVRep was observed; in only 1 of 34 MVRep procedures, re-operation was required because of postoperative MVRep failure for healed endocarditis (in two other patients with healed endocarditis, re-operation was required because of late recurrent endocarditis). In addition, follow-up TTE demonstrated minimal residual mitral valve regurgitation after MVRep.

Sequential TTE demonstrated not only sustained valvular competency and absence of stenosis but also reverse left ventricular remodeling after MVRep in endocarditis. Patients with infective endocarditis often present with congestive heart failure and progressive left ventricular dilation is associated with poor long-term prognosis. In contrast, reverse remodeling is associated with a favorable outcome [17]. Stabilization of the mitral annulus and unloading of the left ventricle may have been underlying responsible mechanisms. To the best of our knowledge, no studies so far have evaluated reverse left ventricular remodeling in patients undergoing MVRep for infective endocarditis.

The early mortality (6%) and long-term survival (88% at 2-year follow-up) in patients with MVRep for infective endocarditis in the present study are in accordance with other studies. In particular, previous reports revealed that operative mortality after MVRep for infective endocarditis ranged from 0% to 9% [6–16], whereas survival ranged from 85% to 93% at 5-year follow-up [10,15,16].

#### 4.2. Acute versus healed endocarditis

Infective endocarditis can be classified into acute or healed based on the severity of the clinical presentation and the progression of the disease [24]. Acute endocarditis has generally been defined as endocarditis during the 6-week antibiotic treatment. Although early surgery may be associated with a higher risk than delayed surgery, early operation may be preferred to avoid severe hemodynamic instability or involvement of perivalvular tissue. Survival rates of 96% for acute endocarditis and 91% for healed endocarditis after MVRep have been reported [7]. In the present study, mortality was higher in patients undergoing surgery in the acute phase as compared to patients undergoing surgery in healed endocarditis (Fig. 1). Since progressive heart failure and uncontrolled sepsis are major indications to decide for acute surgical intervention, this higher mortality rate in patients with acute endocarditis is not unexpected. In addition, the reduction in left atrial and left ventricular dimensions was significant in patients undergoing MVRep in healed endocarditis, whereas a nonsignificant trend toward reverse remodeling was observed in patients with acute endocarditis.

#### 5. Limitations

The main limitation is the small number of patients. However, this was a prospective, observational study, merely to evaluate the feasibility of MVRep in patients with endocarditis. Various issues need further study, including

the relative merits of MVRep and MVR, and also the benefit of MVRep in acute versus healed endocarditis in terms of long-term clinical outcome and echocardiographic evidence of left atrial and ventricular reverse remodeling.

#### 6. Conclusion

The results of the present study demonstrate the feasibility of MVRep in patients with acute and healed endocarditis with low mortality and morbidity, although mortality was higher in patients undergoing surgery in acute endocarditis. However, there was no early and late repeat mitral valve surgery in patients who underwent MVRep for acute endocarditis, supporting early surgery in acute endocarditis. Sequential TTE demonstrated sustained valve competency, absence of stenosis and reverse left atrial and left ventricular remodeling in patients undergoing surgery for healed endocarditis; a trend toward reverse remodeling was also observed after surgery in acute endocarditis, but larger studies are needed to confirm this observation. Although larger studies are needed, the present findings suggest that MVRep should be attempted in patients presenting with acute and healed mitral valve endocarditis.

#### References

- [1] Galloway AC, Colvin SB, Baumann FG, Esposito R, Vohra R, Harty S, Freeberg R, Kronzon I, Spencer FC. Long-term results of mitral valve reconstruction with Carpentier techniques in 148 patients with mitral insufficiency. *Circulation* 1988;78:197–105.
- [2] Cosgrove DM, Chavez AM, Lytle BW, Gill CC, Stewart RW, Taylor PC, Goormastic M, Borsh JA, Loop FD. Results of mitral valve reconstruction. *Circulation* 1986;74:182–187.
- [3] Loop FD. Long-term results of mitral valve repair. *Semin Thorac Cardiovasc Surg* 1989;1:203–10.
- [4] Deloche A, Jebara VA, Relland JY. Valve repair with Carpentier techniques. The second decade. *J Thorac Cardiovasc Surg* 1990;99:990–1001.
- [5] Yun KL, Miller DC. Mitral valve repair versus replacement. *Cardiol Clin* 1991;9:315–27.
- [6] Iung B, Rousseau-Paziaud J, Cormier B, Garbarz E, Fondard O, Brochet E, Acar C, Couetil JP, Hvas U, Vahanian A. Contemporary results of mitral valve repair for infective endocarditis. *J Am Coll Cardiol* 2004;43:386–92.
- [7] Lee EM, Shapiro LM, Wells FC. Conservative operation for infective endocarditis of the mitral valve. *Ann Thorac Surg* 1998;65:1087–92.
- [8] Dreyfus G, Serraf A, Jebara VA, Deloche A, Chauvaud S, Couetil JP, Carpentier A. Valve repair in acute endocarditis. *Ann Thorac Surg* 1990;49:706–11.
- [9] Muehrcke DD, Cosgrove III DM, Lytle BW, Taylor PC, Bugar AM, Durnwald CP, Loop FD. Is there an advantage to repairing infected mitral valves? *Ann Thorac Surg* 1997;63:1718–24.
- [10] Zegdi R, Debieche M, Latremouille C, Lebiéd D, Chardigny C, Grinda JM, Chauvaud S, Deloche A, Carpentier A, Fabiani JN. Long-term results of mitral valve repair in active endocarditis. *Circulation* 2005;111:2532–6.
- [11] Podesser BK, Rodler S, Hahn R, Eigenbauer E, Vodrazka M, Moritz A, Laufer G, Simon P, Wolner E. Mid-term follow up of mitral valve reconstruction due to active infective endocarditis. *J Heart Valve Dis* 2000;9:335–40.
- [12] Pagani FD, Monaghan HL, Deeb GM, Bolling SF. Mitral valve reconstruction for active and healed endocarditis. *Circulation* 1996;94(9 Suppl.):II133–8.
- [13] Senni M, Merlo M, Sangiorgi G, Gamba A, Procopio A, Glauber M, Ferrazzi P. Mitral valve repair and transesophageal echocardiographic findings in a high risk subgroup of patients with active, acute infective endocarditis. *J Heart Valve Dis* 2001;10:72–7.
- [14] Sternik L, Zehr KJ, Orszulak TA, Mullany CJ, Daly RC, Schaff HV. The advantage of repair of mitral valve in acute endocarditis. *J Heart Valve Dis* 2002;11:91–7.

- [15] Mihaljevic T, Paul S, Leacche M, Rawl JD, Aranki S, O’Gara PT, Cohn LH, Byrne JG. Tailored surgical therapy for acute native mitral valve endocarditis. *J Heart Valve Dis* 2004;13(2):210–6.
- [16] Doukas G, Oc M, Alexiou C, Sosnowski AW, Samani NJ, Spyt TJ. Mitral valve repair for active culture-positive infective endocarditis. *Heart* 2005 [Epub ahead of print].
- [17] Udelson JE, Konstam MA. Relation between left ventricular remodeling and clinical outcomes in heart failure patients with left ventricular systolic dysfunction. *J Card Fail* 2002;8:5465–71.
- [18] Durack DT, Lukes AS, Bright DK. New criteria for diagnosis of infective endocarditis: utilization of specific echocardiographic findings. Duke Endocarditis Service. *Am J Med* 1994;96:200–9.
- [19] Olaison L, Pettersson G. Current best practices and guidelines. Indications for surgical intervention in infective endocarditis. *Cardiol Clin* 2003;21:235–51.
- [20] Nihoyannopoulos P, Oakley CM, Exadactylos N, Ribeiro P, Westaby S, Foale RA. Duration of symptoms and the effects of a more aggressive surgical policy: two factors affecting prognosis of infective endocarditis. *Eur Heart J* 1985;6:380–90.
- [21] Bogers AJ, van Vreeswijk H, Verbaan CJ, Kappetein AP, van Herwerden LA, Mochtar B, Bos E. Early surgery for active infective endocarditis improves early and late results. *Thorac Cardiovasc Surg* 1991;39:284–8.
- [22] Carpentier A, Chauvaud S, Fabiani JN, Deloche A, Relland J, Lessana A, D’Allaines C, Blondeau P, Piwnica A, Dubost C. Reconstructive surgery of mitral valve incompetence: ten-year appraisal. *J Thorac Cardiovasc Surg* 1980;79:338–48.
- [23] Thomas JD. How leaky is that mitral valve? Simplified Doppler methods to measure regurgitant orifice area. *Circulation* 1997;95:548–55.
- [24] Mylonakis E, Calderwood SB. Infective endocarditis in adults. *N Engl J Med* 2001;345:1318–30.