

# Soft tissue profile changes after rapid maxillary expansion with a bonded expander

Bianca Mota dos Santos\*, Andréa Sasso Stuani\*\*, Adriana Sasso Stuani\*, Gisele Faria\*\*\*, Catia Cardoso Quintão\*\* and Maria Bernadete Sasso Stuani\*

Departments of Orthodontics and Pediatric Dentistry, \*School of Dentistry of Ribeirão Preto, University of São Paulo, \*\*School of Dentistry, State University of Rio de Janeiro and \*\*\*Department of Restorative Dentistry, School of Dentistry, São Paulo State University, Araraquara, Brazil

*Correspondence to:* Prof. Maria Bernadete Sasso Stuani, Departments of Orthodontics and Pediatric Dentistry, School of Dentistry of Ribeirão Preto, University of São Paulo, Avenida do Café, s/n°, Bairro, Monte Alegre, CEP 14040-904, Ribeirão Preto, SP, Brazil. E-mail: bernadete@forp.usp.br

**SUMMARY** The aim of this study was to evaluate the short- and long-term treatment effects of rapid maxillary expansion (RME) on the soft tissue facial profile of subjects treated with a modified acrylic-hyrax device. The sample comprised 10 males and 10 females in the mixed dentition. Their average age was 9.3 years  $\pm$  10 months pre-treatment (T1), with a narrow maxilla and posterior crossbite, treated with a modified fixed maxillary expander with an occlusal splint. Lateral cephalometric radiographs obtained at T1, immediately post-expansion (T2), and after retention (T3) were used to determine possible changes in the soft tissue facial profile. The means and standard deviations for linear and angular cephalometric measurements were analysed statistically using analysis of variance and Tukey's test ( $\alpha = 0.05$ ).

The measurements at T2 differed significantly from those at T1 and T3. However, RME did not produce any statistically significant alteration ( $P > 0.05$ ) in the soft tissue profile for any of the cephalometric landmarks evaluated when compared at T1 and T3. The use of a fixed expander associated with an occlusal splint did not cause significant alterations in the soft tissue facial profile at T3. This modified device is effective for preventing the adverse vertical effects of RME such as an increase anterior face height in patients with a crossbite.

## Introduction

For decades, the standard of beauty has been determined by the media and this has influenced the concepts of facial harmony and beauty. For these reasons, the importance of harmonious facial aesthetics to satisfactory and functional occlusion during orthodontic treatment has been acknowledged. With the advent of cephalometrics, several measurements have been proposed to evaluate harmony among dentoskeletal structures and soft tissues and the changes that occur during growth and after orthodontic treatment (Holdaway, 1956; Steiner, 1962; Burstone, 1967; Ricketts, 1968; Erbay and Caniklioglu, 2002; Erbay *et al.*, 2002).

Rapid maxillary expansion (RME) has been widely used to increase the maxillary transverse dimension in young patients because the orthopaedic force exerted by the expander can open the midpalatal suture, which is usually patent in children (Haas, 1965, 1970, 1973; Zimring and Isaacson, 1965; Davis and Kronman, 1969; Wertz, 1970; Melsen, 1972; Wertz and Dreskin, 1977). However, for a skeletally more mature adolescent or adult, the suture is often fused, and RME tends to be less effective (Zimring and Isaacson, 1965; Melsen, 1972). Although research has been undertaken on the maxillary and mandibular responses after RME on the sagittal and vertical dimensions (as assessed on lateral cephalograms), the

results are still inconclusive. For example, while Haas (1965) and Davis and Kronman (1969) found that the maxilla moved downward and forward after RME with a fixed expander (Haas type), da Silva Filho *et al.* (1991) observed that the maxilla did not change sagittally, but moved downward, displaying a downward and backward rotation of the palatal plane. Wertz (1970) and Wertz and Dreskin (1977) reported that the maxilla moved downward and backward in some patients and downward and forward in others after RME. Wertz (1970) also reported that the maxillary incisors retroclined after RME, whereas Sandikçioğlu and Hazar (1997) found that the maxillary incisors became more proclined. In terms of mandibular response, some investigators have found that the mandible rotated backward, resulting in a higher mandibular plane angle and an increased lower face height when fixed RME was used (Davis and Kronman, 1969; Wertz, 1970; da Silva Filho *et al.*, 1991; Sandikçioğlu and Hazar, 1997). There is a consensus in the literature that face height is an important factor in facial balance and that lower anterior face height (LAFH) is the main contributor to total face height (Bacon *et al.*, 1983; Flynn *et al.*, 1989; Janson *et al.*, 1994; Barter *et al.*, 1995; Linder-Aronson and Woodside, 2000; Beane *et al.*, 2003). This increased LAFH has been described as a compensatory mechanism to minimize the risk

of a Class III malocclusion because of the enlarged mandibular body (Barter *et al.*, 1995). Using a fixed RME appliance (with occlusal coverage), Akkaya *et al.* (1999) reported that the maxilla moved forward and the mandible moved backward. Therefore, ANB angle and mandibular plane angle increased significantly after expansion. Similar results were reported by Basciftci and Karaman (2002). Nonetheless, Sarver and Johnston (1989) observed that the maxilla moved forward less with a fixed RME with occlusal splint than with a fixed RME (Haas type) and that in some fixed RME patients, the maxilla even moved backward.

The maxillary and mandibular responses after RME on the sagittal and vertical dimensions have been extensively reported and discussed in the literature because interarch discrepancies developed after treatment can potentially cause temporary or permanent changes in the patient's facial profile (Haas, 1965; Davis and Kronman, 1969; Wertz, 1970; Wertz and Dreskin, 1977; Timms, 1980; da Silva Filho *et al.*, 1995; Sandikçioğlu and Hazar, 1997; Memikoglu and Iseri, 1999; Bishara, 2000; Cross and McDonald, 2000; Baccetti *et al.*,

2001; Basciftci and Karaman, 2002). Orthodontists frequently use these changes to improve the facial profile of Class III patients, while others try to avoid these post-RME effects, such as in dolicofacial patients. In addition to be effective and stable and to compensate for unharmonious facial patterns, orthodontic treatment must be in equilibrium with the normal growth process. However, very limited information is available in the literature regarding soft tissues changes after RME and whether they remain stable after retention.

The aim of this study was to investigate the changes that occur in the soft tissue profile of young children with a narrow maxilla and a posterior crossbite, treated with RME.

### Subjects and methods

The research protocol was approved by the Research Ethics Committee of the School of Dentistry of Riberão Preto, and written informed consent was obtained from the parents of the children. It was a prospective study, with no untreated controls, using 60 lateral cephalometric radiographs obtained from 20 healthy Caucasian children (10 males and 10 females) with a mean skeletal age of 9.3 years (range 9.1–10.8 years), who required RME; the mean observation period was 7 months. The skeletal age of each patient was determined on a hand–wrist radiograph, according to the standards set by Greulich and Pyle (1959). The inclusion criteria were a mixed dentition phase; presence of a narrow maxilla and skeletal posterior crossbite, with indications for RME; no previous orthodontics; Class I skeletal pattern (0 degrees less than or equal to ANB less than or equal to 4 degrees) patients without a high mandibular plane angle.

A fixed rapid maxillary expander with an occlusal splint was used for correction of the skeletal crossbite. For fabrication of each appliance, a 0.8 mm stainless steel orthodontic wire framework (Dentaurum, Pforzheim, German) was fabricated that included the buccal and palatal surfaces of the posterior teeth, contouring the distal face of the permanent first molars, and crossing the occlusal surface between the canines and lateral incisors. A hyrax expansion screw (Dental Morelli, São Paulo, Brazil) was then soldered to the framework between the primary molars approximately 2 mm from the palatal surface along the midpalatal suture. An acrylic occlusal splint was then constructed (Figure 1) and bonded to the upper posterior teeth with dual-cure resin cement (Rely X; 3M, St Paul, Minnesota, USA). The acrylic part of the appliance extended over the occlusal and middle third of the vestibular surfaces of all teeth. The thickness of the occlusal acrylic surface was limited to the freeway space and was in contact with all lower teeth. All expanders were made in-house at the orthodontic laboratory of the Ribeirão Preto Dental School, University of São Paulo. One week after insertion, the expander was activated every 12 hours, corresponding to 0.50 mm/day (two turns/day; 0.25 mm per turn) for 3–4 weeks. The desired expansion was achieved when the posterior crossbite was slightly overcorrected with reference to the posterior transverse interarch relationship.

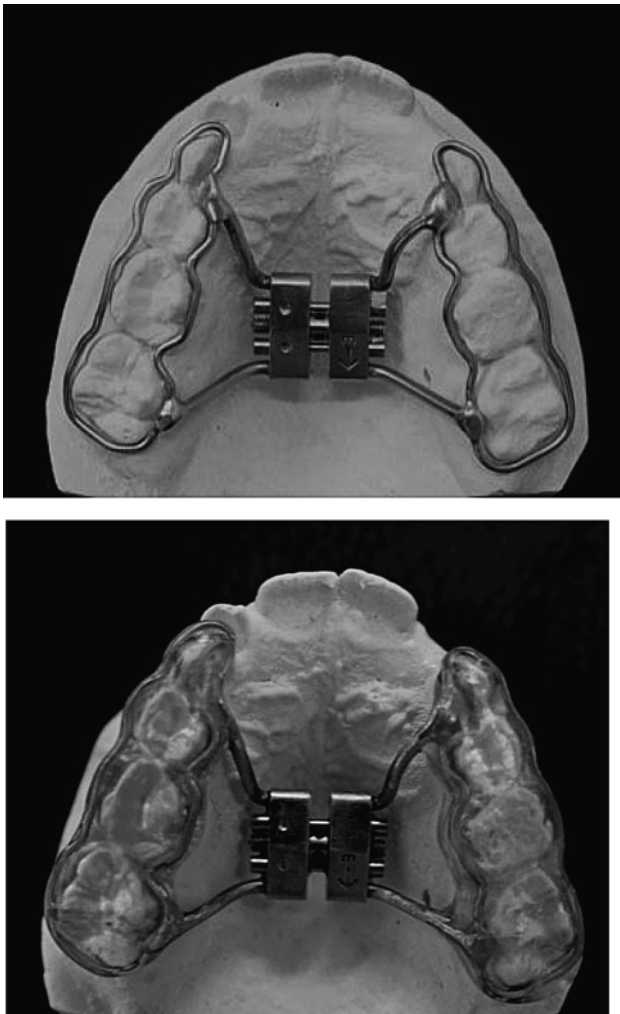


Figure 1 The bonded rapid palatal expander used in the study.

The expansion was considered adequate when the occlusal aspect of the maxillary lingual cusp of the upper first molars contacted the occlusal aspect of the facial cusp of the mandibular lower first molars. The 2–3 mm overexpansion was designed to compensate for relapse after expansion. The screw was then stabilized with acrylic resin and the same appliance was maintained *in situ* as a passive retainer, during a retention period of 6 months.

Pre-treatment (T1), post-expansion (T2), and post-retention (T3) orthodontic records, including study casts and lateral cephalograms, were obtained for all patients. T2 records were taken on the day the expander was stabilized and T3 records 6 months after T2. The mean interval between T1 and T2 was 21 days and between T2 and T3 6 months. No brackets or wires were inserted until the T3 records were taken.

Cephalometric tracings and measurements of the soft tissue facial were made at T1, T2, and T3. Serial lateral cephalograms were hand traced using a 0.5 mm lead pencil on 0.003 mm matte acetate tracing paper. The cephalometric landmarks were located according to established definitions (Holdaway, 1956; Steiner 1962; Ricketts, 1968; Legan and Burstone, 1980; McNamara, 1984) (Figure 2). These were used to determine possible changes in the soft tissue facial profile (Figure 2). Each cephalogram was traced by one author (BMdS) and verified by another investigator (MBSS).

*Error of the method*

Twenty lateral films were randomly chosen to calculate the error of the method. Measurements were repeated after a 1 month interval, without knowledge of the first measurements and the method error was calculated using the formula of Dahlberg (Houston, 1983).

*Statistical analysis*

GraphPad Prism, version 5 (GraphPad Software Inc., San Diego, California, USA) was used for evaluation of the measurements. The mean differences between T1 and T2, T1 and T3, and T2 and T3 measurements were evaluated by analysis of variance and Tukey’s test. Significance was assumed at  $P < 0.05$ .

**Results**

The differences between the original and retraced measurements was less than 0.5 degrees and 0.25 mm, indicating no statistically significant differences in inter- and intra-agreement examiner in cephalometric measurements.

Upper lip measurements (S–Ls, E Line–Ls; SnPg’–Ls) showed protrusion from T1 to T2 and retrusion from T2 to T3, significant from T1 to T2 and T2 to T3 ( $P < 0.05$ ) but

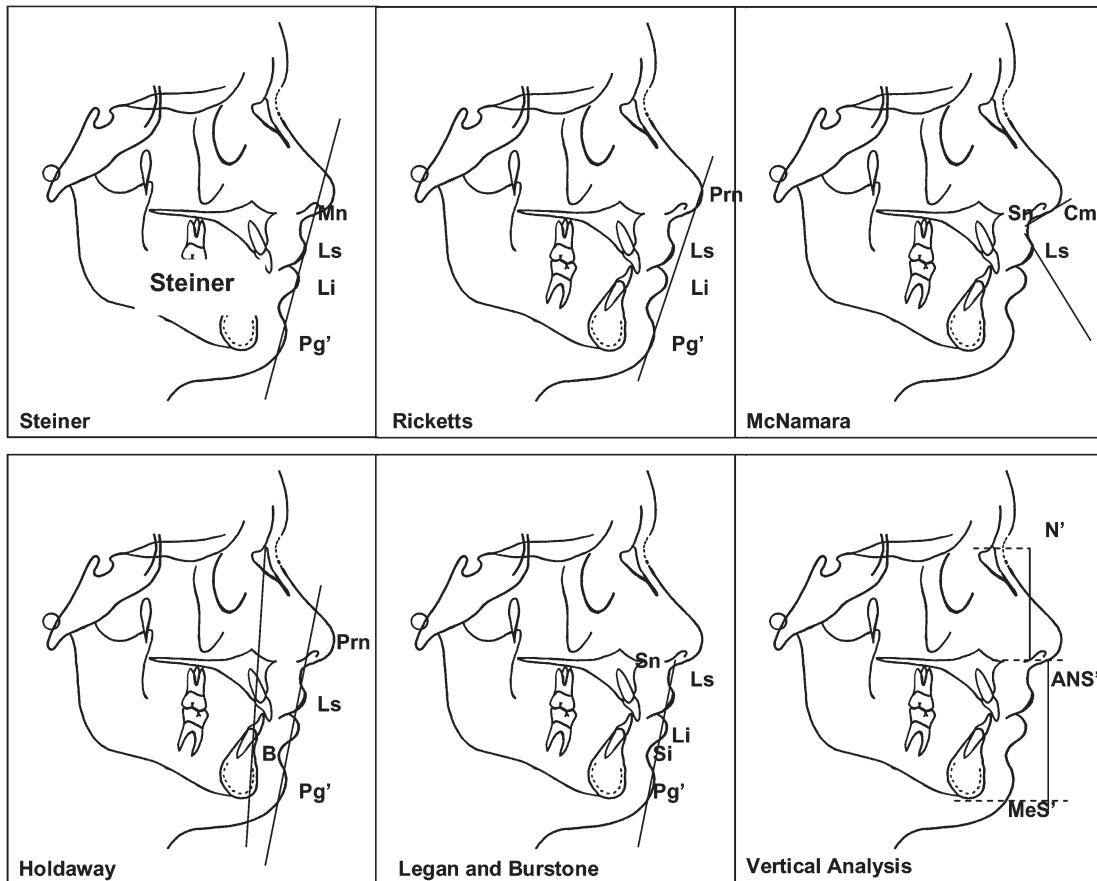


Figure 2 Cephalometric landmarks analysed.

not from T1 to T3. These results demonstrated that the upper lip returned to their original position (Figure 3a, Table 1).

Lower lip measurements (S–Li; E Line–Li; SnPg’–Li) showed retrusion from T1 to T2 and protrusion from T2 to T3, significant from T1 to T2 and T2 to T3 ( $P < 0.05$ ) but not from T1 to T3. The increase in lower lip measurements indicated a downward and backward rotation of the mandible (Figure 3a, Table 1).

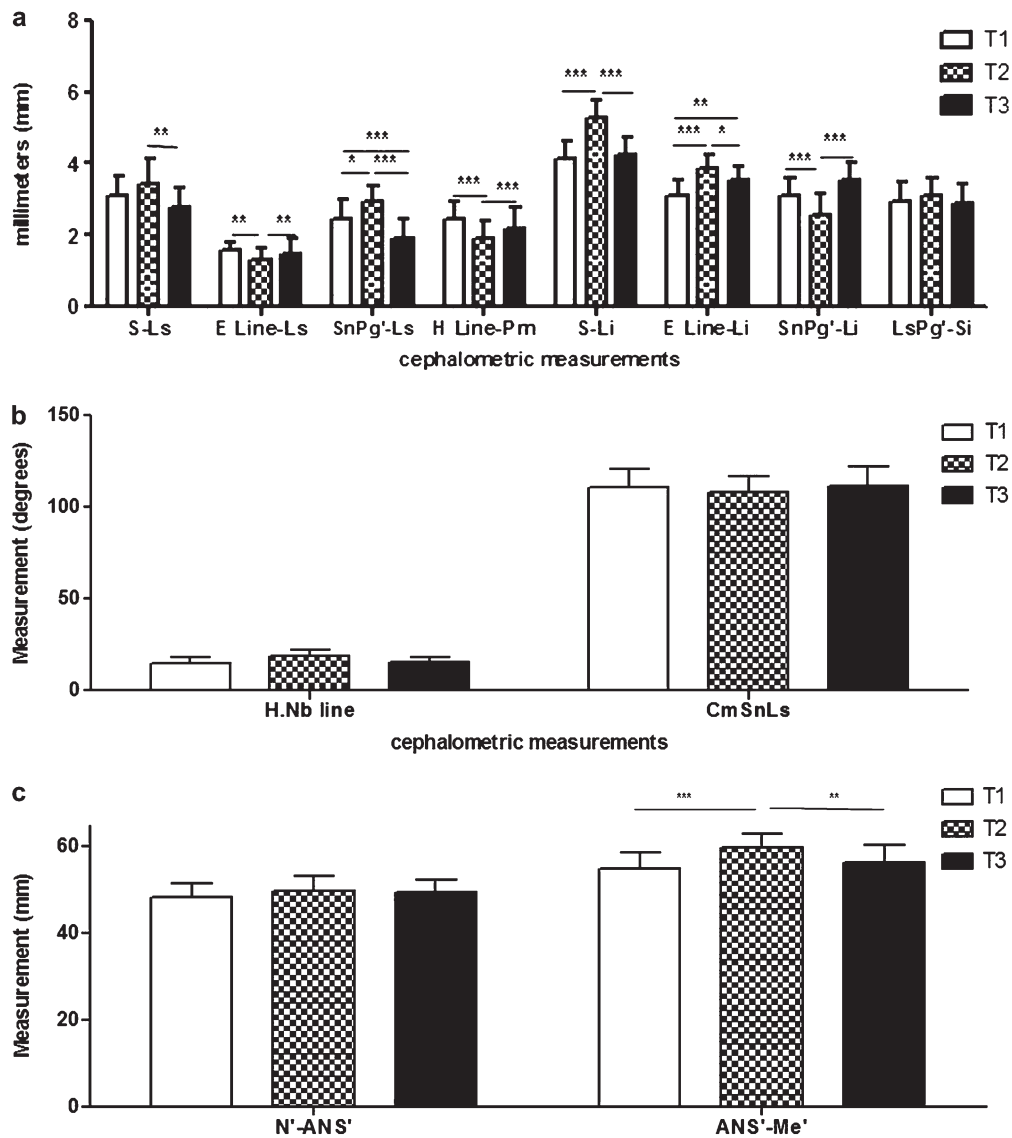
Profile measurements (H Line–Pm) decreased from T1 to T2 ( $P < 0.001$ ) but increased from T2 to T3, although these increases were not statistically significant (Figure 3a, Table 1). Profile analysis using line H.NB showed an increase from T1 to T2 ( $P < 0.001$ ) and a decrease from T2 to T3 ( $P < 0.001$ ) suggesting a downward and backward rotation of the mandible (Figure 3b, Table 1).

The depth of lip–menton sulcus (LsPg’–Si) and nasolabial angle (CmSnLs) showed no significant difference at any time point (Figure 3b, Table 1).

LAFH measurements (ANS’–Me’) increased from T1 to T2 ( $P < 0.001$ ) but decreased from T2 to T3 ( $P < 0.01$ ) although no difference was seen in upper anterior face height (N’–ANS’; Figure 3c, Table 1).

**Discussion**

The objective of the present study was to determine long-term differences in the soft tissue profile following use of a fixed rapid maxillary expander with an occlusal splint and hyrax expansion screw. The advantage of this type of appliance is that no chair time is required for construction, except for taking an impression. None of the patients had any complaints about the appliance. The sample was



**Figure 3** Comparison of upper and lower lip (a), angular (b), and vertical linear (c) cephalometric measurements. Pre-treatment (T1), immediately post-expansion (T2), and after retention (T3).

**Table 1** Means and standard deviations (SD) of angular and linear measurements.

Cephalometric analysis	Line/angle	Mean (SD)			P value
		T1	T2	T3	
Holdaway (1956)	H line–NB line (°)	15.11 (3.22)	19.08 (3.41)	15.31 (2.71)	T1 × T2, ns T1 × T3, ns T2 × T3, ns T1 × T2*** T1 × T3, ns T2 × T3***
	H line–Prn (mm)	2.47 (0.48)	1.91 (0.48)	2.19 (0.36)	T1 × T2, ns T1 × T3, ns T2 × T3***
Steiner (1962)	S line–Ls (mm)	3.11 (0.51)	3.44 (0.67)	2.80 (0.54)	T1 × T2, ns T1 × T3, ns T2 × T3***
	S line–Li (mm)	4.14 (0.49)	5.27 (0.51)	4.22 (0.52)	T1 × T2*** T1 × T3, ns T2 × T3**
Ricketts (1968)	Eline–Ls (mm)	1.55 (0.25)	1.29 (0.32)	1.44 (0.45)	T1 × T2** T1 × T3, ns T2 × T3**
	E line–Li (mm)	3.11 (0.42)	3.87 (0.37)	3.55 (0.38)	T1 × T2*** T1 × T3** T2 × T3*
Legan and Burstone (1980)	SnPg' line–Ls (mm)	2.47 (0.52)	2.91 (0.46)	1.92 (0.52)	T1 × T2* T1 × T3*** T2 × T3***
	SnPg' line–Li (mm)	3.11 (0.48)	2.57 (0.56)	3.55 (0.48)	T1 × T2*** T1 × T3, ns T2 × T3***
	LsPg'–Si (mm)	2.91 (0.56)	3.08 (0.49)	2,87 (0.57)	T1 × T2, ns T1 × T3, ns T2 × T3, ns
McNamara (1984)	CmSnLs (°)	110.90 (9.94)	107.9 (9.05)	111.4 (10.85)	T1 × T2, ns T1 × T3, ns T2 × T3, ns
Vertical analysis	N'–ANS' (mm)	48.32 (3.25)	49.84 (3.44)	49.38 (3.01)	T1 × T2, ns T1 × T3, ns T2 × T3, ns
	ANS'–Me' (mm)	55.01 (3.72)	59.87 (3.07)	56.39 (3.94)	T1 × T2*** T1 × T3, ns T2 × T3**

Ns, not significant. \**P* < 0.05, \*\**P* < 0.01, \*\*\**P* < 0.001.

selected according to their dental stage (mixed dentition) and transverse relationship (posterior skeletal crossbite). Because no differences were found for any cephalometric variables, the sample was not separated according to gender.

RME promotes dental and skeletal alterations that increase the vertical dimension of the lower face, with clockwise rotation of the mandible and retrusion of the chin (Haas, 1965; Wertz, 1970; da Silva Filho *et al.*, 1995; Velazquez *et al.*, 1996; Chang *et al.*, 1997; Sandikçioğlu and Hazar, 1997; Handelman *et al.*, 2000; Cozza *et al.*, 2001). These changes are more significant with the use of a maxillary expander with an occlusal splint bonded to the teeth. In the present study, changes in cephalometric measurements were observed from T1 to T2 and from T2 to T3. These alterations may have direct consequences for the adjacent soft tissues (Lines and Steinhauer, 1974) and may influence the soft tissue facial profile. Some authors have reported that the maxilla may move forward after RME, causing protrusion of the upper lip,

which is an undesirable post-RME effect, especially in adults (Ricketts, 1981). In a study comparing different soft tissue analyses in the evaluation of beauty, patients with more protrusive lips and more retrusive profiles were considered as more attractive (Erbay and Caniklioglu, 2002; Erbay *et al.*, 2002) but large and prominent lip are characteristics of young people (Ricketts, 1968). A change in upper lip position was observed in the present study, but RME did not significantly alter upper lip position from T1 to T3. It should be noted that in this study, the amount of maxillary forward movement was small and might not be clinically significant. Thus, it should not be anticipated that RME will correct a skeletal Class III malocclusion by spontaneous forward maxillary displacement, as suggested by Haas (1970). The use of a reverse-pull headgear in children after RME might be necessary for Class III correction to improve the skeletal relationship and profile. The findings of the present study are in agreement with those of da Silva Filho *et al.* (1991), who found no RME-induced

sagittal change of the maxilla; however, a backward maxillary displacement was observed in their sample after bonded RME treatment (Sarver and Johnston, 1989). If modification of upper lip posture is required, surgically assisted RME might be indicated because a statistically significant but small forward maxillary movement has been reported immediately after surgically assisted RME in adults (Chung *et al.*, 2001).

According to Wertz (1970), there is a tendency to maxillary incisor proclination after RME, and thus slight upper lip retrusion and a discrete increase of the nasolabial angle are expected. However, Sandikçioğlu and Hazar (1997) reported that the maxillary incisors became more proclined (1–SN increased) after RME, which also influenced the facial profile. According to Burstone (1967), any discussion on the lip posture should include not only the vertical but also the sagittal position of the lips. The alterations in the maxillary incisors observed in the present study did not significantly affect nasolabial angle and upper lip position.

The data of the present study show that there was a statistically significant difference between the measurements obtained at T2 (with the appliance in position) and those at T1 and T3 for the following cephalometric landmarks: S–li (T1 and T2; T2 and T3), H Line–Prn (T1 and T2, T2 and T3), E Line–Li (T1 and T2, T2 and T3), E Line–Ls (T1 and T2), ANS'–Me' (T1 and T2, T2 and T3). It may be speculated that the presence of the occlusal splint at T2 caused a clockwise rotation of the mandible, retrusion of the lower lip and an increase of LAFH. This finding is in agreement with previous reports (Davis and Kronman, 1969; Akkaya *et al.*, 1999) that showed mandibular rotation after RME, which may alter the soft tissue facial profile. Previous studies (Davis and Kronman, 1969; Wertz, 1970; da Silva Filho *et al.*, 1991; Basciftci and Karaman, 2002) showed an increase in the mandibular plane angle and LAFH, while da Silva Filho *et al.* (1991) and Sandikçioğlu and Hazar (1997) found a decrease in SNB angle from RME treatment. However, in the present study, these changes were not statistically significant between T1–T3. This may indicate that RME using a fixed rapid maxillary expander with occlusal splint does not cause alterations in the soft tissue facial profile or in the transverse cusp-to-cusp occlusion from RME overexpansion. Downward displacement of the maxilla or mandible or a longer LAFH was not observed because the appliance most likely prevented inclination and extrusion of the molars. The findings of the present study showed an increase in LAFH at T2, which may be attributed to downward and backward clockwise rotation of the mandible due to the presence of the occlusal splint. However, the T3 cephalometric tracings revealed a reduction in LAFH. This is in agreement with Sarver and Johnston (1989), who reported that the mandible did not rotate downward and backward after bonded RME treatment. The increase of LAFH described in the literature indicates the direction of mandibular rotation during orthodontic treatment (Horn, 1992), elucidating the dynamic relationship between anterior and posterior face heights and allowing control of LAFH.

With regard to the skeletal and dental effects of RME on the transverse dimension, many studies have shown increases with the use of a fixed expander in the width of the maxilla, nasal cavity and maxillary arch, vertical changes associated with maxillary displacement, proclination of the posterior teeth and rotation of the mandible (da Silva Filho *et al.*, 1995; Davis and Kronman, 1969; Wertz, 1970; Wertz and Dreskin, 1977; Timms, 1980; Sandikçioğlu and Hazar, 1997; Memikoglu and Iseri, 1999; Cross and McDonald, 2000; Baccetti *et al.*, 2001; Basciftci and Karaman, 2002). In the present study, the mean duration from T1 to T2 was 21 days (range 17–26 days) and from T2 to T3, 6 months. The time interval between T1 and T2 did not exceed 30 days, which virtually eliminates the effect of growth as a variable. Some of the skeletal changes between T2 and T3 could be attributed to growth, although the amount was estimated to be very small.

Different methods and appliances have been introduced for RME (Haas, 1965; Chang *et al.*, 1997; Cozza *et al.*, 2001; Basciftci and Karaman, 2002; McNamara, 2002). The Haas, hyrax, minne expander, cap splint, and the recently developed acrylic bonded RME appliance are examples of those currently used. During expansion with conventional RME appliances, bending of the alveolar structures and buccal tipping of the posterior maxillary teeth lead to posterior rotation of mandible, an open bite, and increased vertical facial dimensions. These factors have a negative effect on facial aesthetics (Haas, 1970, 1973; Wertz, 1970; Wertz and Dreskin, 1977; Sarver and Johnston, 1989; Bishara, 2000). Various RME appliances have been designed to minimize the disadvantages of conventional rapid mandibular expanders. Bonded RME appliances with full occlusal coverage have been reported to have certain advantages over conventional RME appliances (Sarver and Johnston, 1989; McNamara, 2002).

In this study, the rapid maxillary expander was bonded to the occlusal surfaces of the teeth using an occlusal splint (McNamara, 2002) to prevent the occurrence of undesirable dentoskeletal effects produced by the fixed expander (Haas type), i.e. tooth extrusion, which has a direct influence on the facial profile. No significant difference was found between the cephalometric measurements at T1 and T3, which confirms the efficacy of this type of appliance in controlling the soft tissues in children in the mixed dentition phase.

Although the literature shows that RME causes skeletal changes in the sagittal and vertical positions of the maxilla and mandible, these changes may not alter LAFH. However, as there are no specific studies analysing exclusively the soft tissues of the faces of patients treated with RME, the results of this research could not be compared with previous investigations.

## Conclusions

RME using a fixed expander with occlusal splint-produced alterations in the soft tissue facial profile due to the presence of the occlusal splint, but no significant alterations were observed in the soft tissues at the end of the retention period.

## Funding

Brazilian agency FAPESP for financial support (03/22488-2).

## Acknowledgements

The authors are extremely grateful to Carmo Eurípedes Terra Barreto for laboratory assistance. We gratefully acknowledge the Brazilian agency FAPESP for financial support.

## References

- Akkaya S, Lorenzon S, Ucem T T 1999 A comparison of sagittal and vertical effects between bonded rapid and slow maxillary expansion procedures. *European Journal of Orthodontics* 21: 175–180
- Baccetti T, Franchi L, Cameron C G, McNamara J A Jr. 2001 Treatment timing for rapid maxillary expansion. *Angle Orthodontist* 71: 343–350
- Bacon W, Girardin P, Turlot J C 1983 A comparison of cephalometric norms for the African Bantu and a caucasoid population. *European Journal of Orthodontics* 5: 233–240
- Barter M A, Evans W G, Smit G L, Becker P J 1995 Cephalometric analysis of a Sotho-Tswana group. *Journal of the Dental Association of South Africa* 50: 539–544
- Basciftci F A, Karaman A I 2002 Effects of a modified acrylic bonded rapid maxillary expansion appliance and vertical chin cap on dentofacial structures. *Angle Orthodontist* 72: 61–71
- Beane R A, Reimann G, Phillips C, Tulloch C 2003 A cephalometric comparison of black open-bite subjects and black normals. *Angle Orthodontist* 73: 294–300
- Bishara S E 2000 Facial and dental changes in adolescents and their clinical implications. *Angle Orthodontist* 70: 471–483
- Burstone C J 1967 Lip posture and its significance in treatment planning. *American Journal of Orthodontics* 53: 262–284
- Chang J Y, McNamara J A Jr, Herberger T A 1997 A longitudinal study of skeletal side effects induced by rapid maxillary expansion. *American Journal of Orthodontics and Dentofacial Orthopedics* 112: 330–337
- Chung C H, Woo A, Zagarsky J, Vanarsdall R L, Fonseca R J 2001 Maxillary sagittal and vertical displacement induced by surgically assisted rapid palatal expansion. *American Journal of Orthodontics and Dentofacial Orthopedics* 120: 144–148
- Cozza P, Giancotti A, Petrosino A 2001 Rapid palatal expansion in mixed dentition using a modified expander: a cephalometric investigation. *Journal of Orthodontics* 28: 129–134
- Cross D L, McDonald J P 2000 Effect of rapid maxillary expansion on skeletal, dental, and nasal structures: a postero-anterior cephalometric study. *European Journal of Orthodontics* 22: 519–528
- da Silva Filho O G, Boas M C, Capelozza F L 1991 Rapid maxillary expansion in the primary and mixed dentitions: a cephalometric evaluation. *American Journal of Orthodontics and Dentofacial Orthopedics* 100: 171–179
- da Silva Filho O G, Montes L A, Torelly L F 1995 Rapid maxillary expansion in the deciduous and mixed dentition evaluated through posteroanterior cephalometric analysis. *American Journal of Orthodontics and Dentofacial Orthopedics* 107: 268–275
- Davis W M, Kronman J H 1969 Anatomical changes induced by splitting of the midpalatal suture. *Angle Orthodontist* 39: 126–132
- Erbay E F, Caniklioglu C M 2002 Soft tissue profile in Anatolian Turkish adults: Part II. Comparison of different soft tissue analyses in the evaluation of beauty. *American Journal of Orthodontics and Dentofacial Orthopedics* 121: 65–72
- Erbay E F, Caniklioglu C M, Erbay S K 2002 Soft tissue profile in Anatolian Turkish adults: Part I. Evaluation of horizontal lip position using different soft tissue analyses. *American Journal of Orthodontics and Dentofacial Orthopedics* 121: 57–64
- Flynn T R, Ambrogio R I, Zeichner S J 1989 Cephalometric norms for orthognathic surgery in black American adults. *Journal of Oral and Maxillofacial Surgery* 47: 30–39
- Greulich W W, Pyle S I 1959 Radiographic at las of skeletal development of the hand wrist. Stamford University Press, Stanford
- Haas A J 1965 The treatment of maxillary deficiency by opening the midpalatal suture. *Angle Orthodontist* 35: 200–217
- Haas A J 1970 Palatal expansion: just the beginning of dentofacial orthopedics. *American Journal Orthodontics* 57: 219–255
- Haas A J 1973 Rapid palatal expansion: a recommended prerequisite to Class III treatment. *Transactions of the European Orthodontic Society* pp. 311–318
- Handelman C S, Wang L, BeGole E A, Haas A J 2000 Nonsurgical rapid maxillary expansion in adults: report on 47 cases using the Haas expander. *Angle Orthodontist* 70: 129–144
- Holdaway R A 1956 Changes in relationship of points A and B during orthodontic treatment. *American Journal Orthodontics* 42: 176–193
- Horn A J 1992 Facial height index. *American Journal of Orthodontics and Dentofacial Orthopedics* 102: 180–186
- Houston W J B 1983 The analysis of errors in orthodontic measurements. *American Journal Orthodontics* 83: 382–390
- Janson G R, Metaxas A, Woodside D G 1994 Variation in maxillary and mandibular molar and incisor vertical dimension in 12-year-old subjects with excess, normal, and short lower anterior face height. *American Journal of Orthodontics and Dentofacial Orthopedics* 106: 409–418
- Legan H L, Burstone C J 1980 Soft tissue cephalometric analysis for orthognathic surgery. *Journal of Oral Surgery* 38: 744–751
- Linder-Aronson S, Woodside D G 2000 Excess face height malocclusion: etiology, diagnosis and treatment. Quintessence Publishing Company, Chicago
- Lines P A, Steinhauer E W 1974 Diagnosis and treatment planning in surgical orthodontic therapy. *American Journal of Orthodontics* 66: 378–397
- McNamara J A Jr. 1984 A method of cephalometric evaluation. *American Journal Orthodontics* 86: 449–469
- McNamara J A Jr. 2002 Early intervention in the transverse dimension: is it worth the effort? *American Journal of Orthodontics and Dentofacial Orthopedics* 121: 572–574
- Melsen B 1972 A histological study of the influence of sutural morphology and skeletal maturation on rapid palatal expansion in children. *Transactions of the European Orthodontic Society* pp. 499–507
- Memikoglu T U, Iseri H 1999 Effects of a bonded rapid maxillary expansion appliance during orthodontic treatment. *Angle Orthodontist* 69: 251–256
- Ricketts R M 1968 Esthetics, environment, and the law of lip relation. *American Journal of Orthodontics* 54: 272–289
- Ricketts R M 1981 Perspectives in the clinical application of cephalometrics. The first fifty years. *Angle Orthodontist* 51: 115–150
- Sandikçioğlu M, Hazar S 1997 Skeletal and dental changes after maxillary expansion in the mixed dentition. *American Journal of Orthodontics and Dentofacial Orthopedics* 111: 321–327
- Sarver D M, Johnston M W 1989 Skeletal changes in vertical and anterior displacement of the maxilla with bonded rapid palatal expansion appliances. *American Journal of Orthodontics and Dentofacial Orthopedics* 95: 462–466
- Steiner C C 1962 Cephalometrics as a clinical tool. In: Kraus B S, Riedel R (eds). *Vistas in orthodontics* Lea & Febiger, Philadelphia, pp. 131–161
- Timms D J 1980 A study of basal movement with rapid maxillary expansion. *American Journal of Orthodontics* 77: 500–507
- Velazquez P, Benito E, Bravo L A 1996 Rapid maxillary expansion. A study of the long-term effects. *American Journal of Orthodontics and Dentofacial Orthopedics* 109: 361–367
- Wertz R A 1970 Skeletal and dental changes accompanying rapid midpalatal suture opening. *American Journal of Orthodontics* 58: 41–66
- Wertz R, Dreskin M 1977 Midpalatal suture opening: a normative study. *American Journal of Orthodontics* 71: 367–381
- Zimring J F, Isaacson R J 1965 Forces produced by rapid maxillary expansion 3. Forces present during retention. *Angle Orthodontist* 35: 178–186