

Three-dimensional assessment of palatal change in a controlled study of unilateral posterior crossbite correction in the primary dentition

Jasmina Primožič*, Tiziano Baccetti**, Lorenzo Franchi**, Stephen Richmond***, Franc Farčnik* and Maja Ovsenik*

*Department of Dental and Jaw Orthopaedics, Medical Faculty, University of Ljubljana, Slovenia, **Department of Orthodontics, University of Florence, Italy and ***Dental Health and Biological Sciences, Dental School, Cardiff University, UK

Correspondence to: Maja Ovsenik, Department of Dental and Jaw Orthopaedics, Medical Faculty, Hrvatski trg 6, 1000 Ljubljana, Slovenia. E-mail: maja.ovsenik@dom.si

SUMMARY The aim of this study was to quantify the palatal change in three groups of children: children with a unilateral posterior crossbite (TCB) who were treated, children with untreated unilateral posterior crossbite (UCB), and children without a crossbite (NCB). Study casts of 60 Caucasian children in the primary dentition (20 TCB, 20 UCB, and 20 NCB), aged 5.4 ± 0.7 years, were collected at baseline (T1) and at 1-year follow-up (T2). Both TCB and UCB groups had unilateral posterior crossbite and midline deviation. The TCB group was treated using a cemented acrylic splint expander in the upper arch. The study casts were scanned using a laser scanner and palatal surface area, palatal volume, and symmetry of the palatal vault were evaluated and compared between the three groups. At T1, the palatal volume of TCB (2698 mm³) and UCB (2585 mm³) was significantly smaller than that of NCB (3006 mm³; $P < 0.05$, analysis of variance test). After treatment, the palatal volume of the TCB group (3087 mm³) increased and did not differ from the NCB group (3208 mm³), whereas the UCB (2644 mm³) had a significantly smaller palatal volume than the NCB or TCB groups ($P < 0.05$). The increase of palatal volume in the TCB group (389 mm³) was significantly greater than in the UCB (59 mm³) and NCB (202 mm³) groups. The symmetry of the palatal vault was greater than 90 per cent in all three groups at T1 and at T2. Treatment of unilateral posterior crossbite in the primary dentition has a significant effect, particularly on the palatal volume increase.

Introduction

Early treatment of unilateral posterior crossbite is controversial in respect of cost-effectiveness and psychosocial benefit (Tschill *et al.*, 1997; Malandris and Mahoney, 2004; Proffit, 2006). It has been suggested that the preferred time for treatment is in the mixed dentition period (Viazis, 1995), while others consider that orthodontic treatment in the primary dentition period is desirable (Tschill *et al.*, 1997; Thilander *et al.*, 2001; Ovsenik, 2009; Primožic *et al.*, 2009).

Orthodontic treatment at an early developmental phase would be desirable to enhance skeletal, dental development, and correct habits. Dysfunction and malocclusion in early development, especially transverse discrepancies, may lead to temporomandibular joint problems or facial asymmetry (Kiyak, 2006; Proffit, 2006). In unilateral posterior crossbite, the functional asymmetry due to the lateral mandibular shift can contribute to mandibular skeletal asymmetry. In fact, during the growth period, continuous condylar displacement in the glenoid fossa induces differential growth of the condyles (Inui *et al.*, 1999; Kilic *et al.*, 2008). This differential function leads to a thinner masseter muscle

on the crossbite side (Kiliaridis *et al.*, 2000). The level of maximum bite force in children with unilateral posterior crossbite is less than that in children with neutral occlusion (Sonnesen *et al.*, 2001) and differences of the chewing cycles have been found between children with unilateral posterior crossbite and children without malocclusion (Throckmorton *et al.* 2001; Piancino *et al.* 2010; Sever *et al.*, 2010). Early correction of functional problems should prevent adverse dental and facial development (Ninou and Stephens, 1994; Proffit, 2006) as facial asymmetry due to lateral mandibular displacement in unilateral posterior crossbite, if not treated in the primary dentition, may lead to an undesirable growth modification (Ninou and Stephens, 1994; Kilic *et al.*, 2008), which results in facial asymmetry of skeletal origin.

A unilateral crossbite is an anomaly that develops as a result of asymmetrical dental and/or skeletal development. In the primary dentition, unilateral crossbite commonly arises as a result of a narrow maxilla (Primožic *et al.*, 2009) that may be a result of genetic or environmental influences or usually a combination of both. Unilateral crossbite often manifests itself as a discrepancy between the upper and lower

centrelines that may also be associated with facial asymmetry (Allen *et al.*, 2003).

Several methods (Petrén *et al.*, 2003) have been suggested for crossbite correction in the primary dentition period, including active maxillary expansion. The use of an expansion plate with a midline screw in the primary dentition period may result in some skeletal changes as there is less interdigitation of the midpalatal suture (Melsen, 1975), compared to the use of an expansion plate in the mixed or permanent dentition stages when orthodontic forces are considered only light enough to tip teeth (Ngan and Fields, 1995; Baccetti *et al.*, 2001).

Although a considerable number of studies investigating the effects of correcting posterior crossbites have been conducted, the outcomes are very different (Lindner, 1989; Petrén *et al.*, 2003; Malandris and Mahoney, 2004), as objective assessment of upper arch expansion is also difficult. Until recently, the transverse discrepancies between the upper and lower jaws were evaluated on study casts mostly by measuring the linear intercanine and intermolar distances (Sillman, 1964; Thilander and Lennartsson, 2002; Petrén and Bondemark, 2008). However, this method is limited as it does not record tooth inclinations and angulations. Further, it has been reported (Wertz, 1970) that the mandibular shift in unilateral posterior crossbite is the result of a symmetric bilateral constriction of the upper jaw. Until recently, the measurements were mainly performed on study casts by measuring the distances between the teeth cusps and the palatal midline. Therefore, these measurements could have been biased due to tooth position/angulation and midline allocation. In fact, due to the variability of palatal rugae (Damstra *et al.*, 2009), it is very difficult to define the palatal midline and assess the symmetry of the palatal vault before and after expansion therapy.

To overcome these problems, a laser scanner can be used in order to obtain three-dimensional (3D) images of study casts. The 3D images of study casts can be used to measure palatal surface area and palatal volume (Oliveira De Felipe *et al.*, 2008; Primožic *et al.*, 2009).

The aim of this study was to assess the palatal change in three groups of children: children with a unilateral posterior crossbite (TCB) who were treated, children with untreated unilateral posterior crossbite (UCB), and children without a crossbite (NCB). Further objectives were to compare the palatal surface area, palatal volume, and symmetry of the palatal vault.

Subjects and methods

Ethical approval for this study was gained from the Slovenian Ethical Committee at the Medical University in Ljubljana, Slovenia. Study casts of a group of 60 Caucasian children, aged 5.4 ± 0.7 years (20 with unilateral posterior crossbite who were treated—TCB, 20 untreated children

with unilateral posterior crossbite—UCB, and 20 children without unilateral crossbite—NCB), were collected. The TCB group consisted of 10 girls and 10 boys, aged 4.5–6.3 years (mean 5.2; SD 0.7). In the UCB group, there were 12 girls and 8 boys, aged 4.1–7.1 years (mean 5.7; SD 1.0). In the NCB group, there were 8 girls and 12 boys, aged 5.0–6.2 years (mean 5.4; SD 0.3).

The TCB children were randomly selected from a group of children treated at the University of Ljubljana, Slovenia, and that are part of a longitudinal study (Primožic *et al.*, 2011). The UCB were recruited from the patients referred to the Department of Orthodontics of the University of Florence who had declined treatment during the early developmental phases. Only children in the primary dentition period with all the posterior teeth (canines and primary molars) in crossbite on one side and a midline deviation of at least 2 mm due to a functional mandibular shift were included. The functional mandibular shift was assessed clinically by an experienced orthodontist (MO).

In both the TCB and UCB group, 11 children had a functional shift on the right side, 9 children on the left side, for a total of 22 functional shifts on the right side and 18 on the left side. Further, the total transverse discrepancy between the upper and lower jaw in all crossbite children was approximately 3.5 mm on average. The NCB children were randomly selected from a local kindergarten in Slovenia.

The majority of the crossbite children had one or a combination of respiratory, deglutition, or mastication problems, while in the NCB group, only the minority of children showed deglutition impairment.

The TCB group was treated using an acrylic plate with a midline screw to expand the maxillary arch. The acrylic plate with bite plate was cemented on the upper primary molars. The screw was activated 0.25 mm every 2 days for 4 weeks to obtain a slight hypercorrection and was left in place for 4 more weeks without activation. The bite plate was removed and the acrylic plate was then used as a removable retainer for 4 months. Therefore, the expected expansion in TCB subjects would be approximately 4 mm, and active therapy was followed by about 4 months of retention.

Impressions of the dental arches were obtained at baseline (T1) and at 1-year follow-up (T2) that corresponded to 6-months post-treatment period in TCB group. Study casts were scanned at a distance of 60 cm with a Konica/Minolta Vivid 910 laser scanner using a lens with a focal distance of 25 mm. With this lens, the scanner has a reported accuracy of 0.22 mm (Keating, 2004).

Each scan of the study cast was pre-processed to remove unwanted data. In order to measure the palatal surface area and calculate the palatal volume, the boundaries of the palate must be defined. The gingival plane and a distal plane were used as boundaries for the palate. The gingival plane was created by connecting the midpoints of the dento-gingival

junction of all primary teeth. The distal plane was created through two points at the distal surface of the second primary molar perpendicular to the gingival plane (Figure 1a and 1b). The palatal surface area (Figure 1a) and the palatal volume (Figure 1b) were then calculated. Further, symmetry of the palatal vault surface was evaluated (Figure 2). To check for left/right symmetry, the palatal vault was mirrored on the midsagittal plane. The percentage of shell to mirrored shells coinciding within 0.5 mm was recorded.

The validity of the methods used has been reported elsewhere (Hoyte, 2007).

Statistical analysis

The Statistical Package for Social Science (SPSS Inc., Chicago, Illinois, USA) was used for statistical analysis. Analysis of variance (ANOVA) test was used to test the differences of palatal surface area and volume, after exploratory Kolmogorov–Smirnov test revealed normal distribution of the

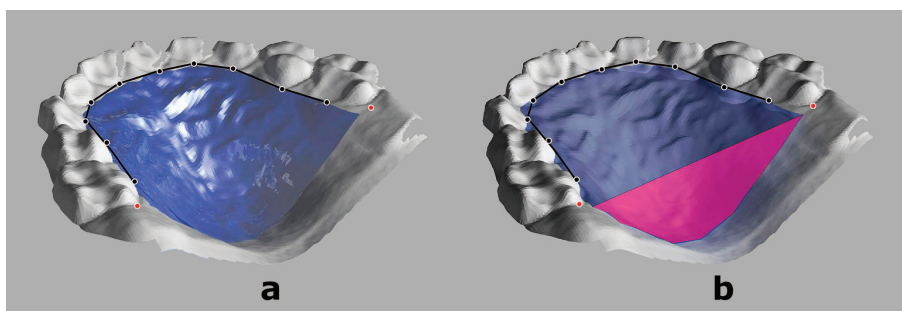


Figure 1 Assessment of palatal surface area (a, light blue) and palatal volume (b, dark blue): a gingival plane (black) constructed through the midpoints of the dentogingival junction (black dots) of all erupted primary teeth and a distal plane (pink), constructed through two points (red dots) at the distal surface of the second primary molars, were used as boundaries of the palate.




Figure 2 Assessment of symmetry of the palatal vault: the palatal region of the original model shell (light blue) was flipped horizontally to obtain the palatal region of the mirrored model shell (dark blue) and the percentage of overlapping of the original and mirrored shells was used to assess symmetry of the palatal vault.

data in the three groups at T1 and T2. The Kruskal–Wallis test was used to test differences of palatal vault symmetry between the three groups. The results were considered to be significant at values of $P < 0.05$. The power of the study was calculated on the basis of the sample size of the three groups and of an effect size equal to 1 (Cohen, 1992). The power was 0.80 at an alpha level of 0.05. Method error for the surface, volume, and symmetry measures was calculated, with intraclass correlation coefficient values ranging from 0.90 to 0.95.

Results

The palatal surface area, palatal volume, and the change of palatal surface area and volume from T1 to T2 are summarized in Table 1. The P values (ANOVA test) for statistically significant differences between the three groups for the observed parameters are listed in Table 2. No significant differences in the observed parameters were found between boys and girls (Student t -test, $P > 0.05$).

At baseline (T1), the greatest palatal surface area and palatal volume were observed in the NCB group compared to the TCB and UCB groups. A statistically significant difference was observed for palatal surface area and palatal volume between the NCB and TCB ($P = 0.031$ and 0.024 , respectively) and for palatal volume between the NCB and UCB groups ($P = 0.007$). No differences for palatal surface

area or for palatal volume were observed at T1 between the TCB and UCB groups ($P > 0.05$). The observed symmetry of the palatal vault in terms of shell to mirrored shell overlapping was 93.91 per cent in the TCB, 91.77 per cent in the UCB, and 94.98 per cent in the NCB group at T1, with no statistically significant differences between the three groups ($P > 0.05$).

At 1-year follow-up (T2), 6 months after the end of active treatment, three relapses (15 per cent) were observed in the treated group, while no self-corrections were observed in the untreated group. At T2, no statistically significant differences for palatal surface area were observed between the three groups ($P > 0.05$). However, no statistically significant difference for palatal volume was observed between the treated group (TCB) and the NCB group ($P > 0.05$), while a statistically significant difference for palatal volume was observed between the UCB and NCB groups ($P = 0.001$) and between the TCB and UCB groups ($P = 0.002$). Further, the increase of the palatal surface area and palatal volume was significantly greater in the TCB group compared to the UCB group ($P < 0.05$) and to the NCB group ($P < 0.05$). No differences between the increase of the palatal surface area and palatal volume were observed between the NCB and UCB groups ($P > 0.05$). The observed symmetry of the palatal vault in terms of shell to mirrored shell overlapping at T2 was 92.93 per cent in the TCB, 91.84 per cent in the UCB, and 94.14 per cent in the NCB group,

Table 1 Descriptive statistics for palatal surface area (mm²) and palatal volumes (mm³) for children with a treated crossbite (TCB), untreated crossbite (UCB), and without crossbite (NCB) at baseline (T1) and at 1-year follow-up (T2) and changes of the parameters over the observed period of time.

	Group	Mean palatal surface area (mm ²)	SD (mm ²)	Mean palatal volume (mm ³)	SD (mm ³)
T1	TCB	741.85	55.32	2697.90	365.92
	UCB	763.65	86.03	2585.25	464.38
	NCB	791.85	83.02	3006.30	460.35
T2	TCB	816.95	67.29	3086.95	410.85
	UCB	800.25	87.45	2644.25	446.12
	NCB	829.95	96.96	3208.10	508.70
Change from T1 to T2	TCB	75.10	38.35	389.05	230.25
	UCB	36.60	39.60	59.00	232.79
	NCB	38.10	50.22	201.80	244.07

Table 2 Statistically significant differences (P values, ANOVA test) between children with a treated crossbite (TCB), untreated crossbite (UCB), and without crossbite (NCB) for palatal surface area and palatal volume at baseline (T1) and at 1-year follow-up (T2) and changes of the parameters over the observed period of time.

Parameter	TCB	NCB	UCB	NCB	TCB	UCB
Palatal surface area T1		0.031		0.298		0.347
Palatal surface area T2		0.625		0.315		0.503
Change of palatal surface area		0.013		0.917		0.003
Palatal volume T1		0.024		0.007		0.399
Palatal volume T2		0.413		0.001		0.002
Change of palatal volume		0.017		0.066		0.000

Shaded portions denote statistically significant difference, $P < 0.05$.

with no statistically significant differences between the three groups ($P > 0.05$).

Discussion

Although early treatment of unilateral posterior crossbite is often recommended to create conditions for normal occlusal and craniofacial development (Petrén *et al.*, 2003), treatment of the malocclusion in the primary dentition period is still questionable in respect of cost-effectiveness (Tschill *et al.*, 1997; Malandris and Mahoney; 2004, Proffit, 2006). It has been suggested that the later crossbites are treated, the greater the risk of damage to the temporomandibular joint (Pirttiniemi *et al.*, 1990; Sonnesen *et al.*, 2001). Further, this malocclusion trait is also associated with asymmetrical muscular function (Ingervall and Thilander, 1975; Ferrario *et al.*, 1999) that affects the elevator muscles and bite force (Sonnesen *et al.*, 2001). It appears that the only indication for correction in the primary dentition is where aesthetics or function may otherwise be compromised (Malandris and Mahoney, 2004).

Different treatment approaches such as selective grinding of teeth, expansion plates, and Quadhelix, are used for crossbite correction at different developmental stages (Lindner, 1989; Malandris and Mahoney, 2004). In this study, treatment was started in the primary dentition using a cemented acrylic plate with a midline screw for palatal expansion. After correction, the plate was decemented and used as a removable retention plate, which has been shown to successfully correct 85 per cent of posterior crossbites in the primary dentition (De Boer and Steenks, 1997). In this study, the same success rate was observed, with 15 per cent of children showing relapse.

Until recently, crossbite correction was evaluated on study casts mostly by measuring the intercanine and intermolar distances (Sillman, 1964; Thilander and Lennartsson, 2002; Petrén and Bondemark, 2008). However, this method could not exclude bias in assessing treatment success of crossbite correction due to the buccal teeth tipping. To overcome this problem, the palatal surface area and palatal volume were measured in this investigation by means of 3D laser scanning technology.

At the time of the first observation, children with crossbite (TCB and UCB) had a statistically significant smaller palatal volume than the NCB group. However, after treatment and a period of retention, there were no differences between the TCB and the NCB groups, while differences were observed between the UCB and the TCB groups and between the UCB and the NCB groups. Further, the increase of palatal surface area and palatal volume in treated children was statistically significantly greater than the increase of palatal surface area and palatal volume due to growth in the two untreated groups.

Both, the palatal surface area and the palatal volume of the treated group statistically significantly increased after treatment (T2), as reported in a previous study (Primožic *et al.*, 2009), showing that treatment with the expansion

plate in the primary dentition period has at least partly a skeletal effect. In fact, it has been shown in previous studies that crossbite correction after active expansion is partially due to opening and bone apposition in the midpalatal suture and partially due to alveolar tipping (Bell and LeCompte, 1981). While the palatal volume increase can be a result of both, the palatal surface area increase is mainly a consequence of bone apposition in the midpalatal suture. Our study showed that both the parameters increased significantly more in the treated group compared to the untreated controls and to the non crossbite group in whom the observed increase was only due to growth in the midpalatal suture. The protocol employed, which involved the use of a cemented appliance during active expansion and a semi-slow rate of expansion (0.25 mm every 2 days), may have played a role in the favourable effects of therapy.

Although previous studies reported mild bilateral constriction of the upper jaw in unilateral posterior crossbite (Lindner, 1989; Thilander and Lennartsson, 2002), only intercanine and intermolar distances were measured in these studies, though no comparisons between the left and right sides in respect to the midpalatal suture of the maxilla were reported. In this study, symmetry of the palatal vault surface was evaluated in terms of palatal shell to mirrored palatal shell overlapping. A high percentage (over 90 per cent) of overlapping of the left and right side of the palatal vault was observed in all three groups at baseline and at 1-year follow-up. This seems to confirm that children with unilateral posterior crossbite have a symmetric surface of the palatal vault, which can however be constricted either bilaterally or unilaterally. Therefore, further research is needed in terms of assessment of the symmetry of the palatal vault space to elucidate this problem.

Conclusions

According to the results of this study, children with unilateral posterior crossbite show a symmetric surface of the palatal vault. A favourable outcome of treatment of unilateral posterior crossbites in the primary dentition period might be also the skeletal effect of therapy on the maxillary structures in terms of increased palatal surface area and volume, in conjunction with a high success rate 1 year after the end of therapy.

Funding

European Orthodontic Society Research Grant and Slovenian Research Agency.

Acknowledgement

The first author would like to thank Dr Alexei Zhurov for his unselfish help and support during her research work, in particular for the present article that was given the WBJ Houston award in Istanbul 2011.

References

- Allen D, Rebellato J, Sheats R, Ceron A M 2003 Skeletal and dental contributions to posterior crossbites. *Angle Orthodontist* 73: 515–524
- Baccetti T, Franchi L, Cameron C G, McNamara J A Jr 2001 Treatment timing for rapid maxillary expansion. *Angle Orthodontist* 71: 343–350
- Bell R A, LeCompte E J 1981 The effects of maxillary expansion using a quad-helix appliance during the deciduous and mixed dentitions. *American Journal of Orthodontics* 79: 152–161
- Cohen J 1992 A power primer. *Psychological Bulletin* 112: 155–159
- Damstra J, Mistry D, Cruz C, Ren Y 2009 Antero-posterior and transverse changes in the positions of palatal rugae after rapid maxillary expansion. *European Journal of Orthodontics* 31: 327–332
- De Boer M, Steenks M 1997 Functional unilateral posterior cross-bite. Orthodontic and functional aspects. *Journal of Oral Rehabilitation* 24: 614–623
- Ferrario V F, Sforza C, Serrao G 1999 The influence of cross-bite on the coordinated electromyographic activity of human masticatory muscles during mastication. *Journal of Oral Rehabilitation* 26: 575–581
- Hoyte T A 2007 Monitoring three dimensional changes in treated and untreated dentitions. Thesis, Cardiff University, Wales
- Ingervall B, Thilander B 1975 Activity of temporal and masseter muscles in children with lateral forced bite. *Angle Orthodontist* 45: 249–258
- Inui M, Fushima K, Sato S 1999 Facial asymmetry in temporomandibular joint disorders. *Journal of Oral Rehabilitation* 26: 402–406
- Keating A P 2004 An evaluation of virtual and actual three-dimensional occlusal records. Thesis, Cardiff University, Wales
- Kiliaridis S, Katsaros C, Raadsheer M C, Mahboubi P H 2000 Bilateral masseter muscle thickness in growing individuals with unilateral posterior cross-bite. *Journal of Dental Research* 79: 497(Abstract)
- Kilic N, Kiki A, Oktay H 2008 Condylar asymmetry in unilateral posterior cross-bite patients. *American Journal of Orthodontics and Dentofacial Orthopedics* 133: 382–387
- Kiyak H A 2006 Patients' and parents' expectations from early treatment. *American Journal of Orthodontics and Dentofacial Orthopedics* 129: S550–S554
- Lindner A 1989 Longitudinal study on the effect of early interceptive treatment in 4-year old children with unilateral cross-bite. *Scandinavian Journal of Dental Research* 97: 432–438
- Malandris A, Mahoney E K 2004 Aetiology, diagnosis and treatment of posterior cross-bites in the primary dentition. *International Journal of Pediatric Dentistry* 14: 155–166
- Melsen B 1975 Palatal growth studied on human autopsy material. A histologic microradiographic study. *American Journal of Orthodontics* 68: 42–54
- Ngan P, Fields H 1995 Orthodontic diagnosis and treatment planning in the primary dentition. *Journal of Dentistry for Children* 62: 25–33
- Ninou S, Stephens C 1994 The early treatment of posterior cross-bites: a review of continuing controversies. *Dental Update* 21: 420–426
- Oliveira De Felipe N L, Da Silveira A C, Viana G, Kusnoto B, Smith B, Evans C A 2008 Relationship between rapid maxillary expansion and nasal cavity size and airway resistance: short- and long-term effects. *American Journal of Orthodontics and Dentofacial Orthopedics* 134: 370–382
- Ovsenik M 2009 Incorrect orofacial functions until 5 years of age and their association with posterior cross-bite. *American Journal of Orthodontics and Dentofacial Orthopedics* 136: 375–381
- Petrén S, Bondemark L 2008 Correction of unilateral posterior cross-bite in the mixed dentition: a randomized controlled trial. *American Journal of Orthodontics and Dentofacial Orthopedics* 133: 790.e7–790.e13
- Petrén S, Bondemark L, Söderfeldt B 2003 A systematic review concerning early orthodontic treatment of unilateral posterior cross-bite. *Angle Orthodontist* 73: 588–596
- Piancino M G, Talpone F, Vallelonga T, Frongia G, Debernardi C L, Bracco P 2010 Slow or rapid palatal expansion for early treatment of unilateral posterior crossbite? Evaluation of the reverse chewing cycles correction. *Progress in Orthodontics* 11: 138–144
- Pirttiniemi P, Kantomaa T, Lahtela P 1990 Relationship between craniofacial and condyle path asymmetry in unilateral cross-bite patients. *European Journal of Orthodontics* 12: 408–413
- Primožic J, Ovsenik M, Richmond S, Kau C H, Zhurov A 2009 Early cross-bite correction: a three-dimensional evaluation. *European Journal of Orthodontics* 31: 352–356
- Primožic J, Richmond S, Kau C H, Zhurov A, Ovsenik M 2011 Three-dimensional evaluation of early crossbite correction: a longitudinal study. *European Journal of Orthodontics* 2011 Feb 10. [Epub ahead of print]
- Profit W R 2006 The timing of early treatment: an overview. *American Journal of Orthodontics and Dentofacial Orthopedics* 120: S47–S49
- Sever E, Marion L, Ovsenik M 2010 Relationship between masticatory cycle morphology and unilateral crossbite in the primary dentition. *European Journal of Orthodontics* 2010 Nov 30. [Epub ahead of print]
- Sillman J H 1964 Dimensional changes of the dental arches: Longitudinal study from birth to 25 years. *American Journal of Orthodontics* 50: 824–884
- Sonnesen L, Bakke M, Solow B 2001 Bite force in pre-orthodontic children with unilateral cross-bite. *European Journal of Orthodontics* 23: 741–749
- Thilander B, Lennartsson B 2002 A study of children with unilateral posterior cross-bite, treated and untreated, in the deciduous dentition—occlusal and skeletal characteristics of significance in predicting the long-term outcome. *Journal of Orofacial Orthopedics* 63: 371–383
- Thilander B, Pena L, Infante C, Parada S S, Mayorga C 2001 Prevalence of malocclusion and orthodontic treatment need in children and adolescents in Bogota, Colombia. An epidemiological study related to different stages of dental development. *European Journal of Orthodontics* 23: 157–176
- Throckmorton G S, Buschang P H, Hayasaki H, Pinto A S 2001 Changes in the masticatory cycle following treatment of posterior unilateral crossbite in children. *American Journal of Orthodontics and Dentofacial Orthopaedics* 120: 521–529
- Tschill P, Bacon W, Sonko A 1997 Malocclusion in the deciduous dentition of Caucasian children. *European Journal of Orthodontics* 19: 361–367
- Viazis A D 1995 Efficient orthodontic treatment timing. *American Journal of Orthodontics and Dentofacial Orthopedics* 108: 560–561
- Wertz R A 1970 Skeletal and dental changes accompanying rapid midpalatal suture opening. *American Journal of Orthodontics* 58: 41–66