

Cite this article as: Ponti A, Qanadli SD, Kirsch M, Tapponnier M. Left sinus of Valsalva aneurysm as a cause of chronic stable angina. *Interact CardioVasc Thorac Surg* 2017;24:967–8.

## Left sinus of Valsalva aneurysm as a cause of chronic stable angina

Alexandre Ponti<sup>a,b,\*</sup>, Salah D. Qanadli<sup>a</sup>, Matthias Kirsch<sup>b</sup> and Maxime Tapponnier<sup>c,d</sup>

<sup>a</sup> Department of Diagnostic and Interventional Radiology, Lausanne University Hospital, Lausanne, Switzerland

<sup>b</sup> Department of Cardiac Surgery, Lausanne University Hospital, Lausanne, Switzerland

<sup>c</sup> Department of Cardiology, Lausanne University Hospital, Lausanne, Switzerland

<sup>d</sup> Department of Cardiology, Valais Hospital, Valais, Switzerland

\* Corresponding author. Lausanne University Hospital, Rue du Bugnon 46, 1011 Lausanne, Switzerland. Tel: +41-79-5560232; fax: +41-21-3144443; e-mail: alexandre.ponti@gmail.com (A. Ponti).

Received 19 November 2016; received in revised form 6 January 2017; accepted 17 January 2017

### Abstract

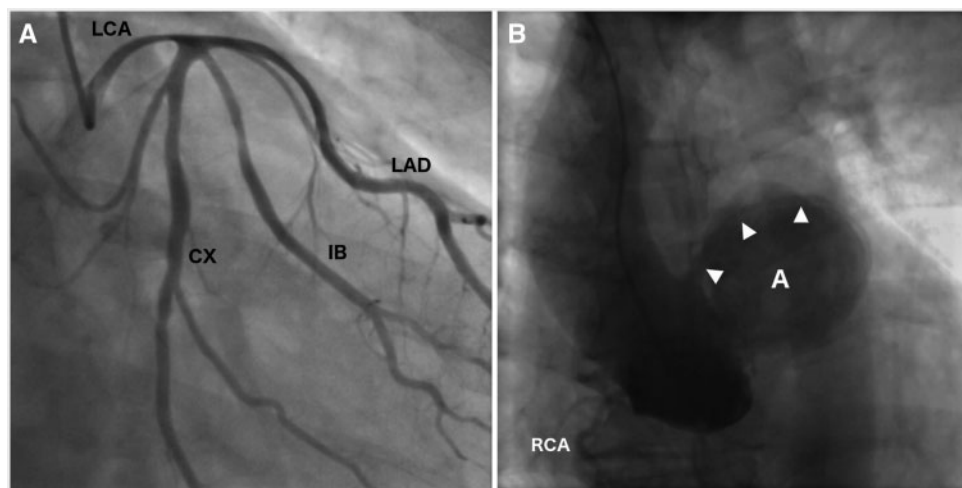
Sinus of Valsalva aneurysms are unusual, particularly when located on the left coronary sinus. They are mainly asymptomatic, however once ruptured, they are associated with high mortality. We present hereinafter an atypical case of a 71-year-old patient with an unruptured left sinus of Valsalva aneurysm causing myocardial ischaemia due to a compressed left main coronary artery. Surgical endoaneurysmorrhaphy was performed; however, a dehiscence of the suture line between the patch and the aortic wall required additional percutaneous implantation of a vascular occluder.

**Keywords:** Sinus of Valsalva aneurysm • Cardiac CT • Surgery • Vascular plug • Embolization

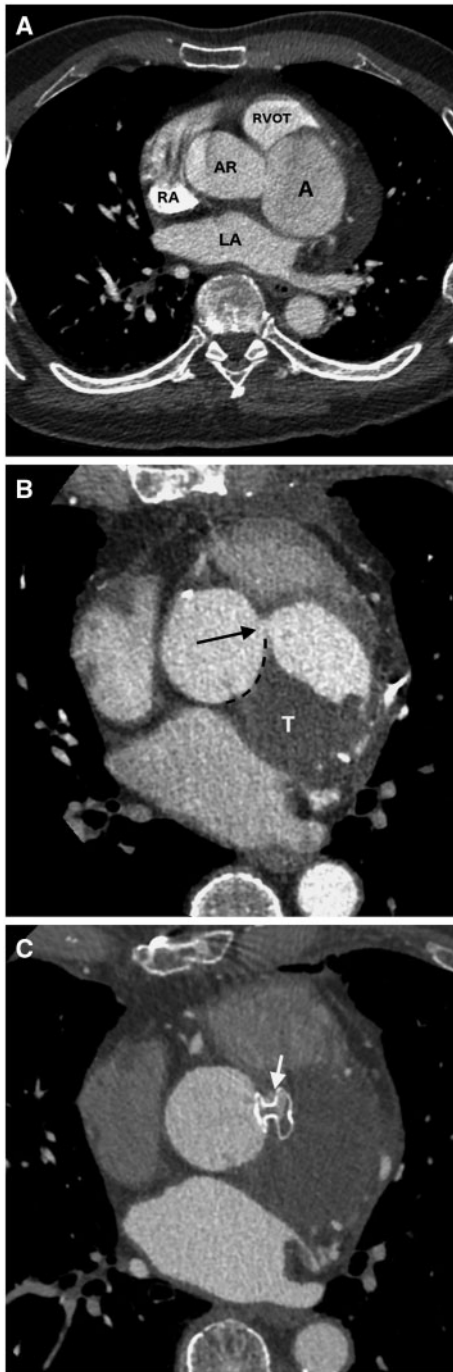### CASE REPORT

A 71-year-old male patient was examined for retrosternal chest pain and dyspnoea occurring during efforts since few months. Exercise stress test was positive for myocardial ischaemia with the appearance of ST depression from V4 to V5 and typical retrosternal chest pain. The patient was subsequently addressed for coronary angiography. This examination revealed minimal coronary sclerosis but an elongated left main coronary artery

compressed by a saccular aneurysm of 5 cm originating from the left coronary cusp. The caudal part of the aneurysm collar was marked out by the aortic valve and by the ostium of the left main stem on the top part (Fig. 1A and B). At transthoracic echocardiogram, the aneurysm was easily identifiable at the left coronary sinus with spontaneous contrast inside suggesting low flow and blood stasis. The aortic valve was tricuspid with only mild regurgitation. Cardiac computed tomography angiography was then performed and provided 3-dimensional assessment of the



**Figure 1:** (A) Selective angiography of the left main coronary artery (LCA) with trifurcation into left anterior descending (LAD), intermediate (IB) and circumflex (CX) branches. The left main coronary artery and proximal part of the three arteries are displaced superiorly and compressed. (B) Non-selective angiography into the aortic root showing the aneurysm of the left coronary sinus (LCS) (A). The LCA is also demonstrated repressed above the aneurysm (arrowheads). The right coronary artery (RCA) is unaffected.



**Figure 2:** (A) Cardiac computed tomography angiography (CCTA) showing the aneurysm (A) originating from the left coronary sinus. Note the very thin septum between the aneurysm and the right ventricular outflow tract (RVOT). Postoperative CCTA 2 (B) and 5 months (C) after surgery. (B) Axial view demonstrating the leak (arrow) at the anterior border of the patch (dotted line) used to close the aneurysm with only partial thrombosis (T) of the aneurysm lumen. (C) Same view after the implantation of the Amplatzer septal occluder showing a very small residual leak (arrows). AR: aortic root; LA: left atrium; RA: right atrium.

aneurysm and surrounding tissues (Fig. 2A). The patient received a diagnosis of left sinus of Valsalva aneurysm and subsequently underwent surgical endoaneurysmorrhaphy under extracorporeal circulation using a Dacron patch ( $3 \times 2 \text{ cm}^2$ ) to close the opening of the aneurysm, thereby reconstructing the left coronary sinus. Due to preoperative myocardial ischaemic symptoms, 3

coronary bypasses were also performed (left internal mammary artery to the left anterior descending artery and a sequential vein bypass to an intermediate branch and a circumflex marginal branch). Postoperative outcome was satisfying showing no complications. During subsequent echocardiography and cardiac computed tomography angiography, partial thrombosis of the aneurysm was identified caused by a dehiscence located on the suture line (Fig. 2B). The patient was readmitted for additional percutaneous procedure. Selective catheterization through the residual neck was performed allowing positioning of non-vascular plug (Amplatzer septal occluder 8 mm, AGA Medical). Two months after the implantation, a follow-up cardiac computed tomography angiography showed almost complete thrombosis of the aneurysm lumen (Fig. 2C). Due to a past transient ischaemic attack, the patient already received Clopidogrel (75 mg/day) before surgery. The treatment was continued throughout.

## DISCUSSION

Sinus of Valsalva aneurysms are unusual, reported in 0.09% in a review of several autopsy series [1]. They affect the right coronary sinus in 65–86% of cases, the noncoronary sinus in 10–30% and the left coronary sinus in only 2–5% [2]. Their origin can be either acquired or congenital. While mostly asymptomatic, they can also cause compression of adjacent structures such as the coronary arteries, as in our case, or the outflow tracts causing heart failure. Expansion of the aneurysm into the ventricular septum has also been reported to cause arrhythmia. Stagnation of blood may lead to embolization into coronary or peripheral arteries. Architectural distortion and haemodynamic alterations caused by the aneurysm may also induce aortic valve regurgitation or increase the risk of endocarditis. Evolution towards rupture can be spontaneous or induced by trauma. Rupture into the pericardial sac is frequently fatal. However, sinus of Valsalva aneurysm rupture can also cause shunting of blood into cardiac chambers [3]. Depending on the acuteness of rupture and quantity of blood shunting, clinical manifestations may vary from a few symptoms to acute heart failure. Most patients die within 2 years following rupture [4]. Currently, most authors recommend to treat aneurysm as soon as discovered, even if asymptomatic, as current outcomes of surgery are excellent compared with the high risk of death linked to its natural evolution [3, 5].

**Conflict of interest:** none declared.

## REFERENCES

- [1] Smith WA. Aneurysm of the sinus of Valsalva: with report of two cases. *J Am Med Assoc* 1914;LXII:1878.
- [2] Galicia-Tornell MM, Marín-Solís B, Mercado-Astorga O, Espinoza-Anguiano S, Martínez-Martínez M, Villalpando-Mendoza E. Sinus of Valsalva aneurysm with rupture. Case report and literature review. *Cir Cir* 2009;77:441–5.
- [3] Takach TJ, Reul GJ, Duncan JM, Cooley DA, Livesay JJ, Ott DA *et al.* Sinus of Valsalva aneurysm or fistula: management and outcome. *Ann Thorac Surg* 1999;68:1573–7.
- [4] Moustafa S, Mookadam F, Cooper L, Adam G, Zehr K, Stulak J *et al.* Sinus of Valsalva aneurysms—47 years of a single center experience and systematic overview of published reports. *Am J Cardiol* 2007;99:1159–64.
- [5] van Son JA, Danielson GK, Schaff HV, Orszulak TA, Edwards WD, Seward JB. Long-term outcome of surgical repair of ruptured sinus of Valsalva aneurysm. *Circulation* 1994;90:1120–29.