

Acknowledgements. We would like to acknowledge Prof. Timothy Goodship and his team at the Institute of Human Genetics, Newcastle University, UK, for performing the complement studies.

Conflict of interest statement. None declared.

References

1. Dong JF, Moake JL, Nolasco L *et al.* ADAMTS-13 rapidly cleaves newly secreted ultralarge von Willebrand factor multimers on the endothelial surface under flowing conditions. *Blood* 2002; 100: 4033–4039
2. Furlan M, Robles R, Galbusera M *et al.* von Willebrand factor-cleaving protease in thrombotic thrombocytopenic purpura and the hemolytic-uremic syndrome. *N Engl J Med* 1998; 339: 1578–1584
3. Kokame K, Matsumoto M, Soejima K *et al.* Mutations and common polymorphisms in ADAMTS13 gene responsible for von Willebrand factor-cleaving protease activity. *Proc Natl Acad Sci USA* 2002; 99: 11902–11907
4. Sarode R. Atypical presentations of thrombotic thrombocytopenic purpura: a review. *J Clin Apher* 2009; 24: 47–52
5. Sarode R, Gottschall JL, Aster RH *et al.* Thrombotic thrombocytopenic purpura: early and late responders. *Am J Hematol* 1997; 54: 102–107
6. Noris M, Bucchioni S, Galbusera M *et al.* Complement factor H mutation in familial thrombotic thrombocytopenic purpura with ADAMTS13 deficiency and renal involvement. *J Am Soc Nephrol* 2005; 16: 1177–1183
7. Manea M, Kristoffersson A, Schneppenheimer R *et al.* Podocytes express ADAMTS13 in normal renal cortex and in patients with thrombotic thrombocytopenic purpura. *Br J Haematol* 2007; 138: 651–662
8. Plaimauer B, Fuhrmann J, Mohr G *et al.* Modulation of ADAMTS13 secretion and specific activity by a combination of common amino acid polymorphisms and a missense mutation. *Blood* 2006; 107: 118–125
9. Antoine G, Zimmermann K, Plaimauer B *et al.* ADAMTS13 gene defects in two brothers with constitutional thrombotic thrombocytopenic purpura and normalization of von Willebrand factor-cleaving protease activity by recombinant human ADAMTS13. *Br J Haematol* 2003; 120: 821–824

Received for publication: 21.9.10; Accepted in revised form: 24.9.10

Nephrol Dial Transplant (2011) 26: 744–747
doi: 10.1093/ndt/gfq663
Advance Access publication 27 October 2010

Apparent renal disease due to elevated creatinine levels associated with the use of boldenone

Georgia Winnett¹, Lesley Cranfield² and Michael Almond¹

¹Renal Medicine and ²Chemical Pathology Southend University Hospital NHS Trust, Westcliff on Sea, Essex, UK

Correspondence and offprint requests to: Michael Almond; E-mail: mike.almond@southend.nhs.uk

Abstract

The widespread use of reporting estimated glomerular filtration rate (eGFR) alongside serum creatinine has led to a heightened appreciation of renal disease. However, creatinine is recognized as an insensitive marker of true GFR and therefore can lead to misdiagnosis of renal dysfunction in the absence of true pathology. We report the case of a 37-year-old male referred due to abnormal eGFR and creatinine in the absence of clinical signs, symptoms or other biochemical abnormalities of renal disease. Subsequent investigations based on a high index of suspicion for exogenous substance abuse led to a novel observation of significantly raised creatinine due to the presence of boldenone, an equine anabolic steroid commonly abused in body building.

Keywords: anabolic steroids; boldenone; disproportionately high creatinine

Case report

A 37-year-old male admitted to hospital was referred to the medical take due to perceived abnormal renal function. His GP had checked his bloods 5 days previously as part of routine screening for his repeat prescription of citalopram and found his creatinine elevated at 338 µmol/L, equating to an estimated GFR of 18 as calculated by the laboratory. He had started citalopram 3 months earlier after suffering from an acute episode of depression at which time his creatinine was 109 µmol/L.

A detailed history yielded little extra information. He had been to Thailand 4 months previously and had a diarrhoeal illness for 1 week, but no other symptoms including weight loss, dry eyes, rash, joint pains or arthralgia were elicited. There was no NSAID usage, and he vehemently denied illicit drug use. He was self-employed as a business manager and did body building for a

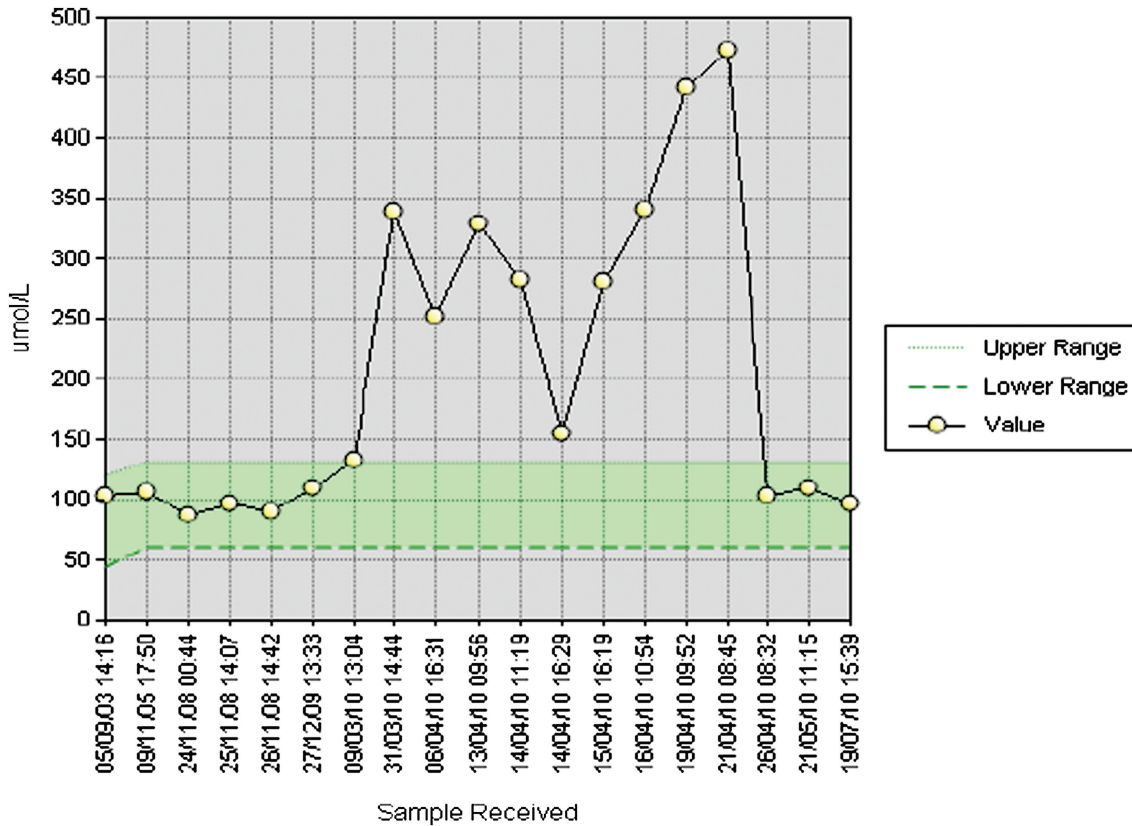


Fig. 1. The fluctuating creatinine over time.

hobby. He admitted to occasionally taking creatine supplementation but at the time of presentation had not taken any for 2 months.

On examination, he was noted to be quite muscular but was euvoalaemic with normal chest and abdominal examination. He was mildly hypertensive at 130/70, and urinalysis revealed blood and protein. His full blood count showed a mildly elevated WCC at 11.3 (neutrophilia), and repeat renal function appeared to be improving (sodium 142 mmol/L, potassium 4.9 mmol/L, urea 4.7 mmol/L and creatinine 251 $\mu\text{mol/L}$). Liver function tests were slightly deranged (bilirubin 7 $\mu\text{mol/L}$ and alanine transferase 102 U/L). An ultrasound showed normal bladder and kidneys (right 10.6 cm and left 10.8 cm). Blood anti-nuclear antigen and anti-neutrophil cytoplasmic antibodies levels were normal. Hepatitis B and C serology was negative.

In view of slightly abnormal liver function tests, a drug reaction with tubulointerstitial nephritis was considered in the differential diagnosis (recent starting of citalopram). A urine sample was sent for protein quantification, and citalopram was stopped. The patient was discharged with a plan to return for review and possible biopsy the following week if renal function not returned to baseline.

The patient returned the following week with a creatinine of 329 $\mu\text{mol/L}$ and urea 3.9 mmol/L. Urine protein-creatinine ratio was negligible at 1.6 mg/mmol (0–30). An enzymatic creatinine was performed (to exclude methodo-

logical interference in routine creatinine measurement as the urea was disproportionately low) which confirmed the elevated creatinine.

It was noted that his creatinine fluctuated quite dramatically (Figure 1) and specifically became more elevated after weekends at home, away from the hospital. This combined with elevated ALT (Figure 2) led us to suspect that exogenous substances were being taken: given the history of body building, creatine supplementation (which has been previously reported to falsely elevate creatinine [1]) or anabolic steroids which have an association with focal segmental glomerular sclerosis [2].

A creatinine kinase level was tested and found to be slightly elevated at 364 (0–90 U/L). A 24-h urine sample revealed a creatinine clearance of 72 mL/min (urine volume 2518 mL) confirming our suspicion of an elevated creatinine in the absence of renal impairment. Urine was sent to the Drugs Control Centre at Kings College, London for exogenous steroids, and a hormone profile was performed while awaiting results.

The patient was restarted on citalopram and discharged to be followed up in the clinic. Although continuing to deny taking any other drugs (including further creatine supplementation), we conveyed our concerns regarding the elevation in creatinine and suggested he should rest from body building for the time being. He returned to clinic the following week with his creatinine having returned to

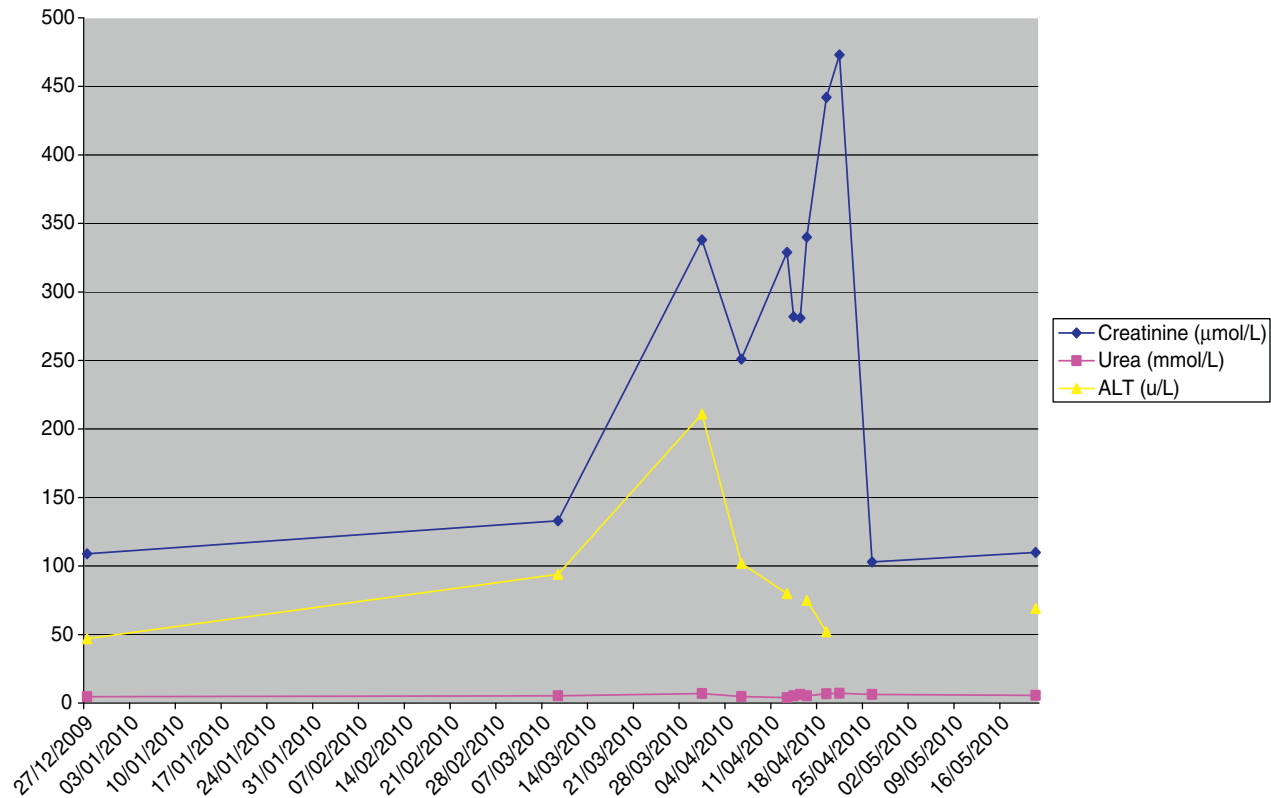


Fig. 2. The variability over time of serum creatinine in relation to ALT and urea.

the normal level, as repeatedly measured before he started taking boldenone.

The hormone profile showed suppressed endogenous LH and FSH and an elevated testosterone level: cortisol 423 nmol/L (150–650), LH 0.2 U/L (1–10), FSH 0.8 U/L (1–8) and testosterone 37.0 nmol/L (8.64–29). The urine results took 4 weeks to confirm evidence of boldenone and its metabolites. Furthermore, the height ratio of urinary testosterone to isomer epitestosterone (T/E) was measured at >20:1, consistent with exogenous testosterone administration.

Discussion

Creatine is mainly located within striated muscle where in its phosphorylated state regenerates ADP to ATP by donating one of its phosphate molecules. Creatinine is derived from creatine, and once produced, it is eliminated from the body via the kidneys in urine. Creatinine is freely filtered at the glomerulus but when used to estimate glomerular filtration, it can overestimate its true value due to a small amount of peritubular capillary secretion. Creatinine production within individuals is fairly constant and is dependent upon muscle bulk and ingestion of exogenous creatine in the form of meat protein (usually small effect). Dietary creatine intake is usually 1 g per day but can increase to 25–30 g with supplementation.

Given that production remains fairly consistent and elimination is solely via the kidneys, creatinine has been used as a surrogate marker for renal function as theoretically, it only changes in intake or elimination, i.e. renal disease can alter creatinine levels which are easily measurable.

Creatine supplements have been used by athletes for their ergogenic potential for decades. Although cases of creatine supplementation associated with renal dysfunction have been published [3], this remains controversial as several other studies have found that creatine supplementation does not affect kidney function in healthy individuals or indeed cause an elevation of serum creatinine [4,5].

It has previously been reported that dietary supplementation with creatine can lead to a significant rise in creatinine and apparent renal disease as measured by estimated GFR using the MDRD equation [1]. However, in that series, creatinine levels rose to a maximum of 166 μmol/L, and eGFR varied between 41 and 60 mL/min/1.73 m² due to ingestion of creatine supplements in HIV-positive patients. It was thought that the underlying HIV predisposed to a malnourished, and therefore leading to a more pronounced effect of creatine supplementation on muscle metabolism and subsequent creatinine levels.

Boldenone (Equipose) is a popular anabolic steroid that improves the growth and feed conversion of cattle resulting in more efficient meat production. It is also linked with equine doping incidents. It has become popular among body builders due to its effect of increasing appetite and erythropoietin production. The increased

muscle bulk associated with anabolic steroids can increase creatinine levels, but the changes in our patient varied too acutely to be explained in this way. The rise in creatinine was not due to elimination failure as evidenced by his creatinine clearance being significantly higher than his estimated GFR had implied.

This case posed a diagnostic dilemma in the early stages as we were presented with a patient with an apparent rapidly progressive rising creatinine without a clear history of ingestion of exogenous substance. It was decided not to conduct a biopsy in view of the absence of proteinuria and negative nephritic screen but meant we had to deal with diagnostic uncertainty while urine tests were performed. This case highlights the importance of a high index of suspicion for other causes of raised creatinine rather than the assumption of elimination failure, i.e. renal disease. Diagnostic clues were the disproportionate elevation in creatinine without other markers of renal disease (raised urea, raised phosphate, normal urinary protein-creatinine ratio, low haemoglobin, etc.) and the marked fluctuations with falls seen during admission when abuse was not possible and a rapid rise post-discharge.

Acknowledgements. Our clinical biochemists were actively involved with this case. They verified the raised creatinine via two methods and suggested that the urine could be set away to be tested for other steroids at the National Reference Laboratory ultimately leading to a diagnosis. We also thank the Drug Control Centre, King's College Hospital, London for processing the urine for anabolic steroids.

Conflict of interest statement. None declared.

References

1. Wills J, Jones R, Nwokolo N *et al.* Protein and creatine supplements and misdiagnosis of kidney disease. *BMJ* 2010; 340: 210–211
2. Herlitz LC, Markowitz GS, Farris AB *et al.* Development of focal segmental glomerulosclerosis after anabolic steroid abuse. *J Am Soc Nephrol* 2010; 21: 163–172
3. Pritchard NR, Kalra PA. Renal dysfunction accompanying oral creatine supplements. *Lancet* 1998; 351: 1252–1253
4. Poortmans JR, Francaux M. Long-term oral creatine supplementation does not impair renal function in healthy athletes. *Med Sci Sports Exerc* 1999; 31: 1108–1110
5. Gualano B, Ugrinowitsch C, Novaes RB *et al.* Effects of creatine supplementation on renal function: a randomized, double-blind, placebo-controlled clinical trial. *Eur J Appl Physiol* 2008; 103: 33–40

Received for publication: 31.8.10; Accepted in revised form: 5.10.10

Nephrol Dial Transplant (2011) 26: 747–751

doi: 10.1093/ndt/gfq666

Advance Access publication 4 November 2010

Acute kidney injury in the setting of AIDS, bland urine sediment, minimal proteinuria and normal-sized kidneys: a presentation of renal lymphoma

Gagangeet Sandhu¹, Aditi Ranade², Pavan Mankal^{1,4}, Leal C. Herlitz³, James Jones⁴ and Stanley Cortell⁵

¹Division of Nephrology, Department of Medicine, St. Luke's–Roosevelt Hospital Center, and the Department of Medicine, Columbia University College of Physicians and Surgeons, New York, NY, USA, ²Department of Pathology, St. Luke's–Roosevelt Hospital Center, Columbia University College of Physicians and Surgeons, New York, NY, USA, ³Department of Pathology, Columbia University Medical Center, NY, USA, ⁴Division of Nephrology, Department of Medicine, St. Luke's–Roosevelt Hospital Center, Columbia University College of Physicians and Surgeons, New York, NY, USA and ⁵Division of Nephrology, Department of Medicine, St. Luke's–Roosevelt Hospital Center, Columbia University College of Physicians and Surgeons, New York, NY, USA

Correspondence and offprint requests to: Gagangeet Sandhu; E-mail: gsandhu@chpnet.org

Abstract

Acute kidney injury in HIV patients is primarily related to HIV-mediated viral or immunological disease or to treatment-related toxicity (tenofovir). Neoplasms are a rare cause of non-obstructive acute kidney injury, primarily because when they occur, they manifest as discrete masses and not as diffuse infiltration of the renal parenchyma. Diffusely infiltrating tumors include carcinoma of the renal pelvis in-

vading the renal parenchyma, renal lymphoma, squamous cell carcinoma (from lung) metastasizing to the kidney and infiltrating sarcomatous type of renal cell carcinoma. To be classified as a true case of renal lymphoma, the tumor should have escaped detection on routine imaging preceding biopsy, and lymphoma-associated renal failure/nephrotic proteinuria should have given rise to the indication for kidney biopsy. We present here a case of an acute