


CASE REPORT

COVID-19 vaccine-induced encephalitis and status epilepticus

H.-T. Fan¹, Y.-Y. Lin^{2,3,4}, W.-F. Chiang^{5,6}, C.-Y. Lin¹, M.-H. Chen⁷, K.-A. Wu^{1,8}, J.-S. Chan^{5,6}, Y.-H. Kao^{2,*}, H.-Y. Shyu^{7,*} and P.-J. Hsiao ^{2,5,6,*}

From the ¹Department of Internal Medicine, Taoyuan Armed Forces General Hospital, Taiwan No.168, Zhongxing Road, Longtan District, Taoyuan City 325, Taoyuan, Taiwan, ²Department of Life Sciences, National Central University, Taoyuan 320, Taiwan, ³Department of Emergency Medicine, Taoyuan Armed Forces General Hospital, Taiwan No.168, Zhongxing Road, Longtan District, Taoyuan City 325, Taoyuan, Taiwan, ⁴Department of Emergency Medicine, Tri-Service General Hospital, National Defense Medical Center, Taipei 114, Taiwan, ⁵Division of Nephrology, Department of Internal Medicine, Taoyuan Armed Forces General Hospital, Taiwan No.168, Zhongxing Road, Longtan District, Taoyuan City 325, Taoyuan, Taiwan, ⁶Division of Nephrology, Department of Internal Medicine, Tri-Service General Hospital, National Defense Medical Center, Taipei 114, Taiwan, ⁷Division of Neurology, Department of Internal Medicine, Taoyuan Armed Forces General Hospital, Taiwan No.168, Zhongxing Road, Longtan District, Taoyuan City 325, Taoyuan, Taiwan and ⁸Division of Pulmonary & Critical Care Medicine, Taoyuan Armed Forces General Hospital, Taiwan No.168, Zhongxing Road, Longtan District, Taoyuan City 325, Taoyuan, Taiwan

*These authors contributed equally to this work.

Address correspondence to: P.-J. Hsiao, Division of Nephrology, Department of Internal Medicine, Taoyuan Armed Forces General Hospital, Taiwan No.168, Zhongxing Road, Longtan District, Taoyuan City 325, Taiwan, Republic of China. email: doc10510@aftygh.gov.tw; a2005a660820@yahoo.com.tw

Learning points for clinicians

Convulsion/seizure may occur infrequently after mRNA-1273 vaccine (Moderna vaccine) administration, with an estimated risk of 285 events per million person-years. We report a rare case of coronavirus disease 2019 vaccine-induced encephalitis and status epilepticus. The patient recovered after pulse corticosteroid therapy administration. Clinicians should be aware of possible neurological complications post-vaccination.

Introduction

Increasing the number of people vaccinated against coronavirus disease 2019 (COVID-19) is considered one of the most effective strategies to control the pandemic. Adverse events after

vaccination have become a challenge; myocarditis and pericarditis are frequently reported following receipt of messenger RNA (mRNA) vaccines, including BNT162b2 (Pfizer vaccine) and mRNA-1273 (Moderna vaccine).¹ We report a rare serious adverse event of refractory status epilepticus after the second dose of the Moderna vaccine. The symptoms were resolved by pulse corticosteroid therapy.

Case report

A healthy 22-year-old man was admitted due to a first seizure 6 days after receiving the second dose of the Moderna vaccine. He received the first dose of the Moderna vaccine without noticeable side effects 15 weeks previously. Intermittent fever occurred for 5 days after the second dose of the Moderna vaccine, followed by blurred vision 1 day before admission. He had consciousness disturbance with an upward gaze and extremity

Submitted: 17 December 2021

© The Author(s) 2022. Published by Oxford University Press on behalf of the Association of Physicians. All rights reserved.

For permissions, please email: journals.permissions@oup.com

rigidity for 5 min at home. There was no known seizure history and no family history of epilepsy. At the time of presentation to the emergency department, his vital signs were stable and he had clear consciousness and sinus tachycardia. On the neurological examination, slurred speech and memory loss were reported in the absence of other neurologic signs. Severe acute respiratory syndrome coronavirus 2 (SARS-CoV-2) real-time reverse transcriptase polymerase chain reaction (PCR) was negative. Laboratory results, including electrolyte balance, were generally normal, except for mildly elevated D-dimer, at 598.59 (normal range: <500) ng/ml. Chest X-ray, brain computerized tomography and electrocardiography showed no obvious abnormalities. Due to another episode of status epilepticus in the emergency department, he was admitted to the intensive care unit on the same day.

On admission, lumbar puncture was performed, and cerebrospinal fluid (CSF) analysis (Table 1) showed no pleocytosis, a normal IgG index of 0.59 (normal range: 0.0–0.7), an elevated protein level of 64.5 (normal range: 15–45) mg/dl and a microalbumin level of 36.47 (normal range: <6.5) pg/dl. CSF was negative for herpes simplex virus (HSV) on PCR, syphilis on venereal disease research laboratory (VDRL) and mycobacterium tuberculosis complex and other bacteria and fungi on culture and cytological examination. Additionally, blood tests for common pathogens and autoantibodies (ANA, RF, etc.) were also negative. Blood and CSF were negative for oligoclonal bands. We detected SARS-CoV-2 spike S1 receptor-binding domain (RBD)

IgG in CSF, with 98.54 binding antibody units (BAU)/ml, and in serum, with 3270.22 BAU/ml (CLIA, Chemiluminescence, ADVIA Centaur XPT, SIEMENS). Contrast brain magnetic resonance imaging showed unremarkable findings, while electroencephalography showed continuous diffuse slowing in the theta and delta ranges. Significantly, a cerebral perfusion scan with single-photon emission computed tomography (Figure 1) showed mild hypoperfusion in the right temporal region, and the probable seizure origin was in the right temporal region. The diagnosis of mRNA-1273 vaccine-induced encephalitis and status epilepticus was made finally.

We initiated medical treatment with intravenous levetiracetam (1 gm loading dose, 1 gm per day optimized to 3 g per day as a maintenance dose), a 5-day course of intravenous acyclovir (5–10 mg/kg) and intravenous valproate sodium (25 mg/kg loading dose, 20 mg/kg/day as maintenance dose), but the seizures continued persistently, and the patient was intubated due to hypercapnia following clonic seizures. Autoimmune encephalitis was suspected based on clinical manifestations, and pulse corticosteroid therapy with 3-day intravenous methylprednisolone at 1000 mg per day starting on Day 6, followed by 3-day methylprednisolone at 500 mg/day and subsequently reduced to 120 mg per day was administered. The patient appeared to significantly improve 3 days later after the initiation of pulse therapy and was extubated on Day 10. He remained seizure-free during the rest of the hospitalization course.

A follow-up lumbar puncture was performed 2 weeks later. The protein level was 49.4 (normal range: 15–45) mg/dl, and the microalbumin level was 25.99 (normal range: <6.5) pg/dl. No other abnormalities in CSF were detected. Autoimmune antibodies for limbic encephalitis were also negative. SARS-CoV-2 spike S1 RBD IgG decreased in CSF to 45.54 BAU/ml but increased in serum to 10 900.22 BAU/ml (CLIA, Chemiluminescence, ADVIA Centaur XPT, SIEMENS).

Table 1. The results of CSF examinations

Item	Result	Unit	Normal range
pH	7.228		
White blood cells	<5	/μl	
Red blood cells	13	/μl	
Total protein	64.5	mg/dl	15–45
LDH	15.2	U/l	
Chloride	125.2	mmol/l	
Glucose	75.9	mg/dl	40–70
HSV 1 PCR	Not detected		
HSV 2 PCR	Not detected		
VDRL	Negative		
IgG index	0.59		0–0.7
CSF culture	No bacteria		
Gram stain	No bacteria		
Indian Ink	Not found		
TB PCR DNA	Negative		
Acid-Fast Stain	Not found		
TB culture	Negative		

Discussion

Convulsions/seizures may develop after vaccination with the Moderna vaccine. The estimated risk of incidence is 285 events per million person-years from Day 0 to Day 21 after vaccination.¹ Refractory status epilepticus has been seldom documented. The underlying pathomechanism is still not well-known.

To date, cytokine storm-associated encephalopathy (CySE) rather than an infectious process directly targeting the brain is considered one of the key mechanisms of COVID-19-related encephalopathy.^{2–4} The mRNA-based vaccine could contribute to

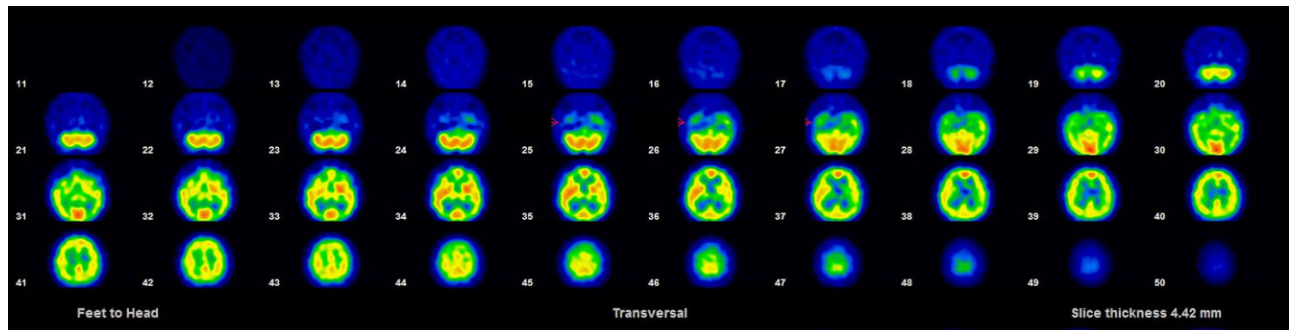


Figure 1. A cerebral perfusion scan showing mild hypoperfusion in the right temporal region.

SARS-CoV-2 spike protein expression. Spike protein expression might be considered a trigger for inflammatory processes, leading to complications after vaccination.³ The clinical response to pulse corticosteroid therapy may be attributed to an immune-mediated process. In our case, elevated total protein and microalbumin in CSF might have been an indication of increased blood–brain barrier permeability. The patient developed an inflammatory response triggered by the spike protein, leading to the disruption of the blood–brain barrier, which induced increased permeability. Despite the fact that there are no detectable biological markers, CySE may contribute to post-vaccine-related neurologic adverse events.⁴ Additionally, we examined SARS-CoV-2 spike S1 domain antibody in serum, which was increased, indicating the effect was induced after vaccination. Increased SARS-CoV-2 spike S1 domain antibody in CSF suggests a possible association with post-vaccine complications, specifically neurologic adverse events. That is, SARS-CoV-2 spike S1 domain antibody presence in CSF could be a currently unknown key, mechanism-induced, post-vaccine-related neurologic adverse event.⁵ Due to the limited incidence, we still lack data on the link between SARS-CoV-2 spike S1 domain antibody in CSF and neurologic complications. To the best of our knowledge, this is the first reported case of refractory status epilepticus after administration of the Moderna vaccine in Taiwan. We believe there will be more research involving CSF analysis to investigate post-vaccine neurological complications. To improve efficacy and safety, further studies are required to elucidate the pathogenesis of neurological complications.

Acknowledgements

The authors would like to thank the staff and researchers at the Taoyuan Armed Forces General Hospital, and Medical Affairs Bureau, Ministry of National Defense, Taiwan. They also thank the patient for consenting to publish her clinical information. This study was supported by grants from the Research Fund of the Taoyuan Armed Forces General Hospital (TYAFGH-D-111038).

Conflict of interest. None declared.

References

1. Klein NP, Lewis N, Goddard K, Fireman B, Zerbo O, Hanson KE, et al. Surveillance for adverse events after COVID-19 mRNA vaccination. *JAMA* 2021; **326**:1390–9.
2. Perrin P, Collongues N, Baloglu S, Bedo D, Bassand X, Lavaux T, et al. Cytokine release syndrome-associated encephalopathy in patients with COVID-19. *Eur J Neurol* 2021; **28**:248–58.
3. Al-Mashdali AF, Ata YM, Sadik N. Post-COVID-19 vaccine acute hyperactive encephalopathy with dramatic response to methylprednisolone: a case report. *Ann Med Surg (Lond)* 2021; **69**:102803.
4. Baldelli L, Amore G, Montini A, Panzera I, Rossi S, Cortelli P, et al. Hyperacute reversible encephalopathy related to cytokine storm following COVID-19 vaccine. *J Neuroimmunol* 2021; **358**: 577661.
5. Saito K, Shimizu T, Suzuki-Inoue K, Ishida T, Wada Y. Aseptic meningitis after vaccination of the BNT162b2 mRNA COVID-19 vaccine. *Neurol Sci* 2021; **42**:4433–5.